www.jcrpe.org

ISSN: 1308-5727
E-ISSN: 1308-5735

JCRPE Journal of Clinical Research in Pediatric Endocrinology

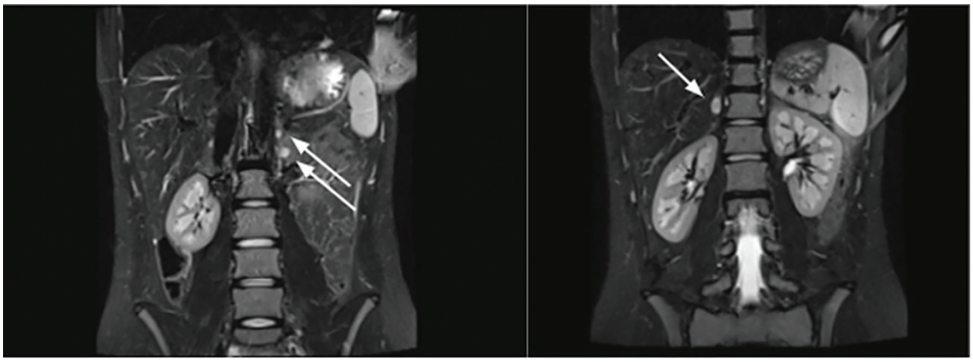

Hereditary Pheochromocytoma as a Major Manifestation of von Hippel Lindau Disease (vHL) in Childhood: Long-term Follow-up of Five Patients with vHL from One Family

Pasternak-Pietrzak K et al.

Page: 12-19

June **2026**
Volume **18**
Issue **Suppl 1**

Official Journal of
Turkish Society for Pediatric
Endocrinology and Diabetes

galenos yayinevi

JCRPE Journal of Clinical Research in Pediatric Endocrinology
www.jcrpe.org

Editor in Chief

Abdullah Bereket
Marmara University Faculty of Medicine, Department of Pediatric Endocrinology, İstanbul, Türkiye
abdullahbereket@gmail.com

Associate Editors

Aneta Gawlik-Starzyk
Medical University of Silesia Faculty of Medical Sciences in Katowice, Katowice, Poland
E-mail: agawlik@mp.pl

Damla Gökşen
Ege University Faculty of Medicine, Department of Pediatric Endocrinology, İzmir, Türkiye
E-mail: damla.goksen@ege.edu.tr

Jan Idkowiak
Institute of Metabolism and Systems Research, College of Medical and Dental Sciences, University of Birmingham, United Kingdom
E-mail: j.idkowiak@bham.ac.uk

Korcan Demir
Dokuz Eylül University Faculty of Medicine, Department of Pediatric Endocrinology, İzmir, Türkiye
E-mail: korcandemir@gmail.com

Özlem Akgün-Doğan
Acıbadem University Faculty of Medicine, Departments of Pediatric Genetics and Medical Genetics, İstanbul, Türkiye
E-mail: ozlemakgundogan@gmail.com

Samim Özen
Ege University Faculty of Medicine, Department of Pediatric Endocrinology, İzmir, Türkiye
E-mail: samim.ozen@ege.edu.tr

Serap Demircioğlu Turan
Marmara University Faculty of Medicine, Department of Pediatric Endocrinology, İstanbul, Türkiye
E-mail: serap.turan@marmara.edu.tr

Z. Alev Özön
Hacettepe University Faculty of Medicine, Department of Pediatrics, Division of Pediatric Endocrinology, Ankara, Türkiye
E-mail: ozonalev@gmail.com

Honorary Editor

Feyza Darendeliler
Emeritus, İstanbul University İstanbul Faculty of Medicine, Department of Pediatric Endocrinology, İstanbul, Türkiye
E-mail: feyzad@istanbul.edu.tr

Editorial Board

Ali Kemal Topaloğlu
University of Mississippi Medical Center, Department of Pediatrics, Division of Pediatric Endocrinology, Jackson, Mississippi, USA

Aysun Bideci
Gazi University Faculty of Medicine,Department of Pediatric Endocrinology, Ankara, Türkiye

Ayça Aykut
Ege University Faculty of Medicine, Department of Medical Genetics, İzmir, Türkiye

Banerjee Indi
Manchester University NHS Foundation Trust, Manchester, United Kingdom

Belma Haliloğlu
Marmara University Faculty of Medicine, Department of Pediatric Endocrinology, İstanbul, Türkiye

Gül Yeşiltepe Mutlu
Koç University Faculty of Medicine, Department of Pediatric Endocrinology, İstanbul, Türkiye

Hakan Döneray
Atatürk University Faculty of Medicine, Department of Pediatric Endocrinology, Erzurum, Türkiye

Hüseyin Onay
Ege University Faculty of Medicine, Department of Medical Genetics, İzmir, Türkiye

Hussain Alsaffar
Sultan Qaboos University, Department of Child Health, Oman

Justin Davies
University Hospital Southampton NHS Foundation Trust, Southampton Children's Hospital, Paediatric Endocrinology, Southampton; University of Southampton, Faculty of Medicine, Hampshire, England

Khalid Hussain
Sidra Medicine, Department of Pediatric Endocrinology, Doha, Qatar

Murat Bastepe
Massachusetts General Hospital, Harvard Medical School Endocrine Unit, Boston, USA

Margaret C S Boguszewski, MD, PhD
Federal University of Paraná, Department of Pediatrics, Curitiba, Brazil

Merih Berberoğlu
Emeritus Professor of Pediatrics, Ankara University Faculty of Medicine, Department of Pediatric Endocrinology, Ankara, Türkiye

Neslihan Güngör
Louisiana State University Health Sciences Center-Shreveport, Department of Pediatric Endocrinology, Louisiana, USA

Nurgün Kandemir
Emeritus Professor of Pediatrics, Hacettepe University Faculty of Medicine, Department of Pediatric Endocrinology, Ankara, Türkiye

Ömer Tarım
Bursa Uludağ University Faculty of Medicine, Department of Pediatric Endocrinology, Bursa, Türkiye

Rasha Tarif
Ain Shams University Faculty of Medicine, Department of Pediatrics, Cairo, Egypt

Violeta Iotova
Endo-ERN Work Package 'Education & Training' Paediatric Chair, Department of Pediatrics, Medical University of Varna, Varna, Bulgaria

Zehra Yavaş Abalı
Marmara University Faculty of Medicine, Department of Pediatric Endocrinology, İstanbul, Türkiye

Zdeněk Šumník
Charles University and University Hospital Motol, Department of Pediatrics, 2nd Faculty of Medicine, Prag, Czech Republic

Güven Özkaya (Statistical Consultant)
Bursa Uludağ University Faculty of Medicine, Department of Biostatistics, Bursa, Türkiye

English Language Editor and Assistant to the Editor in Chief
Jeremy Jones, *Kocaeli, Türkiye*

The paper used to print this journal conforms to ISO 9706: 1994 standard (Requirements for Permanence).
The National Library of Medicine suggests that biomedical publications be pirinted on acid-free paper (alkaline paper).

Reviewing the articles' conformity to the publishing standards of the Journal, typesetting, reviewing and editing the manuscripts and abstracts in English, creating links to source data, and publishing process are realized by Galenos.

galenos yayınevi

Publisher Contact
Address: Molla Gürani Mah. Kaçamak Sk. No: 21/1 34093 İstanbul, Türkiye
Phone: +90 (530) 177 30 97
E-mail: info@galenos.com.tr /yayin@galenos.com.tr
Web: www.galenos.com.tr
Publisher Certificate Number: 14521

Printing at: Son Sürat Daktilo Dijital Baskı San. Tic. Ltd. Şti.
Address: Gayrettepe Mah. Yıldızposta Cad. Evren Sitesi A Blok No: 32 D: 1-3 34349 Beşiktaş, İstanbul/Türkiye
Phone: +90 212 288 45 75
Online Publication: June 2026
ISSN: 1308-5727 **E-ISSN:** 1308-5735

JCRPE Journal of Clinical Research in Pediatric Endocrinology
www.jcrpe.org

AIMS AND SCOPE

ABOUT THE JOURNAL

The Journal of Clinical Research in Pediatric Endocrinology (JCRPE) is a peer-reviewed international journal that publishes high quality papers and reviews, which focus on clinical and translational research in Pediatric Endocrinology and Diabetes. JCRPE is among the leading journals in this field, committed to the publication of articles containing new clinical research that will have an immediate impact on clinical pediatric practice. In line with the journal's mission to disseminate knowledge and improve the care of children with endocrine disorders, articles in both current and previous issues are provided as free on-line open access to all readers globally, which also increases the visibility of the papers published in JCRPE.

JCRPE publishes original research articles, reviews, short communications, letters, case reports with novel insights, and other special features related to the field of pediatric endocrinology and diabetes. JCRPE is the official journal of Turkish Society for Pediatric Endocrinology and Diabetes and is published in English quarterly (March, June, September, December). The target audience includes physicians, researchers and other healthcare professionals in all areas of pediatric endocrinology and diabetes..

JCRPE is indexed in **PubMed/MEDLINE, Index Medicus/PubMed, PubMed Central (PMC), British Library, EBSCO, SCOPUS, EMBASE, Engineering Village, Reaxys, CINAHL, ProQuest, GALE, Turk Medline, Tübitak Ulakbim TR Index, Türkiye Citation Index, Science Citation Index-SCI-E, Hinari, GOALI, ARDI, OARE, AGORA, J-GATE, IdealOnline** and **DOAJ**.

JCRPE has an impact factor 1.5 in 2024.
****The 5-year impact factor 1.9 in 2024.**

The journal is printed on an acid-free paper.

Permissions

Requests for permission to reproduce published material should be sent to the publisher.
Galenos Publishing House
Address: Molla Gürani mah. Kaçamak Sok. 21/1 Fatih, Istanbul, Türkiye
Telephone: +90 212 621 99 25
Fax: +90 212 621 99 27
Web page: http://www.galenos.com.tr/en
E-mail: info@galenos.com.tr

Copyright Notice

The author(s) hereby affirms that the manuscript submitted is original, that all statement asserted as facts are based on author(s) careful investigation and research for accuracy, that the manuscript does not, in whole or part, infringe any copyright, that it has not been published in total or in part and is not being submitted or considered for publication in total or in part elsewhere.
Completed Copyright Assignment&Affirmation of Originality Form will be faxed to the JCRPE Editorial Office (Fax: +90 212 621 99 27).

By signing this form,
1. Each author acknowledge that he/she participated in the work in a substantive way and is prepared to take public responsibility for the work.
2. Each author further affirms that he or she has read and understands the "Ethical Guidelines for Publication of Research".
3. The author(s), in consideration of the acceptance of the manuscript for publication, does hereby assign and transfer to the Journal of Clinical Research in Pediatric Endocrinology all of the rights and interest in and the copyright of the work in its current form and in any form subsequently revised for publication and/or electronic dissemination.

Open Access Policy

This journal provides immediate open and free access to its content on the principle that making research freely available to the public supports a greater global exchange of knowledge.
Open Access Policy is based on the rules of the Budapest Open Access Initiative (BOAI) http://www.budapestopenaccessinitiative.org/. By "open access" to peer-reviewed research literature, we mean its free availability on the public internet, permitting any users to read, download, copy, distribute, print, search, or link to the full texts of these articles, crawl them for indexing, pass them as data to software, or use them for any other lawful purpose, without financial, legal, or technical barriers other than those inseparable from gaining access to the internet itself. The only constraint on reproduction and distribution, and the only role for copyright in this domain, should be to give authors control over the integrity of their work and the right to be properly acknowledged and cited.
This work is licensed under a Creative Commons Attribution-NonCommercial-NoDerivatives 4.0 (CC BY-NC-ND) International License.
CC BY-NC-ND: This license allows reusers to copy and distribute the material in any medium or format in unadapted form only, for noncommercial purposes only, and only so long as attribution is given to the creator.

CC BY-NC-ND includes the following elements:
BY – Credit must be given to the creator
NC – Only noncommercial uses of the work are permitted
ND – No derivatives or adaptations of the work are permittedz

JCRPE Journal of Clinical Research in Pediatric Endocrinology
www.jcrpe.org

INSTRUCTIONS TO AUTHORS

GENERAL INFORMATION

Manuscripts must be written in English and must meet the requirements of the journal. Papers that do not meet these requirements will be returned to the author for necessary revision before the review. Manuscripts submitted to JCRPE are evaluated by peer reviewers. Authors of manuscripts requiring modifications have two months to resubmit a revised paper. Manuscripts returned after this deadline will be treated as new submissions. The journal is in compliance with the uniform requirements for manuscripts submitted to biomedical journals published by the International Committee of Medical Journal Editors (NEJM 1997; 336:309-315, updated 2001). Upon submission of the manuscript, authors are to indicate the type of trial/research and provide the checklist of the following guidelines when appropriate: Consort statement for randomized controlled trials (Moher D, Schultz KF, Altman D, for the CONSORT Group. The CONSORT statement revised recommendations for improving the quality of reports of parallel group randomized trials. JAMA 2001 ; 285 : 1987 - 91), the QUOROM statement for meta-analysis and systemic reviews of randomized controlled trials (Moher D, Cook DJ, Eastwood S, Olkin I, Rennie D, Stroup DF. Improving the quality of reports of meta-analyses of randomized controlled trials: the QUOROM statement. Quality of Reporting of Meta-Analyses. Lancet 1999; 354 : 1896 – 900) and the MOOSE guidelines for meta-analysis and systemic reviews of observational studies (Stroup DF, Berlin JA, Morton SC, et al. Meta-analysis of observational studies in epidemiology: a proposal for reporting Meta-analysis of observational studies in Epidemiology (MOOSE) group. JAMA 2000; 283: 2008 – 12). Keywords are included according to MeSH (Medical Subject Headings) National Library of Medicine.

Once the manuscript is accepted to be published in The Journal of Clinical Research in Pediatric Endocrinology, it receives a Digital Object Identifier (DOI) number. Uncorrected full text files can be reached online via PubMed and Ahead of Print section of the journal's website (http://www.jcrpe.org/ahead-of-print).
All contents will be printed in black and white.

Article Publication Charges

As of January 1, 2025, "Journal of Clinical Research in Pediatric Endocrinology" applies an Article Processing Charge (APCs) for only accepted articles. No fees are requested from the authors during submission and evaluation process. All manuscripts must be submitted via https://jcrpe.manuscriptmanager.net/ . An APC fee of and local taxes will be applied depending on the article type (see Table 1)

Table 1.

Article Type	Fee
Original article	$ 350
Case Report	$ 275
Noninvited Review	$ 500

Please contact the editorial office for detailed information by the following link: info@jcrpe.org

*Please note that the Article Processing Charge (APC) will not affect neither the editorial and peer-review process nor the priority of the manuscripts by no means. All submissions will be evaluated by the Editorial Board and the external reviewers in terms of scientific quality and ethical standards.

MANUSCRIPT CATEGORIES

All manuscripts must adhere to the limitations, as described below, for text only; the word count does not include the abstract, references, or figure/table legends. The word count must be noted on the title page, along with the number of figures and tables. Original Articles should be no longer than 4000 words and include no more than six figures and tables and 50 references. The abstract of the article should not exceed 250 words.

Short Communications are short descriptions of focused studies with important, but very straightforward results. These manuscripts should be no longer than 2000 words, and include no more than two figures and tables and 20 references. The abstract of the article should not exceed 250 words.

Brief Reports are discrete, highly significant findings reported in a shorter format. The abstract of the article should not exceed 150 words and the text/article length should not exceed 1200 words. References should be limited to 12, a maximum of 2 figures or tables.

Clinical Reviews address important topics in the field of pediatric endocrinology. Authors considering the submission of uninvited reviews should contact the editors in advance to determine if the topic that they propose is of current potential interest to the Journal. Reviews will be considered for publication only if they are written by authors who have at least three published manuscripts in the international peer reviewed journals and these studies should be cited in the review. Otherwise only invited reviews will be considered for peer review from qualified experts in the area. These manuscripts should be no longer than 5000 words and include no more than four figures and tables and 120 references. The abstract of the article should not exceed 250 words.

Case Reports are descriptions of a case or small number of cases revealing novel and important insights into a condition's pathogenesis, presentation, and/or management. These manuscripts should be 2500 words or less, with four or fewer figures and tables and 30 or fewer references. The abstract of the article should not exceed 250 words.

Consensus Statements may be submitted by professional societies. All such submission will be subjected to peer review, must be modifiable in response to criticisms, and will be published only if they meet the Journal's usual editorial standards. These manuscripts should typically be no longer than 4000 words and include no more than six figures and tables and 120 references.

Letters to the Editor may be submitted in response to work that has been published in the Journal. Letters should be short commentaries related to specific points of agreement or disagreement with the published work. Letters should be no longer than 500 words with no more than five complete references, and may not include any figures or tables.

Note on Prior Publication

The journal publishes original research and review material. Material previously published in whole or in part shall not be considered for publication. At the time of submission, authors must report that the manuscript has not been published elsewhere. Abstracts or posters displayed at scientific meetings need not be reported.

MANUSCRIPT SUBMISSION PROCEDURES

JCRPE only accepts electronic manuscript submission at the web site www.jcrpe.org
After logging on to the website www.jcrpe.org click 'Submit an Article' icon. All corresponding authors should be provided a password and a username after providing the information needed. If you already have an account from a previous submission, enter your username and password to submit a new or revised manuscript. If you have forgotten your username and/or password, e-mail the editorial office for assistance. After logging on the article submission system with your own password and username please read carefully the directions of the system to provide all needed information. Attach the manuscript, tables and figures and additional documents.

All Submissions Must Include:

1. A cover letter requesting that the manuscript be evaluated for publication in JCRPE and any information relevant to your manuscript. Cover letter should contain address, telephone, fax and e-mail address of the corresponding author.

2. Completed Copyright and Disclosure of Potential Conflicts of Interest Form. The corresponding author must acquire all of the authors' completed forms and mail to info@galenos.com.tr / yayin@galenos.com.tr or submit to the Manuscript Manager.

3. Completed Disclosure of Potential Conflict of Interest Form. The corresponding author must acquire all of the authors' completed disclosure forms and fax them to the editorial office at +90 212 621 99 27.

Authors must complete the online submission forms. If unable to successfully upload the files please contact the editorial office by e-mail.

MANUSCRIPT PREPARATION

General Format

The Journal requires that all submissions be submitted according to these guidelines:

- Text should be double spaced with 2.5 cm margins on both sides using 12-point type in Times Roman font.
- All tables and figures must be placed after the text and must be labeled.
- Each section (abstract, text, references, tables, figures) should start on a separate page.
- Manuscripts should be prepared as word document (*.doc) or rich text format (*.rtf).

JCRPE Journal of Clinical Research in Pediatric Endocrinology
www.jcrpe.org

INSTRUCTIONS TO AUTHORS

Title Page

The title page should include the following:

- Full title
- Short title of not more than 40 characters for page headings
- Authors' names, and institutions, and e-mail addresses
- Corresponding author's e-mail and post address, telephone and fax numbers
- At least five and maximum eight keywords. Do not use abbreviations in the keywords
- Word count (excluding abstract, figure legends and references)
- Name and address of person to whom reprint requests should be addressed
- Any grants or fellowships supporting the writing of the paper
- The acknowledgements, if there are any
- If the content of the manuscript has been presented before, the time and place of the presentation
- The ORCID (Open Researcher and Contributor ID) number of the all authors should be provided while sending the manuscript. A free registration can be done at http://orcid.org.

Structured Abstracts (According to the The Journal of the American Medical Association)
Original Articles should be submitted with structured abstracts of no more than 250 words. All information reported in the abstract must appear in the manuscript. The abstract should not include references. Please use complete sentences for all sections of the abstract. Structured abstract should include background, objective, methods, results and conclusion.

What is already known on this topic?
What this study adds?
These two items must be completed before submission. Each item should include at most 2-3 sentences and at most 50 words focusing on what is known and what this study adds.
Review papers do not need to include these boxes.

Introduction

The article should begin with a brief introduction stating why the study was undertaken within the context of previous reports.

Experimental Subjects

All clinical investigations described in submitted manuscripts must have been conducted in accordance with the guidelines in the Declaration of Helsinki and has been formally approved by the appropriate institutional review committees. All manuscripts must indicate that such approval was obtained and that informed consent was obtained from subjects in all experiments involving humans. The study populations should be described in detail. Subjects must be identified only by number or letter, not by initials or names. Photographs of patients' faces should be included only if scientifically relevant. Authors must obtain written consent from the patient for use of such photographs.

Clinical Trials Registration

All clinical trials must be registered in a public trials registry acceptable to the International Committee of Medical Journals Editors (ICMJE). Authors of randomized controlled trials must adhere to the CONSORT guidelines, and provide both a CONSORT checklist (for protocols, see the SPIRIT guidance) and flow diagram. We require that you choose the MS Word template at www.consort-statement.org for the flow chart and cite/upload it in the manuscript as a figure. In addition, submitted manuscripts must include the unique registration number in the Abstract as evidence of registration.

You can register for clinical trials by visiting the following link:
https://clinicaltrials.gov/
To register the relevant record in the system and learn more about the protocol to be followed, please review the link below:
https://classic.clinicaltrials.gov/ct2/manage-recs/how-register

Graphical Abstract

The Journal of Clinical Research in Pediatric Endocrinology aims to enhance the visibility of authors' publications and contribute to the scientific community as much as possible. In this regard, our journal encourages authors to publish graphical abstracts. The provided example abstract below reflects the standards accepted by our journal. Therefore, our journal expects authors to adhere to the following instructions:
1) Unless authors specify otherwise, the vectors used in the example will be used as the standard. Information to be placed beneath the vectors will be provided by the authors.
2) The article graphics used in the example will be revised with graphics of the authors' preference.
Once these two stages are completed successfully, the prepared graphical abstract will be integrated into the article. Our journal aims to support authors in this process and enhance the impact of their scientific work.

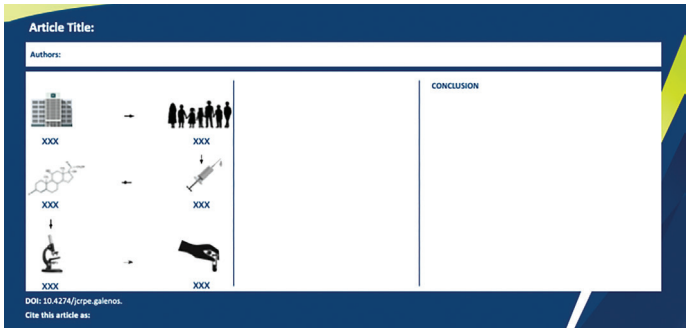

Experimental Animals

A statement confirming that all animal experimentation described in the submitted manuscript was conducted in accord with accepted standards of humane animal care, according to the Declaration of Helsinki and Genova Convention, should be included in the manuscript.

Materials and Methods

These should be described and referenced in sufficient detail for other investigators to repeat the work. Ethical consent should be included as stated above.
The name of the ethical committee, approval number should be stated. At the same time, the Ethics Committee Approval Form should be uploaded with the article.

Results

The Results section should briefly present the experimental data in text, tables, and/or figures. Do not compare your observations with that of others in the results section.
The raw results of weight, length/height, body mass index, and blood pressure measurements can not be compared among groups since they normally change with age and according to gender. Instead, standard deviation scores of those values should be reported and compared.

Discussion

The Discussion should focus on the interpretation and significance of the findings with concise objective comments that describe their relation to other work in that area and contain study limitations.

Study Limitations

Limitations of the study should be detailed. In addition, an evaluation of the implications of the obtained findings/results for future research should be outlined.

Conclusion

The conclusion of the study should be highlighted.

Acknowledgments (Not Required for Submission)

An acknowledgment is given for contributors who may not be listed as authors, or for grant support of the research.

JCRPE Journal of Clinical Research in Pediatric Endocrinology
www.jcrpe.org

INSTRUCTIONS TO AUTHORS

Authorship Contribution
The kind of contribution of each author should be stated.

References
Authors are required to provide an active access link and, where available, the DOI (Digital Object Identifier) for each reference listed in the bibliography at the time of manuscript submission. References lacking DOI information should include a direct and verifiable URL to the source. Submissions with incomplete reference metadata may be returned to authors for correction prior to peer review.
References to the literature should be cited in numerical order (in parentheses) in the text and listed in the same numerical order at the end of the manuscript on a separate page or pages. The author is responsible for the accuracy of references.
Number of References: Case Report max 30 / Original Articles max 50
Examples of the reference style are given below. Further examples will be found in the articles describing the Uniform Requirements for Manuscripts Submitted to Biomedical Journals (Ann Intern Med.1988; 208:258-265, Br Med J. 1988; 296:401-405). The titles of journals should be abbreviated according to the style used in the Index Medicus.

Journal Articles and Abstracts: List all authors. The citation of unpublished observations, of personal communications is not permitted in the bibliography. The citation of manuscripts in press (i.e., accepted for publication) is permitted in the bibliography; the name of the journal in which they appear must be supplied. Citing an abstract is not recommended.

Books: List all authors or editors.

Sample References
Papers Published in Periodical Journals: Gungor N, Saad R, Janosky J, Arslanian S. Validation of surrogate estimates of insulin sensitivity and insulin secretion in children and adolescents. J Pediatr 2004;144:47-55.

Papers Only Published with DOI Numbers: Knops NB, Sneeuw KC, Brand R, Hile ET, de Ouden AL, Wit JM, Verloove-Vanhorick SP. Catch-up growth up to ten years of age in children born very preterm or with very low birth weight. BMC Pediatrics 2005 doi: 10.1186/1471-2431-5-26.
Book Chapters: Darendeliler F. Growth Hormone Treatment in Rare Disorders: The KIGS Experience. In: Ranke MB, Price DA, Reiter EO (eds). Growth Hormone Therapy in Pediatrics: 20 Years of KIGS. Basel, Karger, 2007;213-239.

Books: Practical Endocrinology and Diabetes in Children. Raine JE, Donaldson MDC, Gregory JW, Savage MO. London, Blackwell Science, 2001;37-60.

Tables
Tables must be constructed as simply as possible. Each table must have a concise heading and should be submitted on a separate page. Tables must not simply duplicate the text or figures. Number all tables in the order of their citation in the text. Include a title for each table (a brief phrase, preferably no longer than 10 to 15 words). Include all tables in a single file following the manuscript.

Figures Legends
Figure legends and titles should be submitted on a separate page. Figure legends and titles should be clear and informative. Tables and figures should work under "windows". Number all figures (graphs, charts, photographs, and illustrations) in the order of their citation in the text. Include a title for each figure (a brief phrase, preferably no longer than 10 to 15 words).

Figures & Images
At submission, the following file formats are acceptable: AI, EMF, EPS, JPG, PDF, PPT, PSD, TIF. Figures may be embedded at the end of the manuscript text file or loaded as separate files for submission purposes.
All images MUST be at or above intended display size, with the following image resolutions: Line Art 800 dpi, Combination (Line Art + Halftone) 600 dpi, Halftone 300 dpi. See the Image quality specifications chart for details. Image files also must be cropped as close to the actual image as possible.

Units of Measure
Results/Tables should be expressed in metric units. If needed please apply this usage in your manuscript.
If p values are significant in the tables you have prepared, the relevant p values should be indicated in bold font.

Validation of Data and Statistical Analysis
Assay validation: Bioassay and radioimmunoassay potency estimates should be accompanied by an appropriate measure of the precision of these estimates. For bioassays, these usually will be the standard deviation, standard error of the mean, confidence limits. For both bioassays and radioimmunoassays, it is necessary to include data relating to within-assay and between-assay variability. If all relevant comparisons are made within the same assay, the latter may be omitted. Statistical analysis should be done accurately and with precision. Please consult a statistician if necessary.

Proofs and Reprints
Proofs and a reprint order are sent to the corresponding author. The author should designate by footnote on the title page of the manuscript the name and address of the person to whom reprint requests should be directed. The manuscript when published will become the property of the journal.

Page and Other Charges
Archiving
The editorial office will retain all manuscripts and related documentation (correspondence, reviews, etc.) for 12 months following the date of publication or rejection.

Submission Preparation Checklist
As part of the submission process, authors are required to check off their submission's compliance with all of the following items, and submissions may be returned to authors that do not adhere to these guidelines.

1. The submission has not been previously published, nor is it before another journal for consideration (or an explanation has been provided in Comments to the Editor).

2. The submission file is in Microsoft Word, RTF, or WordPerfect document file format. The text is double-spaced; uses a 12-point font; employs italics, rather than underlining (except with URL addresses); and all illustrations, figures, and tables are placed within the text at the appropriate points, rather than at the end. Please do not send the manuscript in docx.

3. Where available, URLs for the references have been provided.

4. A completed Copyright ve Disclosure of Potential Conflicts of Interest Form must be uploaded with other files during the submission. The corresponding author must acquire all of the authors' completed forms and mail to info@galenos.com.tr / yayin@galenos.com.tr or submit to the Manuscript Manager.

5. The text adheres to the stylistic and bibliographic requirements outlined in the Author Guidelines, which is found in About the Journal.

6. Completed Disclosure of Potential Conflict of Interest Form. The corresponding author must aquire all of the authors" completed disclosure forms and fax them, together, to the editorial office along with the Author Disclosure Summary.

Privacy Statement
The names and email addresses entered in this journal site will be used exclusively for the stated purposes of this journal and will not be made available for any other purpose or to any other party.

Peer Review Process
1. The manuscript is assigned to an editor, who reviews the manuscript and makes an initial decision based on manuscript quality and editorial priorities.

2. For those manuscripts sent for external peer review, the editor assigns reviewers to the manuscript.

3. The reviewers review the manuscript.

4. The editor makes a final decision based on editorial priorities, manuscript quality, and reviewer recommendations.

5. The decision letter is sent to the author.

JCRPE Journal of Clinical Research in Pediatric Endocrinology
www.jcrpe.org

The Reviewer is Asked to Focus on the Following Issues:

1. General recommendation about the manuscript
How original is the manuscript?
Is it well presented?
How is the length of the manuscript?

2. Publication timing, quality, and priority
How important is the manuscript in this field?
Does it present original data?
Does it carry priority in publishing?

3. Specific questions regarding the quality of the manuscript
Does the title describe the study accurately?
Is the abstract informative and clear?
Do the authors state the study question in the introduction?
Are the methods clear?
Are ethical guidelines met?
Are statistical analyses appropriate?
Are the results presented clearly?
Does the discussion cover all of the findings?
Are the references appropriate for the manuscript?

4. Remarks to the editor
Accepted in its present form
Accepted after modest revisions
Reconsidered for acceptance after major changes
Rejected

5. Remarks to the author
What would be your recommendations to the author?
Conflict of interest statement for the reviewer (Please state if a conflict of interest is present)
For further instructions about how to review, see Reviewing Manuscripts for Archives of Pediatrics & Adolescent Medicine by Peter Cummings, MD, MPH; Frederick P. Rivara, MD, MPH in Arch Pediatr Adolesc Med. 2002;156:11-13.

GUIDELINES FOR MANUSCRIPT PREPARATION

The authors can also benefit from the following guidelines in the process of preparing the article:
Clinical Trials
Observational Studies
Systematic Review
Diagnostic and Prognostic Studies

JCRPE Journal of Clinical Research in Pediatric Endocrinology
www.jcrpe.org

CONTENTS

CASE REPORTS

1 **A Rare Presentation of 17α-Hydroxylase/17,20-Lyase Deficiency in a Patient with Non-Hodgkin's Lymphoma: A Case Report**
Niran Tekkeli, İlknur Kurt, Nevin Yalman, Çetin Timur, Şenol Demir, Elif Sağsak; İstanbul, Türkiye

6 **Autosomal Recessive Hypophosphatemic Rickets Type 2 Associated with a Novel *ENPP1* Variant in a Taiwanese Girl**
Han-Yi Lin, Ni-Chung Lee, Meng-Ju Melody Tsai, Ting-Ming Wang, Yi-Ching Tung; Hsinchu, Taipei, Yunlin, Taiwan

12 **Hereditary Pheochromocytoma as a Major Manifestation of von Hippel Lindau Disease (vHL) in Childhood: Long-term Follow-up of Five Patients with vHL from One Family**
Katarzyna Pasternak-Pietrzak, Agata Kozłowska, Elżbieta Moszczyńska; Warsaw, Poland

20 **A Rare Cause of Proportional Short Stature and Puberty Precocity: Floating-Harbor Syndrome**
Duygu Çetinkaya, Gönül Büyükyılmaz, Esra Kılıç; Ankara, Türkiye

25 **A Rare Coexistence of Turner Syndrome and Mycosis Fungoides: A Case Report**
Ozge Bayrak Demirel, Esin Karakilic-Ozturan, Tugba Atci, Sule Ozturk Sari, Can Baykal, Asli Derya Kardelen, Melek Yildiz, Sukran Poyrazoglu, Firdevs Bas, Feyza Darendeliler; İstanbul, Türkiye

30 **Unraveling a Genetic Puzzle: Could *MAP3K7* Be a Candidate Gene for RASopathies?**
Sirmen Kızılcan Çetin, Zeynep Şıklar, Zehra Aycan, Elif Özsu, Serdar Ceylaner, Merih Berberoğlu; Ankara, Türkiye

37 **Gonadoblastoma with Dysgerminoma in a Virilized Adolescent with Karyotype 46,XX: A Case Report and Review of the Literature**
Tugce Kandemir, Esin Karakilic Ozturan, Ozlem Dural, Ayca Dilruba Aslanger, Elif Inan Balci, Aysel Bayram, Semen Onder, Asli Derya Kardelen, Melek Yildiz, Sukran Poyrazoglu, Firdevs Bas, Feyza Darendeliler; İstanbul, Türkiye

45 **Permanent Neonatal Diabetes with High Insulin Requirements due to a New Variant in the *INS* Gene**
Johana Andrea Botero Hernández, Gina González-Valencia, Vanessa Suarez, Gabriel del Castillo; Medellín, Nariño, Colombia

50 **A Novel SRD5A2 Loss-of-Function Variant in a Chinese Child with 5α-reductase Type 2 Deficiency**
Peng Zhou, Juanjuan Lyu, Xiaomei Sun, Ying Liu, Chuanjie Yuan, Jin Wu; Chengdu, China

54 **A Rare Cause of Neonatal Salt Wasting Syndrome: Clinical Management of a Case Diagnosed with Pseudohypoaldosteronism due to a Novel Homozygous Variant in the *SCNN1B* Gene**
Berna Singin, Zeynep Donbaloğlu, Ebru Barsal Çetiner, Kürşat Çetin, Nurten Özkan Zarif, Kıymet Çelik, Ercan Mıhçı, Özden Altıok Clark, Hale Tuhan, Mesut Parlak; Antalya, Türkiye

59 **Clinical and Molecular Landscape of Weiss-Kruszka Syndrome: A Case Report and Literature Review**
Lele Li, Chunxiu Gong; Beijing, China

64 **Cabergoline Induced Pathological Gambling in an Adolescent with Prolactinoma**
Ummahan Tercan, Ezgi Sarban, Melek Yıldız, Özlem Nida Erbaşı, Mine Özkan, Aslı Derya Kardelen, Şükran Poyrazoğlu, Firdevs Baş, Feyza Darendeliler; İstanbul, Türkiye

70 **Atypical Presentation of New Onset Diabetes with Hyperglycemic Hyperosmolar State in Two Toddlers**
Alina Haque, Esther E. Bell-Sambataro, Foram Patel, Leena Mamilly, Kathryn Obrynba, Jennifer M. Ladd; Ohio, Florida, Texas, United States

75 **Thauvin-Robinet-Faivre Syndrome: A *FIBP* Variant in an Adolescent with Segmental Overgrowth and Thyroid Carcinoma**
Ülkü Gül Şiraz, Deniz Koçak Göl, Meino Rohlfs, Christoph Klein, Ekrem Ünal, Nihal Hatipoğlu; Kayseri, Gaziantep, Türkiye; Munich, Germany

83 **Xp21 Contiguous Gene Deletion Syndrome: Diagnosis, Treatment, and a Review of the Literature on a Rare Genetic Disorder**
Berna Singin, Zeynep Donbaloğlu, Ebru Barsal Çetiner, Aynur Bedel, Kürşat Çetin, Belgin Akcan Paksoy, Tarkan Kalkan, Halide Akbaş, Hale Ünver Tuhan, Mesut Parlak; Antalya, Türkiye

92 **Four Consecutive False Negative Newborn Screens in a Patient with Classical Congenital Adrenal Hyperplasia: A Case Report**
Patrick Rizzuto, Mariam Gangat, Ahmed Khattab, Ian Marshall; New Jersey, United States

CASE REPORT

JCRPE Journal of Clinical Research in Pediatric Endocrinology

DOI: 10.4274/jcrpe.galenos.2024.2024-3-13
J Clin Res Pediatr Endocrinol 2026;18(Suppl 1):1-5

A Rare Presentation of 17α-Hydroxylase/17,20-Lyase Deficiency in a Patient with Non-Hodgkin's Lymphoma: A Case Report

Niran Tekkeli[1], İlknur Kurt[2], Nevin Yalman[3], Çetin Timur[3], Şenol Demir[4], Elif Sağsak[5]

[1]Yeditepe University Faculty of Medicine, Department of Pediatrics, İstanbul, Türkiye
[2]Marmara University Faculty of Medicine, Department of Pediatric Endocrinology, İstanbul, Türkiye
[3]Yeditepe University Faculty of Medicine, Department of Pediatric Hematology, İstanbul, Türkiye
[4]Marmara University Faculty of Medicine, Department of Medical Genetics, İstanbul, Türkiye
[5]Yeditepe University Faculty of Medicine, Department of Pediatric Endocrinology, İstanbul, Türkiye

Cite this article as: Tekelli N, Kurt İ, Yalman N, Timur Ç, Demir Ş, Sağsak E. A rare presentation of 17α-hydroxylase/17,20-lyase deficiency in a patient with non-Hodgkin's lymphoma: a case report. J Clin Res Pediatr Endocrinol. 2026;18(Suppl 1):1-5

What is already known on this topic?

In 17α-hydroxylase/17,20-lyase deficiency (17OHD), patients are usually diagnosed during the adolescent period due to delayed puberty or amenorrhea. However, findings of adrenal failure are rare because of excessive production of corticosterone.

What this study adds?

Although clinical signs and symptoms of cortisol deficiency are not seen in 17OHD, hyperpigmentation may be observed in stressful situations. Hypergonadotropic hypogonadism can be a sign of adrenal dysfunction.

ABSTRACT

17α-hydroxylase/17,20-lyase deficiency (17OHD) is a rare form of congenital adrenal hyperplasia that causes decreased cortisol and sex steroid levels and leads to high production of adrenocorticotropic hormone. Although affected patients have absolute cortisol deficiency, they do not show clinical signs of cortisol deficiency or hyperpigmentation. These patients most commonly present with delayed puberty and amenorrhea at late pubertal age. Impaired production of sex steroids leads to ambiguous or female external genitalia in affected 46, XY individuals. In this report, we describe a patient with 17OHD who presented with hyperpigmentation and hypergonadotropic hypogonadism while receiving chemotherapy.

Keywords: 17α-hydroxylase deficiency, *CYP17A1* gene, hyperpigmentation, hypergonadotropic hypogonadism, disorders/differences in sex development

Corresponding Author: Elif Sağsak, MD, Yeditepe University Faculty of Medicine, Department of Pediatric Endocrinology, İstanbul, Türkiye
E-mail: elif.sagsak@yeditepe.edu.tr **ORCID:** orcid.org/0000-0001-7121-1575
Conflict of interest: None declared
Received: 26.03.2024 **Accepted:** 05.06.2024 **Epub:** 10.10.2024 **Publication Date:** 02.06.2026

©Copyright 2026 by Turkish Society for Pediatric Endocrinology and Diabetes / The Journal of Clinical Research in Pediatric Endocrinology published by Galenos Publishing House.
Licensed under a Creative Commons Attribution-NonCommercial-NoDerivatives 4.0 (CC BY-NC-ND) International License.

J Clin Res Pediatr Endocrinol
2026;18(Suppl 1):1-5

Introduction

Congenital adrenal hyperplasia (CAH) is a group of inherited autosomal recessive diseases caused by mutations in genes encoding steroidogenic enzymes required for cortisol, aldosterone, and adrenal sex steroid synthesis (1). 17α-hydroxylase/17,20-lyase deficiency (17OHD) is a rare form of congenital CAH and occurs as a result of mutations in the cytochrome P450 family (*CYP17A1*) gene on chromosome 10q24.3. The estimated prevalence is 1 in 50,000-100,000 (2,3). The enzyme 17OHD (P450c17) is essential for the synthesis of cortisol and sex steroids. This enzyme has 17α-hydroxylase and 17,20-lyase activities. The first reaction provides the transformation of pregnenolone and progesterone to 17α-hydroxypregnenolone and 17α-hydroxyprogesterone respectively. The second transforms 17α-hydroxysteroids to dehydroepiandrosterone (DHEA) and androstenedione. The absence of the enzyme causes decreased cortisol and sex steroid levels and leads to high production of adrenocorticotropic hormone (ACTH) that further drives the overproduction of 11-deoxycorticosterone (11-DOC) and corticosterone (4). High 11-DOC and corticosterone act as mineralocorticoids and lead to hypertension and hypokalemia. In addition, the impaired production of sex steroids leads to ambiguous or female external genitalia in affected 46, XY individuals, and normal genitalia in 46, XX individuals at birth, but no sexual development at the expected time of puberty. Affected patients most commonly present with hypertension, delayed puberty, and amenorrhea at a late pubertal age (5). Although these patients also have absolute cortisol deficiency, they do not show clinical signs of cortisol deficiency because of the effect of corticosterone on the glucocorticoid receptor (6). However, in times of severe stress, classical findings of adrenal insufficiency may also occur in 17OHD. Here, we report the case of a 10 years and 6-months-old patient who was diagnosed with 17OHD while receiving treatment for non-Hodgkin's lymphoma (NHL) without common findings of the condition.

Case Report

Ten-and-a-half-year-old girl with NHL was referred to pediatric endocrinology as the ovaries were not seen on abdominal ultrasonography performed because of abdominal pain. Eight months earlier, she was diagnosed with pre-B-cell NHL and started to receive chemotherapy. The patient's history revealed that she had a mild hyperpigmentation in her skin, especially in the folds of the body when she was four years old and was evaluated as allergic. However, when she used antiallergic medications, they were not effective. She reported increased darkening of the skin after the diagnosis and treatment of NHL. She was the third child of healthy parents who were first-cousins. Anthropometric measurements were calculated by using reference values for Turkish children (7). On physical examination, her weight was 43 kg [+0.98 standard deviation score (SDS)], height was 150 cm (+1.3 SDS) and body mass index was 19.11 kg/m^2 (+0.57 SDS). Her blood pressure was 110/60 mmHg (95th percentile: 121/78 mmHg), and she was prepubertal. The external genital structure was typically female. There was hyperpigmentation in skin folds (Figure 1), and her liver was 7 cm palpable in the subcostal region. Pelvic ultrasound and magnetic resonance imaging revealed the absence of both ovaries and the uterus and atrophic gonads in the proximal right inguinal canal and the left lower abdominal quadrant. Hormonal tests showed hypergonadotropic hypogonadism (Table 1). Plasma ACTH, anti-Müllerian hormone, corticosterone, 11-DOC, and progesterone were found to be high, while cortisol, DHEA sulfate (DHEA-S), estradiol, total testosterone and 17-OH progesterone concentrations were low (Table 1). Serum sodium and potassium levels were normal. Karyotype analysis was performed by G-banding following 72 hour culture of peripheral blood lymphocytes. The karyotype was 46, XY.

Blood samples from the patient and parents were collected using vacuum-EDTA tubes. DNA was isolated from the peripheral blood using QIAamp DNA Blood Mini Kit (Qiagen GmbH, Hilden, Germany 19300 Germantown Rd, Germantown, MD 20874, USA) following the manufacturer's protocol. Quantification of DNA concentration and purity assessment was carried out by spectrophotometric methods. Given the proband's clinical features and biochemical and hormonal findings, the *CYP17A1* gene sequence analysis was performed with the preliminary

Figure 1. Skin color before treatment

diagnosis of 17OHD. All coding exons and exon-intron regions of the *CYP17A1* gene were sequenced using next-generation sequencing technology (Miseq, Illumina Inc., San Diego, CA, USA). To call variants, sequencing data were aligned with the human reference genome, hg19. Genetic analysis identified a homozygous non-sense variation [(NM_000102): c.238C>T; p.Gln80*] in the *CYP17A1* gene. The variation was not present in the ExAC, dbSNP, ClinVar, or HGMD databases, and was predicted to be likely pathogenic according to the ACMG criteria (PVS1, PM2) (8). The segregation analysis revealed that the parents were both heterozygous for the same *CYP17A1* c.238C>T(p. Gln80*) variant. Hydrocortisone treatment was initiated (10 mg/m^2/day in three doses). The proband underwent 24-hours blood pressure monitoring and echocardiography which were normal. The patient was referred for psychiatric consultation. After hydrocortisone treatment, hyperpigmentation regressed during follow-up. Sex steroid replacement was planned according to the gender chosen at the age of onset of puberty.

Written informed consent was obtained from the family of the patient for publication of this report.

Discussion

In 17OHD, patients are usually diagnosed during adolescence because of delayed puberty or amenorrhea. The diagnosis of 17OHD before puberty is very rare unless there is a known family history (9). The main reason for presentation at pubertal ages is the absence of clinical signs of glucocorticoid deficiency and complete enzyme activity impairment in most patients, which results in normal female external genitalia in both sexes. Severe symptomatic hypertension in both 46, XX and 46, XY patients or inadequate virilization of external genitalia in 46, XY partial 17OHD may facilitate earlier diagnosis of the condition (9,10). Our case is important because she was diagnosed at an early age without hypertension, delayed puberty or ambiguous genitalia. An abdominal ultrasound examination performed because of abdominal pain during treatment for NHL could not visualize any ovaries. Subsequently, we diagnosed hypergonadotropic hypogonadism. Evaluation of adrenal function should be included in the etiological evaluation of hypergonadotropic hypogonadism in girls, after excluding Turner syndrome (11). The patient had no Turner syndrome stigmata. Chemotherapy may also cause hypergonadotropic hypogonadism but because of the very short duration of chemotherapy before diagnosis of hypergonadotropic hypogonadism, we did not consider chemotherapy in the etiology.

Table 1. The biochemical and hormonal findings of the patient at presentation

Laboratory evaluation	Result	Reference range
Sodium (mmol/L)	142	136-145
Potassium (mmol/L)	3.9	3.5-4.5
FSH (mIU/mL)	41.55	2.1-11.1
LH (mIU/mL)	32.86	<11.9
ACTH (ng/L)	199.5	7.2-63.3
Cortisol (ug/dL)	0.59	50-250
Estradiol (pg/mL)	<5.00	6-27
Total testosterone (ng/dL)	<2.5	0-75
11-DOC (ug/L)	0.7	0-0.3
AMH (ng/mL)	16	1.7-104.5
17-OHP (ug/L)	0.15	<1
DHEA-S (ug/L)	20.64	160-960
Androstenedione (ug/L)	0.034	0.42-1
Progesterone (ng/ml)	6.61	<0.33
Corticosterone (ug/L)	181	0.18-19.7
Aldosterone (ng/L)	<1.1	2.5-35.7
Renin (ng/dL)	<3.7	3.7-43.2

FSH: follicle-stimulating hormone, LH: luteinizing hormone, ACTH: adrenocorticotropic hormone, DHEA-S: dehydroepiandrosterone sulfate, 17OHP: 17α-hydroxyprogesterone, 11-DOC: 11-deoxyicorticosterone, AMH: anti-Müllerian hormone

Biochemical investigations demonstrated that there were decreased concentrations of estradiol, total testosterone, DHEA-S, androstenedione, and cortisol, as well as increased concentrations of progesterone, corticosterone, 11-DOC, and ACTH. The low levels of estradiol and testosterone led to female genitalia even though the karyotype was 46, XY. Based on the clinical, biochemical, and molecular features, the patient was diagnosed with 17OHD. In cases of 17OHD, steroid synthesis in both the adrenal glands and gonads is impaired (12). This leads to complete female external genitalia in both sexes when there is complete enzyme deficiency.

Since ACTH and melanocyte-stimulating hormone are produced from proopiomelanocortin, hyperpigmentation may be observed in patients with 17OHD. However, ACTH concentration is not as high and hyperpigmentation is not as marked in patients with 17OHD compared with 21-hydroxylase, and 11β-hydroxylase deficiency (8). The presented case had mild hyperpigmentation, evident from the age of four years old. This color change was misdiagnosed as an allergic reaction and she used allergy medications which were ineffective. Furthermore, the proband's parents reported increased pigmentation since the initiation of chemotherapy for NHL which suggested increased stress and a compensatory increase in ACTH. Significant hyperpigmentation in the folds and darkening of the skin color decreased markedly approximately two weeks after hydrocortisone treatment was started (Figure 2). In cases of unexpected hyperpigmentation of the skin, especially in the skin folds, adrenal function should be checked.

In addition, increased ACTH leads to a elevated 11-DOC production. High levels of 11-DOC induce sodium and fluid retention and loss of potassium and hydrogen, and consequently hypertension, because of the potent mineralocorticoid effect of 11-DOC (13). In the presented case hypokalemia and hypertension were not detected. Ambulatory blood pressure monitoring and echocardiography were normal. At the time of diagnosis, 10-15% of individuals with 17OHD are normotensive and/or normokalemic. Dundar et al. (10) reported hypertension in approximately 75% of patients at the time of diagnosis. The heterogeneity of hypertension and hyperkalemia can be explained by the variance in target tissue sensitivity of various cortisol precursors, which show mineralocorticoid activity. The response in females to increased DOC is lower (14). In one study, hypertension was detected in one of the two patients with the same ethnicity and the same mutation of complete 17OHD, while the other was reported to be normotensive. However, in this case, the patient with hypertension was also obese (15). Thus, the role of gender, environmental variables, body habitus and ethnicity may explain variations in the presence and severity of hypertension in 17OHD patients. Since hydrocortisone helps to reduce 11-DOC and ACTH levels, hypertension is not expected to develop after treatment is started. Nevertheless, blood pressure should be monitored. One of the benefits of early recognition and management of 17OHD is to prevent or alleviate the long-term morbidity associated with hypertension.

Aldosterone was low in the presented case. In 17OHD, the immediate precursors of aldosterone are elevated, but aldosterone tends to be low. 11-DOC is assumed to inhibit renin and aldosterone synthase, resulting in sodium retention and volume expansion. However, treatment of 17OHD with glucocorticoids resulted in normal aldosterone levels (16).

Figure 2. Skin color after treatment

In 17OHD, findings of adrenal failure are rare, because of excessive production of corticosterone, which has a weak glucocorticoid effect. Thus, excessive corticosterone in 17OHD tends to mask the symptoms of cortisol deficiency, as in the presented case (5). However, hyperpigmentation became prominent during chemotherapy. Glucocorticoid (hydrocortisone 10 mg three times daily) was administered after the diagnosis of 17OHD was established. Although it is known that adrenal insufficiency does not develop in these patients, our patient was receiving chemotherapy and other symptoms of adrenal insufficiency could have been observed in severe infections due to neutropenia.

Genetic counseling, psychiatric evaluation, and follow-up were suggested for the presented patient. There was a novel, homozygous Q80* variant in *CYP17A1*. Since this variant is expected to cause a severely truncated P450c17 enzyme, we might expect complete 17OHD. Reports suggest gonadectomy in adolescence is appropriate in 46, XY girls with complete 17OHD due to the risk of malignant transformation of the abdominal testes (1). We planned gonadectomy, if accepted, after a psychiatric evaluation. In addition, sex hormone replacement therapy is recommended in adolescence for secondary sexual development, maintenance of female sexual characteristics, and stimulation of epiphyseal closure (11).

Conclusion

Early diagnosis of 17OHD may be challenging because of the low prevalence of the condition and the diverse clinical, biochemical, and molecular presentations. In the presence of unexplained hyperpigmentation and hypergonadotropic hypogonadism, the hypothalamic-pituitary-adrenal axis should be evaluated to investigate 17OHD.

Ethics

Informed Consent: Written informed consent was obtained from the family of the patient for publication of this report.

Footnotes

Authorship Contributions

Surgical and Medical Practices: Niran Tekkeli, İlknur Kurt, Nevin Yalman, Çetin Timur, Elif Sağsak, Concept: İlknur Kurt, Design: Elif Sağsak, Data Collection or Processing: Niran Tekkeli, İlknur Kurt, Nevin Yalman, Çetin Timur, Şenol Demir, Analysis or Interpretation: Niran Tekkeli, Şenol Demir, Elif Sağsak, Literature Search: Niran Tekkeli, Elif Sağsak, Writing: Elif Sağsak.

Financial Disclosure: The authors declared that this study received no financial support.

References

1. Miller WL, Auchus RJ. The molecular biology, biochemistry, and physiology of human steroidogenesis and its disorders. Endocr Rev. 2011;32:81-151. Epub 2010 Nov 4
2. Lieberman S, Warne PA. 17-hydroxylase: an evaluation of the present view of its catalytic role in steroidogenesis. J Steroid Biochem Mol Biol. 2001;78:299-312.
3. Auchus RJ. The genetics, pathophysiology, and management of human deficiencies of P450c17. Endocrinol Metab Clin North Am. 2001;30:101-119, vii.
4. Auchus RJ. Steroid 17-hydroxylase and 17,20-lyase deficiencies, genetic and pharmacologic. J Steroid Biochem Mol Biol. 2017;165:71-78. Epub 2016 Feb 6
5. Keskin M, Uğurlu AK, Savaş-Erdeve Ş, Sağsak E, Akyüz SG, Çetinkaya S, Aycan Z. 17α-hydroylase/17,20-lyase deficiency related to P.Y27*(c.81C>A) mutation in CYP17A1 gene. J Pediatr Endocrinol Metab. 2015;28:919-921.
6. Sun M, Mueller JW, Gilligan LC, Taylor AE, Shaheen F, Noczyńska A, T'Sjoen G, Denvir L, Shenoy S, Fulton P, Cheetham TD, Gleeson H, Rahman M, Krone NP, Taylor NF, Shackleton CHL, Arlt W, Idkowiak J. The broad phenotypic spectrum of 17α-hydroxylase/17,20-lyase (CYP17A1) deficiency: a case series. Eur J Endocrinol. 2021;185:729-741.
7. Neyzi O, Bundak R, Gökçay G, Günöz H, Furman A, Darendeliler F, Baş F. Reference values for weight, height, head circumference, and body mass index in Turkish children. J Clin Res Pediatr Endocrinol. 2015;7:280-293.
8. Richards S, Aziz N, Bale S, Bick D, Das S, Gastier-Foster J, Grody WW, Hegde M, Lyon E, Spector E, Voelkerding K, Rehm HL; ACMG Laboratory Quality Assurance Committee. Standards and guidelines for the interpretation of sequence variants: a joint consensus recommendation of the American College of Medical Genetics and Genomics and the Association for Molecular Pathology. Genet Med. 2015;17:405-424. Epub 2015 Mar 5
9. Kurnaz E, Kartal Baykan E, Türkyılmaz A, Yaralı O, Yavaş Abalı Z, Turan S, Bereket A, Çayır A, Guran T. Genotypic sex and severity of the disease determine the time of clinical presentation in steroid 17α-hydroxylase/17,20-lyase deficiency. Horm Res Paediatr. 2020;93:558-566. Epub 2021 Mar 29
10. Fontenele R, Costa-Santos M, Kater CE. 17α-hydroxylase deficiency is an underdiagnosed disease: high frequency of misdiagnoses in a large cohort of brazilian patients. Endocr Pract. 2018;24:170-178. Epub 2017 Nov 16
11. Dundar I, Akinci A, Camtosun E, Ciftci N, Kayas L. Presentation, diagnosis, and follow-up characteristics of 17α-hydroxylase deficiency cases with exon 1-6 deletion (founder mutation) in the CYP17A1gene: 20-year single-center experience. Sex Dev. 2023;17:43-50. Epub 2023 Jan 18
12. Voutilainen R, Miller WL. Developmental expression of genes for the stereoidogenic enzymes P450scc (20,22-desmolase), P450c17 (17 alpha-hydroxylase/17,20-lyase), and P450c21 (21-hydroxylase) in the human fetus. J Clin Endocrinol Metab. 1986;63:1145-1150.
13. Mula-Abed WA, Pambinezhuth FB, Al-Kindi MK, Al-Busaidi NB, Al-Muslahi HN, Al-Lamki MA. Congenital adrenal hyperplasia due to 17-alpha-hydoxylase/17,20-lyase deficiency presenting with hypertension and pseudohermaphroditism: first case report from Oman. Oman Med J. 2014;29:55-59.
14. Kawanishi H, Hasegawa Y, Nakano D, Ohkita M, Takaoka M, Ohno Y, Matsumura Y. Involvement of the endothelin ET(B) receptor in gender differences in deoxycorticosterone acetate-salt-induced hypertension. Clin Exp Pharmacol Physiol. 2007;34:280-285.
15. Keskin M, Uğurlu AK, Savaş-Erdeve Ş, Sağsak E, Akyüz SG, Çetinkaya S, Aycan Z. 17α-hydroylase/17,20-lyase deficiency related to P.Y27*(c.81C>A) mutation in CYP17A1 gene. J Pediatr Endocrinol Metab. 2015;28:919-921.
16. Bassett MH, White PC, Rainey WE. The regulation of aldosterone synthase expression. Mol Cell Endocrinol. 2004;217:67-74.

CASE REPORT

JCRPE Journal of Clinical Research in Pediatric Endocrinology

DOI: 10.4274/jcrpe.galenos.2024.2024-3-8
J Clin Res Pediatr Endocrinol 2026;18(Suppl 1):6-11

Autosomal Recessive Hypophosphatemic Rickets Type 2 Associated with a Novel *ENPP1* Variant in a Taiwanese Girl

Han-Yi Lin[1], Ni-Chung Lee[2], Meng-Ju Melody Tsai[3], Ting-Ming Wang[4], Yi-Ching Tung[5]

[1]National Taiwan University Hospital Hsinchu Branch, Department of Pediatrics, Hsinchu, Taiwan
[2]National Taiwan University Hospital, Department of Medical Genetics, Taipei, Taiwan
[3]National Taiwan University Hospital Yunlin Branch, Department of Pediatrics, Douliu, Yunlin, Taiwan
[4]National Taiwan University Hospital, Department of Orthopedic Surgery, Taipei, Taiwan
[5]National Taiwan University Hospital, Department of Pediatrics, Taipei, Taiwan

Cite this article as: Lin H-Y, Lee N-C, Tsai M-J M, Wang T-M, Tung Y-C. Autosomal recessive hypophosphatemic rickets type 2 associated with a novel *ENPP1* variant in a Taiwanese girl. J Clin Res Pediatr Endocrinol. 2026;18(Suppl 1):6-11

What is already known on this topic?

Autosomal recessive hypophosphatemic rickets type 2 (ARHR2) is a rare genetic disorder caused by a variant of the gene encoding ectonucleotide pyrophosphatase/phosphodiesterase 1 (*ENPP1*). Use of oral phosphates and active vitamin D can improve bowing of the legs and growth although generalized arterial calcification may occur and should be monitored.

What this study adds?

The present case describes a patient with a novel *ENPP1* variant, c.1092-42A>G. ARHR2 should be considered if hypophosphatemic rickets with elevated FGF23 level without dominant inheriting family history, even in patients of normal stature.

ABSTRACT

Autosomal recessive hypophosphatemic rickets (ARHR) type 2 (ARHR2) is a rare form of hypophosphatemic rickets (HR) caused by a variant of the gene encoding ectonucleotide pyrophosphatase/phosphodiesterase 1 (*ENPP1*). Our patient presented with a history of unsteady gait and progressively bowing legs that had commenced at the age of one year. Laboratory tests revealed elevated fibroblast growth factor 23 level, hypophosphatemia, and high urine phosphate level. Radiography revealed the typical features of rickets. Next-generation sequencing identified a previously reported c.783C>G (p.Tyr261Ter) and a novel c.1092-42A>G variant in *ENPP1*. The patient was prescribed oral phosphates and active vitamin D and underwent guided growth of both distal femora and proximal tibiae commencing at the age of three years. No evidence of generalized arterial calcification was apparent during follow-up, and growth rate was satisfactory.

Corresponding Author: Yi-Ching Tung, MD, National Taiwan University Hospital, Department of Pediatrics, Taipei, Taiwan
E-mail: dtped004@gmail.com **ORCID:** orcid.org/0000-0003-0466-3891
Conflict of interest: None declared
Received: 30.04.2024 **Accepted:** 08.06.2024 **Epub:** 16.07.2024 **Publication Date:** 02.06.2026

©Copyright 2026 by Turkish Society for Pediatric Endocrinology and Diabetes / The Journal of Clinical Research in Pediatric Endocrinology published by Galenos Publishing House.
Licensed under a Creative Commons Attribution-NonCommercial-NoDerivatives 4.0 (CC BY-NC-ND) International License.

Keywords: Encoding ectonucleotide pyrophosphatase/phosphodiesterase 1 (ENPP1), fibroblast growth factor 23 (FGF23), hypophosphatemic rickets

Introduction

Hereditary hypophosphatemic rickets (HR) is a rare disorder characterized by renal phosphate wasting, which in turn impairs bone matrix mineralization. In recent decades, the role played by a major phosphatonin, fibroblast growth factor 23 (FGF23), has been clarified. FGF23 is secreted by osteocytes to regulate phosphate metabolism by reducing renal phosphate reabsorption (1). FGF23 also impairs 1,25 dihydroxyvitamin D activation. The most common form of FGF23-related HR is X-linked HR caused by mutational inactivation of the gene encoding the phosphate-regulating endopeptidase (2). However, several other types of FGF23-related HR are inherited in both autosomal-dominant and -recessive manners. Of these, autosomal-recessive HR type 2 (ARHR2), caused by bi-allelic pathogenic variants of the gene encoding ectonucleotide pyrophosphatase/phosphodiesterase 1 (*ENPP1*), is rare. Variants in *ENPP1* were first associated with generalized arterial calcification of infancy (GACI) (3). GACI may trigger sudden death before six months of age. Variants in *ENPP1* also increase serum FGF23 levels (4,5), in turn causing autosomal-recessive HR. Here, we report a girl with bowed legs and hypophosphatemia who was finally diagnosed as a rare case of ARHR2.

Case Report

A 26-month-old girl visited our pediatric endocrine clinic. Her parents reported frequent falls, an unsteady gait, and progressive leg bowing that had commenced more than one year earlier. She had been born prematurely, at 35 weeks gestation, and weighed 2,480 g at birth. Her developmental milestones were within the normal ranges. There was no family history of sudden infant death or genu varum. At the first visit, her height was 88.4 cm (50-75th percentile) and her weight 14.8 kg (90-97th percentile). Physical examination revealed bilateral genu varum and widening of the wrists and especially the ankles (Figure 1A). Neither rachitic rosary nor frontal bossing was observed. Radiography revealed fraying, splaying, and cupping of the metaphyses of both knees, as well as bowed legs with severe deviations in the mechanical axes (Figure 1B). Laboratory tests revealed an elevated alkaline phosphatase (ALP) level (674 U/L; normal range, 69-325 U/L), normocalcemia, hypophosphatemia (phosphate level, 0.97 mmol/L; normal range, 1.2-2.2 mmol/L), and a normal serum intact parathyroid hormone (iPTH) level. The ratio of the tubular maximum reabsorption of phosphate to the glomerular filtration rate was 2.8 mg/dL (normal range, 2.9-6.5 mg/dL), indicating insufficient renal tubular phosphate reabsorption despite the hypophosphatemia. The serum FGF23 level was elevated at 84.98 pg/mL (normal range, 8-54.3 pg/mL), leading to a diagnosis of FGF23-related HR. The biochemical data for the patient and her parents are listed in Table 1.

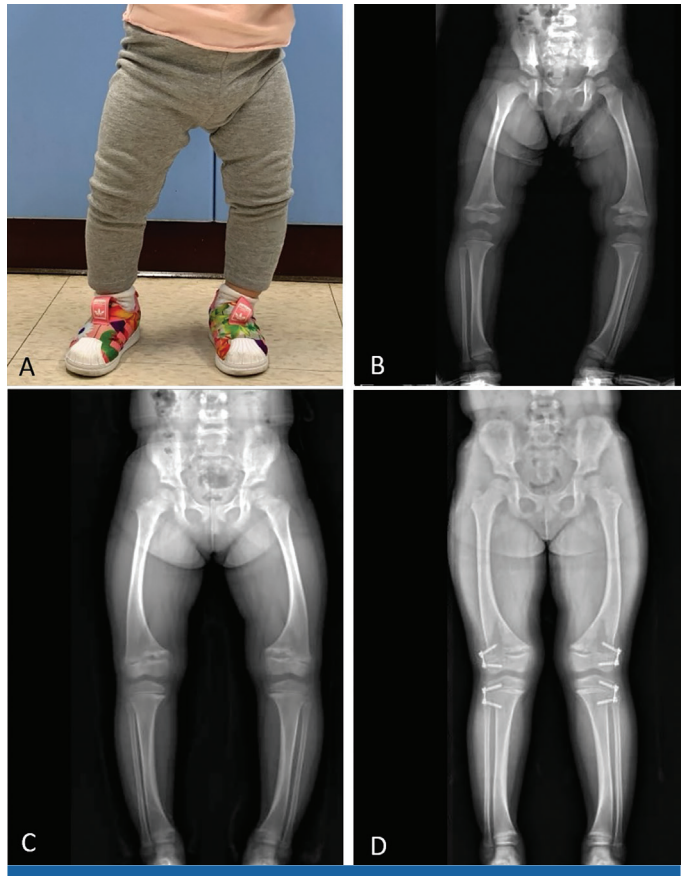

Figure 1. A) Bowlegs at diagnosis, **B)** X-ray of lower extremities at diagnosis, **C)** X-ray of lower extremities before guided growth, **D)** X-ray of lower extremities after guided growth and treatment of phosphate and calcitriol

Whole-exome sequencing (WES) revealed the presence of the *ENPP1* compound heterozygous variant c.783C>G (p.Tyr261Ter; regarded as "pathogenic" by the American College of Medical Genetics) in the mother and c.1092-42A>G in the father ("likely pathogenic"). SpliceAI software predicted that c.1092-42A>G is a "gain of acceptor" variant (delta score 0.79) (Figure 2). No vessel calcification was apparent on cardiac sonography. There were no symptoms and signs of hypertension, renal failure or heart failure during follow-up.

We commenced conventional therapy (40 mg/kg/day) phosphate salts. This dose was then titrated up to 50 mg/kg/day and combined with active vitamin D at 15-25 ng/kg/day.

Table 1. The auxological and biochemical data of patient and her parents

	Patient	Father	Mother
Height, cm	88.4	179	158
Height, SDS	0.61	1.32	-0.29
Serum			
Ca, mmol/L	2.68 (2.2-2.7)	2.49 (2.2-2.7)	2.31 (2.2-2.7)
P, mmol/L	0.97 (1.2-2.2)	1.0 (0.8-1.4)	0.97 (0.8-1.4)
Mg, mmol/L	0.81 (0.7-1.2)	0.90 (0.7-1.2)	0.84 (0.7-1.2)
ALP, U/L	674 (69-325)	67 (28-95)	37 (28-95)
Cre, umol/L	26.53 (25-60)	61.89 (50-110)	44.21 (65-120)
iPTH, pg/mL	37.5 (15-70)	110.4 (15-70)	80.9 (15-70)
25(OH)D, ng/mL	28.5 (20-50)	29.0 (20-50)	22.4 (20-50)
FGF23, pg/mL	84.98 (8-54.3)		
Urine			
TRP, %	92.7 (85-95)	86.7 (88-90)	92.95 (88-90)
TmP/GFR, mg/dL	2.8 (2.9-6.5)	2.7 (2.5-4.5)	2.8 (2.5-4.5)

Reference values are presented in parenthesis for age-specific criteria.
SDS: standard deviation score, Ca: calcium, P: phosphate, Mg: magnesium, ALP: alkaline phosphatase, Cre: creatinine, iPTH: intact parathyroid hormone, 25(OH)D: 25-hydroxyvitamin D, FGF23: fibroblast growth factor 23, TRP: tubular reabsorption of phosphate, Tmp/GFR: ratio of the maximum rate of tubular phosphate reabsorption to the glomerular filtration rate

After one year of this therapy, guided growth of both distal femora and proximal tibiae commenced when she was 3 years and 4 months old because of progressive genu varum (Figure 1C). The biochemical data gradually improved, with the ALP level decreasing to 460 U/L. Follow-up radiography revealed that both femoral metaphyses had healed, and that the mechanical axis deviations of the lower extremities had been corrected (Figure 1D). Her growth curve remained within the normal range, and neither bony nor gastrointestinal discomfort was reported.

Methods

Serum total calcium, phosphorus, magnesium, creatinine and ALP and urine phosphorus and creatinine were assayed using an automatic biochemical analyzer (Beckman Coulter, AU analysers, Brea, California, USA). Serum iPTH and 25-hydroxy vitamin D (25-OHD) levels were measured by chemiluminescence assay (ARCHITECT system, Abbott, North Chicago, IL, USA). FGF23 was measured by two-site enzyme-linked immunosorbent assay (FGF23 ELISA kit, KAINOS), Laboratories Inc, Bunkyo-ku, Tokyo, Japan. The WES data were generated using Nova Seq platforms (Illumina Inc., San Diego, CA, USA) DNA was extracted from blood samples. Sequenced was done by the captured-based method (Roche KAPA HyperExome, Wilmington, MA, USA). Raw reads

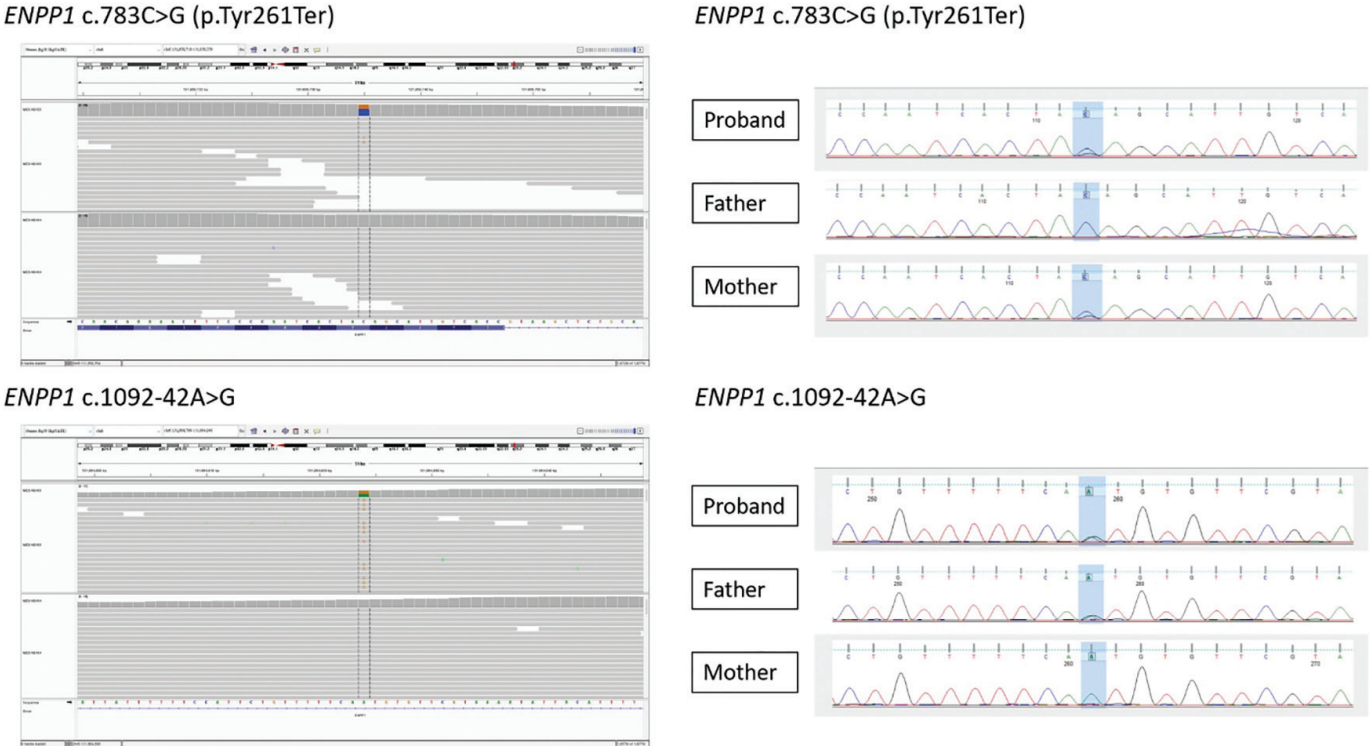

Figure 2. Integrative Genomics Viewer image and Sanger sequencing electropherograms of the variants identified in this patient and her parents
ENPP1: ectonucleotide pyrophosphatase/phosphodiesterase 1

were mapped to GRhg38 genome and variants were called by the BWA (Burrows-Wheeler Aligner. http://bio-bwa.sourceforge.net), GATK (Genome Analysis Toolkit, Broad Institute: https://gatk.broadinstitute.org) and ANNOVAR, (Wang Genomics Lab: http://annovar.openbioinformatics.org).

Discussion

ENPP1 is an enzyme of the cell membrane that degrades adenosine triphosphate into adenosine monophosphate and pyrophosphate (PPi). PPi inhibits hydroxyapatite crystal deposition and thus plays an essential role in reducing calcification. A PPi deficiency triggers pathological vascular calcification (6). Inactivating *ENPP1* variants were first reported in eight unrelated children with GACI, formerly termed idiopathic infantile arterial calcification. The clinical manifestations include calcification of the elastic internal laminae of muscle arteries and stenosis attributable to myointimal proliferation (3). GACI is associated with a mortality rate of 55% within the first six months of life, caused by heart failure, arterial hypertension, multiorgan failure, and/or myocardial infarction. GACI is sometimes characterized by intimal proliferation without calcification with clinical findings of hypertension, pulmonary hypertension, and ischemic changes due to arterial stenosis (7). Survivors exhibit ectopic calcification and an elevated serum FGF23 level (8). Kaplan-Meier analysis predicted that survivors would develop HR before the age of 14 years (8). During follow-up, 5 of 19 (26.3%) survivors exhibited HR with renal phosphate loss (9), which was assumed to reflect an attempt to protect against arterial calcification (3). One of five HR patients treated with phosphates and calcitriol presented with worsening arterial stenoses (9). However, several later reports claimed that long-term treatment of HR alleviated bone pain and improved growth without increasing vascular calcification (8,10).

ARHR2 was first reported in a family of Bedouin origin (5). The earlier suggestion that hypophosphatemia protects arteries was replaced by the realization that excess FGF23 is the major pathogenetic feature in patients with *ENPP1* variants. However, the mechanism by which such variants increase the FGF23 level remains unknown (4,5). It was observed that *ENPP1*-deficient mice exhibit increased *FGF23* expression (11). The inactivation of *ENPP1* reduces PPi levels in soft tissues and results in local phosphate depletion in bone. The defect in bone mineralization causes increased FGF23 expression (12). In addition, it has been suggested that an increased level of FGF23 is an adaptive physiological response (13). ARHR2 patients exhibit short stature, early fusion of cranial sutures, rachitic skeletal deformities, lower limb deformities, progressive varus deformities, and bone pain (13). Some reported cases presented with progressive conductive hearing loss (14), pseudoxanthoma (15) and ossification of the posterior longitudinal ligament (16), all of which reflect ectopic calcification. Any family history of GACI, HR, and/or consanguinity should be carefully noted. In our patient, radiography identified typical rachitic traits, especially in the lower extremities. Laboratory tests revealed elevated FGF23-induced hypophosphatemia and increased urine phosphate excretion. A definitive diagnosis was made possible by *ENPP1* sequencing. Our patient presented with lower limb varus deformities at the time that she began to walk, and the deformities gradually worsened. The clinical presentation, laboratory data, and radiological findings were typical of HR, but her height was not short, perhaps attributable to high mid-parental height. ARHR2 should be considered if HR is accompanied by an elevated FGF23 level, even in patients of normal stature.

A total of 140 *ENPP1* variants have been identified to date, of which missense variants are the most common (70%) (17). In our patient, the variant in exon 7 (c.783C>G) has been reported to be associated with both GACI (18) and ARHR2 (19). In Chinese patients, c.783C>G is the most common ARHR2 variant (19). However, the c.1092-42A>G variant in intron 10 is a novel ARHR2 variant. No obvious correlations between *ENPP1* variants and phenotypes have yet been reported (Figure 3) and even siblings with the same variants differ markedly in phenotype (4,8,20).

ARHR2 treatment is generally the same as that for HR, which comprises phosphate and calcitriol supplementation to increase the serum phosphate level and normalize the ALP level. The aims are to eliminate limb deformities and bone pain and to promote growth. Gastrointestinal symptoms, such as abdominal pain and diarrhea, are acute side effects of phosphate supplementation, reducing adherence (13,21). Boyce et al. (22) recommended the initial doses of phosphate to be 25-30 mg/kg/day and calcitriol at 15 ng/kg/day. Previous reports have described the dosage of phosphate to range from 18 to 62.5 mg/kg/day and calcitriol from 10.2 to 37.5 ng/kg/day (4,10,14,16). In patients with a history of GACI, the maximum dosage was 18 mg/kg/day of phosphate and 18 ng/kg/day of calcitriol (10). Although there is no clear opinion, lower doses than in other HR types are recommended. No obvious association was apparent between worsening vascular calcification and treatment with phosphate and calcitriol after long-term follow-up (4,10). However, close monitoring of biochemical parameters and vascular calcification status is essential before and during treatment.

Surgical intervention may be necessary if a bone deformity progresses (23), and regular orthopedic follow-up must be scheduled (10,21). In our case, after phosphate and active vitamin D supplementation, guided growth of both distal femora and proximal tibiae was required because of progressive mechanical axial deviations. Both femoral metaphyses healed, the bowing of the legs improved, and the growth curve remained within the normal range. Since 2018, burosumab, a monoclonal antibody targeting FGF-23, has afforded good results in patients

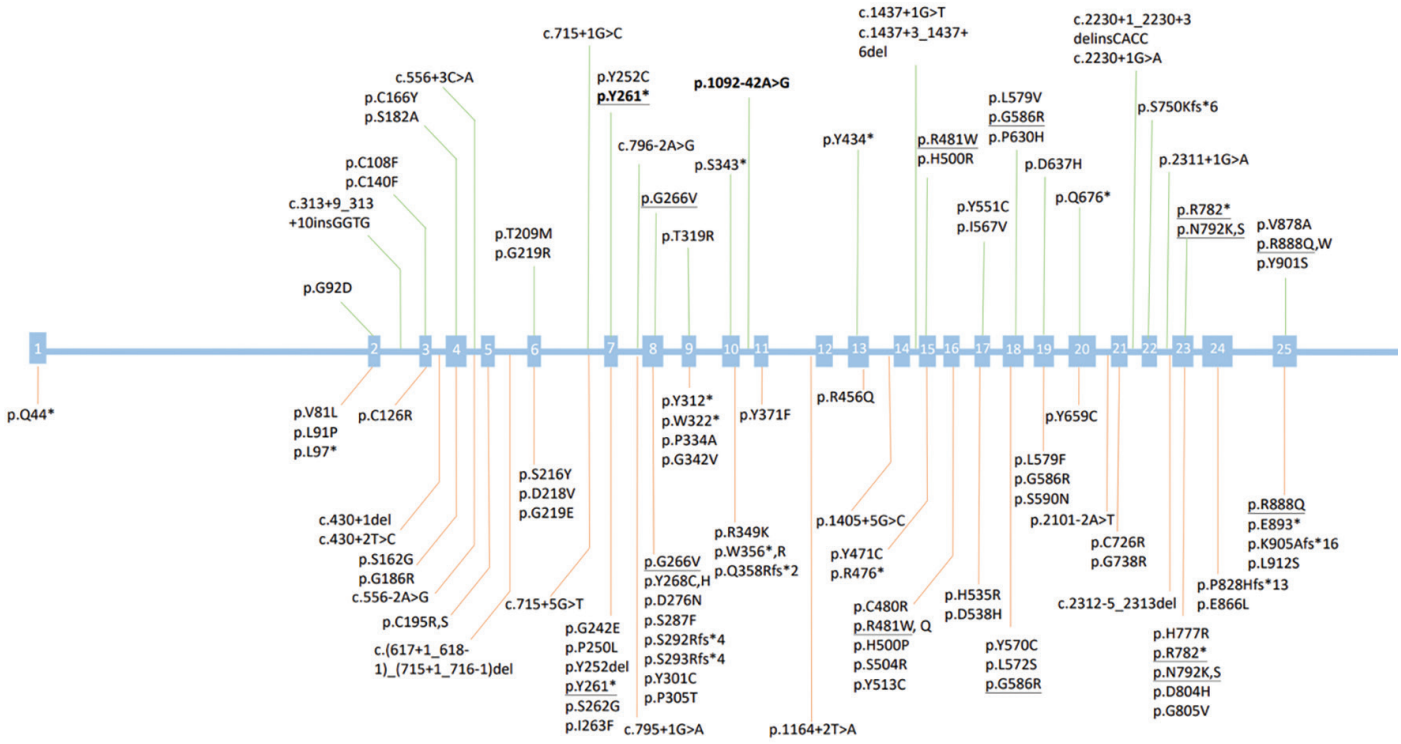

Figure 3. ENPP1 variants identified in patients with ARHR2 and GACI. The upper part shows variants associated with ARHR2, highlighted with a green line. In the lower part, other variants associated with GACI are indicated by an orange line. Variants associated with both GACI and ARHR2 are shown underlined. The variants of our patient are highlighted in bold

ENPP1: ectonucleotide pyrophosphatase/phosphodiesterase 1, ARHR2: autosomal recessive hypophosphatemic rickets type 2, GACI: generalized arterial calcification of infancy

with X-linked HR (24). Renal tubular phosphate reabsorption and linear growth improved, and the severity of the bone pain and rickets lessened. However, it has been suggested that burosumab may worsen ectopic calcification by upregulating ALP and downregulating PPi. Stern et al. (25) reported a patient with GACI and HR with *ENPP1* variants, in whom cardiac calcification worsened after treatment with burosumab for 20 months. Thus, the utility of burosumab in patients with ARHR2 remains controversial. This highlights the need to identify relevant variants before prescribing burosumab for HR patients. In *ENPP1*-deficient mice, *ENPP1* replacement therapies reduced pathological calcification and enhanced growth (26), thus showing considerable promise.

Study Limitations

There are two limitations in our case report. GACI is one of the presentations of *ENPP1* deficiency. We had followed up cardiac sonography without evidence of GACI till now. A computed tomography scan would be arranged either when symptoms develop or years later. The second one is that the novel intronic variant is pathogenic on *in silico* analyses, yet the functional analyses of this variant have not been conducted.

Conclusion

We report a novel *ENPP1* variant in a Taiwanese patient with compound heterozygous ARHR2. The skeletal varus deformity was similar to those of previous cases with *ENPP1* variants, but the stature of the index case was normal. Conventional treatment with phosphates and activated vitamin D promoted radiological bone healing and sustained growth without any evidence of vascular or ectopic calcification. However, long-term meticulous monitoring is essential for such patients.

Ethics

Informed Consent: Written informed guardian consent was obtained from the patient for publication of this case report and any accompanying images.

Footnotes

Authorship Contributions

Surgical and Medical Practices: Han-Yi Lin, Meng-Ju Melody Tsai, Ting-Ming Wang, Yi-Ching Tung, Concept: Han-Yi Lin, Ni-Chung Lee, Meng-Ju Melody Tsai, Ting-Ming Wang, Yi-Ching Tung, Design Han-Yi Lin, Ni-Chung Lee, Ting-Ming Wang, Yi-Ching Tung, Data Collection or Processing: Han-Yi Lin, Ni-Chung Lee, Meng-Ju Melody

Tsai, Yi-Ching Tung, Analysis or Interpretation: Han-Yi Lin, Ni-Chung Lee, Yi-Ching Tung, Literature Search: Han-Yi Lin, Meng-Ju Melody Tsai, Yi-Ching Tung, Writing: Han-Yi Lin, Ting-Ming Wang, Yi-Ching Tung.

Financial Disclosure: The authors declared that this study received no financial support.

References

1. Fukumoto S. FGF23-related hypophosphatemic rickets/osteomalacia: diagnosis and new treatment. J Mol Endocrinol. 2021;66:R57-R65.
2. Francis F, Hennig S, Korn B, Reinhardt R, de Jong P, Poustka A, Lehrach H, Rowe PSN, Goulding JN, Summerfield T, Mountford R, Read AP, Popowska E, Pronicka E, Davies KE, O'Riordan JLH, Econs MJ, Nesbitt T, Drezner MK, Oudet C, Pannetier S, Hanauer A, Strom TM, Meindl A, Lorenz B, Cagnoli B, Mohnike KL, Murken J, Meitinger T. A gene (PEX) with homologies to endopeptidases is mutated in patients with X-linked hypophosphatemic rickets. The HYP consortium. Nat Genet. 1995;11:130-136.
3. Rutsch F, Ruf N, Vaingankar S, Toliat MR, Suk A, Höhne W, Schauer G, Lehmann M, Roscioli T, Schnabel D, Epplen JT, Knisely A, Superti-Furga A, McGill J, Filippone M, Sinaiko AR, Vallance H, Hinrichs B, Smith W, Ferre M, Terkeltaub R, Nürnberg P. Mutations in ENPP1 are associated with 'idiopathic' infantile arterial calcification. Nat Genet. 2003;34:379-81.
4. Lorenz-Depiereux B, Schnabel D, Tiosano D, Häusler G, Strom TM. Loss-of-function ENPP1 mutations cause both generalized arterial calcification of infancy and autosomal-recessive hypophosphatemic rickets. Am J Hum Genet. 2010;86:267-272. Epub 2010 Feb 4
5. Levy-Litan V, Hershkovitz E, Avizov L, Leventhal N, Bercovich D, Chalifa-Caspi V, Manor E, Buriakovsky S, Hadad Y, Goding J, Parvari R. Autosomal-recessive hypophosphatemic rickets is associated with an inactivation mutation in the ENPP1 gene. Am J Hum Genet 2010;86:273-278. Epub 2010 Feb 4
6. Goding JW, Grobben B, Slegers H. Physiological and pathophysiological functions of the ecto-nucleotide pyrophosphatase/phosphodiesterase family. Biochim Biophys Acta. 2003;1638:1-19.
7. Dursun F, Turan İ, Bitkin EÇ, Bayramoğlu E, Çayır A, Erdeve ŞS, Çakır EDP, Çamtosun E, Dilek SO, Kırmızıbekmez H, Eser M, Türkyılmaz A, Karagüzel G. Natural history of ENPP1 deficiency: Nationwide Turkish Cohort Study of autosomal-recessive hypophosphataemic rickets type 2. Clin Endocrinol (Oxf). 2024;101:475-484. Epub 2024 Feb 7
8. Ferreira CR, Hackbarth ME, Ziegler SG, Pan KS, Roberts MS, Rosing DR, Whelpley MS, Bryant JC, Macnamara EF, Wang S, Müller K, Hartley IR, Chew EY, Corden TE, Jacobsen CM, Holm IA, Rutsch F, Dikoglu E, Chen MY, Mughal MZ, Levine MA, Gafni RI, Gahl WA. Prospective phenotyping of long-term survivors of generalized arterial calcification of infancy (GACI). Genet Med 2021;23:396-407. Epub 2020 Oct 2
9. Rutsch F, Böyer P, Nitschke Y, Ruf N, Lorenz-Depierieux B, Wittkampf T, Weissen-Plenz G, Fischer RJ, Mughal Z, Gregory JW, Davies JH, Loirat C, Strom TM, Schnabel D, Nürnberg P, Terkeltaub R; GACI Study Group. Hypophosphatemia, hyperphosphaturia, and bisphosphonate treatment are associated with survival beyond infancy in generalized arterial calcification of infancy. Circ Cardiovasc Genet. 2008;1:133-140.
10. Ferreira CR, Ziegler SG, Gupta A, Groden C, Hsu KS, Gahl WA. Treatment of hypophosphatemic rickets in generalized arterial calcification of infancy (GACI) without worsening of vascular calcification. Am J Med Genet A. 2016;170A:1308-1311. Epub 2016 Feb 9
11. Maulding ND, Kavanagh D, Zimmerman K, Coppola G, Carpenter TO, Jue NK, Braddock DT. Genetic pathways disrupted by ENPP1 deficiency provide insight into mechanisms of osteoporosis, osteomalacia, and paradoxical mineralization. Bone. 2021;142:115656. Epub 2020 Sep 24
12. Quarles LD. Skeletal secretion of FGF-23 regulates phosphate and vitamin D metabolism. Nat Rev Endocrinol. 2012;8:276-286.
13. Höppner J, Kornak U, Sinningen K, Rutsch F, Oheim R, Grasemann C. Autosomal recessive hypophosphatemic rickets type 2 (ARHR2) due to ENPP1-deficiency. Bone. 2021;153:116111. Epub 2021 Jul 9
14. Steichen-Gersdorf E, Lorenz-Depiereux B, Strom TM, Shaw NJ. Early onset hearing loss in autosomal recessive hypophosphatemic rickets caused by loss of function mutation in ENPP1. J Pediatr Endocrinol Metab. 2015;28:967-970.
15. Nitschke Y, Baujat G, Botschen U, Wittkampf T, du Moulin M, Stella J, Le Merrer M, Guest G, Lambot K, Tazarourte-Pinturier MF, Chassaing N, Roche O, Feenstra I, Loechner K, Deshpande C, Garber SJ, Chikarmane R, Steinmann B, Shahinyan T, Martorell L, Davies J, Smith WE, Kahler SG, McCulloch M, Wraige E, Loidi L, Höhne W, Martin L, Hadj-Rabia S, Terkeltaub R, Rutsch F. Generalized arterial calcification of infancy and pseudoxanthoma elasticum can be caused by mutations in either ENPP1 or ABCC6. Am J Hum Genet 2012;90:25-39. Epub 2011 Dec 29
16. Saito T, Shimizu Y, Hori M, Taguchi M, Igarashi T, Fukumoto S, Fujitab T. A patient with hypophosphatemic rickets and ossification of posterior longitudinal ligament caused by a novel homozygous mutation in ENPP1 gene. Bone. 2011;49:913-916. Epub 2011 Jul 2
17. Ralph D, Levine MA, Richard G, Morrow MM, Flynn EK, Uitto J, Li Q. Mutation update: variants of the ENPP1 gene in pathologic calcification, hypophosphatemic rickets, and cutaneous hypopigmentation with punctate keratoderma. Hum Mutat. 2022;43:1183-1200. Epub 2022 May 18
18. Ruf N, Uhlenberg B, Terkeltaub R, Nürnberg P, Rutsch F. The mutational spectrum of ENPP1 as arising after the analysis of 23 unrelated patients with generalized arterial calcification of infancy (GACI). Hum Mutat. 2005;25:98.
19. Liu ZQ, Chen XB, Song FY, Gao K, Qiu MF, Qian Y, Du M. [Homozygous ectonucleotide pyrophosphatase/phosphodiesterase 1 variants in a girl with hypophosphatemic rickets and literature review]. Zhonghua Er Ke Za Zhi. 2017;55:858-861. [in Chinese]
20. Dlamini N, Splitt M, Durkan A, Siddiqui A, Padayachee S, Hobbins S, Rutsch F, Wraige E. Generalized arterial calcification of infancy: phenotypic spectrum among three siblings including one case without obvious arterial calcifications. Am J Med Genet A. 2009;149A:456-460.
21. Linglart A, Biosse-Duplan M, Briot K, Chaussain C, Esterle L, Guillaume-Czitrom S, Kamenicky P, Nevoux J, Prié D, Rothenbuhler A, Wicart P, Harvengt P. Therapeutic management of hypophosphatemic rickets from infancy to adulthood. Endocr Connect. 2014;3:R13-R30.
22. Boyce AM, Gafni RI, Ferreira CR. Generalized arterial calcification of infancy: new insights, controversies, and approach to management. Curr Osteoporos Rep. 2020;18:232-241.
23. Choe Y, Shin CH, Lee YA, Kim MJ, Lee YJ. Case report and review of literature: autosomal recessive hypophosphatemic rickets type 2 caused by a pathogenic variant in *ENPP1* gene. Front Endocrinol (Lausanne). 2022;13:911672.
24. Carpenter TO, Whyte MP, Imel EA, Boot AM, Högler W, Linglart A, Padidela R, Van't Hoff W, Mao M, Chen CY, Skrinar A, Kakkis E, San Martin J, Portale AA. Burosumab therapy in children with X-linked hypophosphatemia. N Engl J Med. 2018;378:1987-1998.
25. Stern R, Levi DS, Gales B, Rutsch F, Salusky IB. Correspondence on "Prospective phenotyping of long-term survivors of generalized arterial calcification of infancy (GACI)" by Ferreira et al. Genet Med. 2021;23:2006-7. Epub 2021 Jun 14
26. Cheng Z, O'Brien K, Howe J, Sullivan C, Schrier D, Lynch A, Jungles S, Sabbagh Y, Thompson D. INZ-701 prevents ectopic tissue calcification and restores bone architecture and growth in ENPP1-deficient mice. J Bone Miner Res. 2021;36:1594-1604. Epub 2021 May 5

CASE REPORT

JCRPE Journal of Clinical Research in Pediatric Endocrinology

DOI: 10.4274/jcrpe.galenos.2024.2024-2-1
J Clin Res Pediatr Endocrinol 2026;18(Suppl 1):12-19

Hereditary Pheochromocytoma as a Major Manifestation of von Hippel Lindau Disease (vHL) in Childhood: Long-term Follow-up of Five Patients with vHL from One Family

Katarzyna Pasternak-Pietrzak, Agata Kozłowska, Elżbieta Moszczyńska

The Children's Memorial Health Institute (CMHI), Department of Endocrinology and Diabetology, Warsaw, Poland

Cite this article as: Pasternak-Pietrzak K, Kozłowska A, Moszczyńska E. Hereditary pheochromocytoma as a major manifestation of von Hippel Lindau disease (vHL) in childhood: long-term follow-up of five patients with vHL from one family. J Clin Res Pediatr Endocrinol. 2026;18(Suppl 1):12-19

What is already known on this topic?

The presentation of many lesions associated with von Hippel-Lindau disease (vHL) occurs in the third and fourth decades of life. However, the age range of initial manifestations is wide and children are particularly vulnerable, being at risk of developing hemangioblastomas and pheochromocytoma (PHEO) that can remain clinically occult until symptoms become severe. There is a lack of published data regarding the long-term care of patients with vHL diagnosed with PHEO in childhood.

What this study adds?

We present five patients with vHL from one family with PHEO diagnosed in childhood. PHEO was the main manifestation of the disease and extensive follow-up data [47 yrs (Patient 1); 32 yrs (Patient 2); 27 yrs (Patient 3); 1.5 yrs (Patient 4) and 0.7 yrs (Patient 5), respectively] from the first PHEO diagnosis is available. This duration of follow-up data is unique in the literature concerning the pediatric vHL population.

ABSTRACT

Von Hippel-Lindau disease (vHL) is a hereditary, autosomal dominant syndrome manifested by a predisposition to the occurrence of benign and malignant neoplasms. The spectrum of vHL-related neoplasms includes: pheochromocytoma (PHEO), central nervous system and retinal hemangioblastomas, renal clear cell carcinoma, epididymal cystadenomas, and pancreatic neuroendocrine tumors, as well as visceral, especially renal and pancreatic, cysts. We report a single family including five patients with genetically confirmed vHL in which every member had PHEO diagnosed during pediatric care. The presented family had a missense variant in the *VHL* gene (exon 1, g.A451G, p.S80G) which has been connected with an increased risk of PHEO. Performing screening laboratory and imaging tests in patients with genetically confirmed vHL

Corresponding Author: Katarzyna Pasternak-Pietrzak, MD, PhD, The Children's Memorial Health Institute (CMHI), Department of Endocrinology and Diabetology, Warsaw, Poland
E-mail: k.pasternak-pietrzak@ipczd.pl **ORCID:** orcid.org/0000-0001-9602-5023
Conflict of interest: None declared.
Received: 17.04.2024 **Accepted:** 24.08.2024 **Epub:** 23.09.2024 **Publication Date:** 02.06.2026

©Copyright 2026 by Turkish Society for Pediatric Endocrinology and Diabetes / The Journal of Clinical Research in Pediatric Endocrinology published by Galenos Publishing House.
Licensed under a Creative Commons Attribution-NonCommercial-NoDerivatives 4.0 (CC BY-NC-ND) International License.

may help to avoid the occurrence of disease symptoms and to perform elective surgery under safe conditions. Due to the risk of coexisting pathologies and the complexity of the disease, patients with vHL require long-term care.

Keywords: von Hippel-Lindau syndrome, pheochromocytoma, adrenal paraganglioma, metanephrines

Introduction

Von Hippel-Lindau disease (vHL) is a hereditary, autosomal dominant syndrome manifested by a predisposition to the occurrence of benign and malignant neoplasms. It is caused by a highly penetrant mutation in the *VHL* gene (3p25.3), a classic example of a suppressor gene. The spectrum of vHL-related neoplasms includes: pheochromocytoma (PHEO); central nervous system (CNS) and retinal hemangioblastomas (HB); renal clear cell carcinoma (RCC); epididymal cystadenomas; and pancreatic neuroendocrine tumours (NETs), as well as visceral cysts especially affecting the renal system and pancreas (1). The prevalence of vHL is as high as 1:36,000 (2). The prevalence of PHEO in vHL is estimated at 15-30%; these are usually benign tumours (3). We report a single family with genetically confirmed vHL in which every member had PHEO diagnosed during pediatric care.

Case Report

Genetic pedigree of patients is shown in Figure 1.

Case 1

(Patient 1- the mother of Patients 2 and 3). An 18-year-old woman underwent subtotal right adrenalectomy. Unfortunately, there is no detailed medical documentation available from this period, but she was subsequently diagnosed with PHEO, confirmed by histopathological examination. At the age of 21 years, she was admitted to the internal medicine department due to the recurrence of hypertension, tachycardia, subfebrile episodes, poor heat tolerance and weight loss of 10 kg within six months. Daily noradrenaline, metoxycatecholamines and vanillylmandelic acid (VMA) excretion were elevated (Table 1). Abdominal computed tomography (CT) showed a nodular mass of about 4.5 cm in diameter at the upper area of the left kidney. She was treated with labetalol and was referred to the surgical institute for surgical treatment. Left-sided adrenalectomy was performed. She was treated with hydrocortisone (HC) and fludrocortisone. Replacement therapy was discontinued after eight years, when normal adrenal function was evident. At the age of 58 yrs the patient was admitted due to an adrenal crisis and since then she has been treated with HC and fludrocortisone. Three years later abdominal magnetic resonance imaging (MRI) showed a lesion in her pancreas which was confirmed by somatostatin receptor scintigraphy (SRS) and positron emission tomography (PET). A biopsy was performed and the histopathology suggested a diagnosis of NET (G2). Due to lack of patient's consent for the surgery, treatment with somatostatin analogue (lanreotide) was started. Currently, she is 65 years old and continues under the care of adult endocrinology.

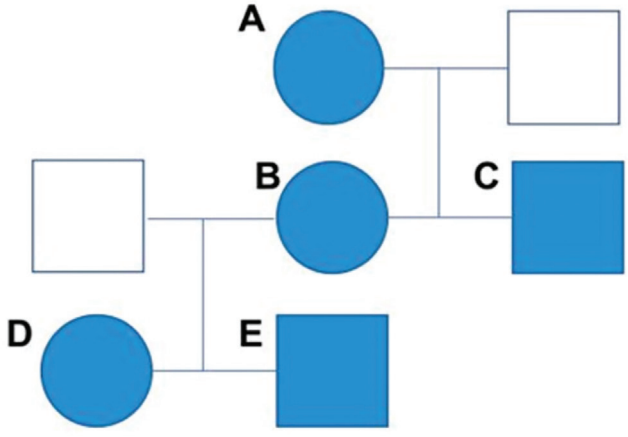

Figure 1. Genetic pedigree of patients. A) Patient 1, B) Patient 2, C) Patient 3, D) Patient 4, E) Patient 5

Case 2

(Patient 2- the mother of Patients 4 and 5). A 13-year-old girl with a confirmed family history of vHL (*VHL* mutation in her mother, Patient 1) was admitted to the pediatric ward because of periodic increases in blood pressure (BP) with headaches for six months, excessive sweating and cardiac symptoms (chest pain, palpitations) for the last two months. She was investigated for tachycardia and elevated blood pressure (up to 150/100 mmHg), which normalized after treatment with phenoxybenzamine and propranolol. Biochemically, she had elevated levels of noradrenaline, adrenaline and VMA in urine (Table 1). CT showed a large tumor measuring 4x4 cm in the central part of the right adrenal gland and a small nodule of about 1 cm in the lower part of the left adrenal gland. ^{131}I/^{123}I-Metaiodobenzylguanidine (MIBG) scintigraphy revealed a large focus of tracer accumulation above the right kidney and a much smaller one on the left side. She was eligible for surgery. Right-sided adrenalectomy and subtotal left-sided adrenalectomy were performed. After surgery she developed symptoms of adrenal insufficiency and treatment with HC and fludrocortisone was started. The monitoring tests [VMA in daily urine collection (DUC), catecholamines and metoxycatecholamines] performed 45 days after surgery were in the normal range. Similarly to her mother, Patient 1, replacement with HC and fludrocortisone was not necessary after 13 months, and normal results of a

J Clin Res Pediatr Endocrinol
2026;18(Suppl 1):12-19

Table 1. Laboratory and imaging tests before PHEO surgery

	Patient 1	Patient 2	Patient 3	Patient 4		Patient 5
Age at the moment of PHEO surgery (yrs)	21 (date of left adrenalectomy)	13	5.5	13 yrs 10 mo (date of right adrenalectomy)	14 yrs 3 mo (date of left adrenalectomy)	5
NA in DUC (µg/d)	1749 (↑)	1127 (↑)	606 (N≤44)	121.5 (N=8.3-51)	161.3 (N=8.3-51)	1248.5 (N=8.3-51.1)
A in DUC (µg/d)	Normal	37.7 (↑)	Normal	4.1 (N=1.3-14.5)	5.7 (N=1.3-14.5)	
VMA in DUC	25.2 mg/d (↑)	16.6 mg/d (↑)	14.7 mg/d (↑)	5.2 (2-5.2)	4.5 (2-5.2)	
Normetanephrine in plasma	3000 µg/d (↑)	3465 µg/d (↑)	1890 µg/d (↑)	295 pg/mL (N≤137)	385.5 pg/mL (N≤137)	5259.75 pg/mL (N=31-257)
Metanephrine in plasma				27.17 pg/mL (N<75)	10.75 pg/mL (N<75)	
Abdominal ultrasonography	-	A heterogeneous, hyperechoic mass with a narrow hypoechoic rim measuring 5x3.6x3cm in the right adrenal area		Normal	-	Two solid, abnormal masses between the tail of the pancreas and the left kidney without any connection, size 20x20x25mm and 12x9.5x14.5 mm.
Abdominal CT	At the upper pole of the left kidney there is a nodular mass with a diameter of approximately 4.5 cm. Density measurement shows greater tumor saturation in the marginal layers and less in the central part.	A large tumor measuring 4x4 cm with necrosis in the central part of the right adrenal gland and a small nodule of about 1 cm in the lower part of the left adrenal gland	Quite large, medium shape, with quite uneven averages	-	-	Two focal, solid lesions in the left adrenal gland, with dimensions 22x23x23 mm and 14x14x15 mm with strong contrast enhancement
MRI of the abdomen	-		A nodule (size 25x24x21 mm) emerging from the lower part of the left adrenal gland; in the part of the right adrenal gland a nodule of similar morphology, measuring about 9x7 mm	A lesion in the upper part of the right adrenal gland approx. 11x 9 mm ax x 13 mm cc, and in the lower part, size 5 mm, also within the left adrenal gland, small nodules with features of contrast enhancement, size up to 7 mm	Progression of the previously described nodules in the left adrenal gland (the largest ones 14x12x12 mm and 8x7x7 mm, other small ones up to 5 mm)	
SRS	-			The scintigraphic image shows no signs of changes with increased expression of somatostatin receptors	-	A lesion with a discreetly increased expression of receptors in the projection of the left adrenal gland somatostatins.

Table 1. Continued

	Patient 1	Patient 2	Patient 3	Patient 4		Patient 5
MIBG scintigraphy	-	A large focus of tracer accumulation above the right kidney and a much smaller one on the left side.		In the projection of the right adrenal gland, a focus of abnormal increased tracer accumulation. No increased tracer accumulation in the left adrenal gland	-	
18F-FDG PET/CT	-				Presence of metabolically active changes in the left adrenal gland - of a hyperplastic nature, in other areas there are no signs of hyperplastic changes	A polycyclic lesion in the left adrenal gland with pathological accumulation of [18]-FDG, the possibility of another lesion above

PHEO: pheochromocytoma, NA: noradrenaline, DUC: daily urine collection, VMA: vanillylmandelic acid, MRI: magnetic resonance imaging, SRS: somatostatin receptor scintigraphy, MIBG: ^{131}I/^{123}I-Metaiodobenzylguanidine, 18F-FDG PET/CT: fluorine-18-fluorodeoxyglucose positron emission tomography/computed tomography

synthetic corticotropin test were documented earlier than in the Patient 1. Due to the family history of PHEO [mother (Patient 1) and younger brother (Patient 3)], when the patient was 23 years old, all three family members underwent molecular tests. DNA analysis showed a mutation in the *VHL* gene (*VHLc*.451 A/G) which was present in all three patients. At the age of 19 years she completed endocrinological care at the Children's Memorial Health Institute (CMHI). Observation and investigation up to this point had not revealed any other problems apart from PHEO in terms of vHL-related diseases. At the age of 35 years, abdominal CT showed a cystic-solid focal lesion 11x9 mm in the upper pole of the right kidney which was suspicious for RCC. Wedge resection of the left kidney was performed and histopathology reported RCC G2. During intraoperative ultrasound, a focal lesion in the body of the pancreas was also identified. On endoscopic ultrasonography, two solid, hypoechoic nodules were visualized in the head and body of the pancreas. The histopathology of biopsy material suggested NET, which was confirmed after surgical removal of the lesions. At the age of 37 years, the patient was operated due to a spinal canal tumor and an L3-L4 laminectomy was performed. Once again, histopathology reported HB. She also had laser photocoagulation due to retinal capillary HB. Moreover, at the age of 43 years, an endoscopic ultrasound revealed some new lesions in her pancreas, the biopsy showed NET G1, and these are currently under observation.

Case 3

(Patient 3). A patient with a positive family history (bilateral PHEO in his mother and sister) was under endocrinological care at CMHI from the age of five years. The patient, apart from sweating, had no symptoms. However, at the age of five years, biochemistry reported elevated values of noradrenaline and VMA in DUC (Table 1). On the basis of extended hormonal and imaging (CT and MRI) diagnostics (Table 1), this boy was eligible for surgical treatment. At the age of 5.5 years, a complete resection of the left adrenal gland and removal of a right adrenal nodule was performed. The normalization of catecholamines and metanephrines in the urine was biochemically confirmed nine days after this surgery.

About a year after the surgery, the patient experienced periodic severe abdominal pain, increased sweating, periodic headaches and constipation with concurrent normal BP. On the basis of biochemical and radiological tests (MIBG scintigraphy and MRI) the diagnosis of recurrent PHEO was established. When the patient was 6 years 8 months old, a resection of the right adrenal nodule was performed. Four months later, the boy was readmitted due to abnormal, increased urinary catecholamines, without clinical symptoms typical for PHEO. After performing imaging tests (CT and scintigraphy), the existence of a recurrence in the projection of the right adrenal gland was confirmed and the boy underwent resection of the right adrenal gland. Normalization of catecholamines and metanephrines in DUC was confirmed 10 days after surgery. At the age of 18 years, the patient was diagnosed with severe hyponatremia (lowest sodium concentration was 92 mmol/L), and was diagnosed with syndrome of inappropriate antidiuretic hormone secretion and a hypothalamic HB. The patient underwent neurosurgical operation.

Similar to his sister (Patient 2), during routine screening examinations, HB of the T3 vertebral body was detected

on MRI, as well as a retinal capillary HB in the left eye. A CT scan performed at the age of 25 years showed foci with strong contrast enhancement in the pancreas. SRS showed active pathology in the pancreatic lesion, and MIBG scintigraphy showed increased accumulation of radiotracer in the pelvic projection corresponding to a paraganglioma. The concentration of normetanephrine in the blood plasma was almost three-fold greater than the upper limit of normal. A cytological and histological biopsy of the pancreatic lesion confirmed NET of the pancreas. Total pancreaticoduodenectomy, splenectomy and surgical treatment of a pelvic paraganglioma were performed. The patient is currently treated with insulin due to diabetes and he remains under the care of an adult endocrinology centre.

Case 4

(Patient 4- a daughter of Patient 2). A 5-year-old girl, the daughter of Patient 2, with genetically confirmed vHL (same mutation in the *VHL* ex1 g.A451G, p.S80G) was under endocrine care at CMHI because of the strong family history of vHL. She has been screened for vHL-related diseases since the age of five years. At the age of 13 years, the result of noradrenaline in DUC was abnormal. In the control DUC elevated levels of noradrenaline and plasma normetanephrine were found with the normal plasma concentration of metanephrines (Table 1). Chromogranin A and neuron-specific enolase (NSE) levels were normal., and ambulatory BP monitoring were within normal limits. Ambulatory BP monitoring was normal. After imaging diagnostics (MIBG scintigraphy, SRS, MRI of the abdomen, see Figure 2), laparoscopic removal of focal lesions in the right adrenal gland was planned. Right-sided adrenalectomy was performed after 10 days preparation with a selective alpha-blocker. Postoperative studies performed seven days after surgery showed a decrease in noradrenaline concentration in DUC of 63 µg/24 h (NR 8.3-51), and slightly elevated normetanephrine concentration of 161.07 pg/mL (NR<137 pg/mL). The follow-up studies performed three months after surgery revealed an increase of noradrenaline in 24-hour urine collection of 161.3 µg/24 h (NR 8.3-51.1) and normetanephrine in blood serum of 385.5 pg/mL (NR<137 pg/mL). Imaging with 2-deoxy-2-[fluorine-18]fluoro-D-glucose PET showed the presence of metabolically active hyperplastic changes in the left adrenal gland. Doxazosin treatment was started. The patient underwent laparoscopic partial adrenalectomy of the left side, which was performed successfully. Follow-up studies performed 12 days, and at four and 12 months after the surgery revealed normal results of catecholamines in DUC, plasma metanephrines, chromogranin A and NSE. The patient remains under constant endocrinological care.

Case 5

(Patient 5- a son of Patient 2). A 5-year-old boy, known to be a carrier of the *VHL* mutation (g.A451G, p.S80G) was under endocrine from the age of 4 years. Genetic testing was performed due to vHL in his mother, uncle and sister. His laboratory tests were normal until the age of five years, when the results of catecholamines in DUC during routine follow-up were significantly elevated with noradrenaline in DUC of 966.0 and 1248.5 µg/24 h (NR 8.3-51.1, plasma normetanephrine 5259.75 pg/mL (NR 31-257 pg/mL) (Table 1). Chromogranin A and NSE results were also raised. Abdominal CT showed two focal, solid lesions in the left adrenal gland, with dimensions of 22x23x23 mm and 14x14x15 mm with strong contrast enhancement. SRS revealed a lesion with a discreetly increased expression of receptors in the projection of the left adrenal gland. PET examination showed a multilobulated lesion in the left adrenal gland with pathological accumulation of [18]-fluoro-D-glucose and the possibility of another lesion above (Figure 3). BP values were above the 95th percentile. There were no significant signs of organ damage caused by hypertension. Doxazosin was added to the treatment in a gradually increasing dose. On Holter electrocardiogram, sinus tachycardia was diagnosed and propranolol at a dose of 3x5 mg/day was started. A partial left-sided adrenalectomy was performed laparoscopically. Follow-up studies performed at three weeks, three months and eight months after the surgery revealed normal results for catecholamines in DUC, plasma metanephrines, chromogranin A and NSE. The patient remains under constant endocrinological care.

In all five patients postoperative histopathological examination of the adrenal glands revealed a tumor corresponding to an adrenal paraganglioma (PHEO).

Discussion

A clinical diagnosis of vHL can be established in one of two ways. These are: (1) in a patient with a family history of vHL and the presence of a CNS or retinal HB, PHEO, or RCC; or (2) in a simplex case (a patient with no family history) with two HB or two visceral tumours or one HB and one visceral tumor (4). The gold standard for vHL diagnosis is identification of a pathogenic variant in the *VHL* gene, which confirms the clinical diagnosis (5).

The nomenclature and classifications of paragangliomas has changed. In the old classification there were: PHEO and paraganglioma: head and neck or sympathetic. In the new classification there are: adrenal paraganglioma (PHEO), sympathetic abdominal paraganglioma, sympathetic head and neck paraganglioma and parasympathetic paraganglioma (6).

The presentation of many lesions associated with vHL often occurs in the third and fourth decades of life, but the age range of initial manifestations is wide and children are particularly vulnerable, being at risk of developing HB and PHEO that can remain clinically occult until symptoms become severe (7,8). The lifetime risk of developing PHEO in patients with vHL is 10-25% (9). Data regarding vHL manifestation in

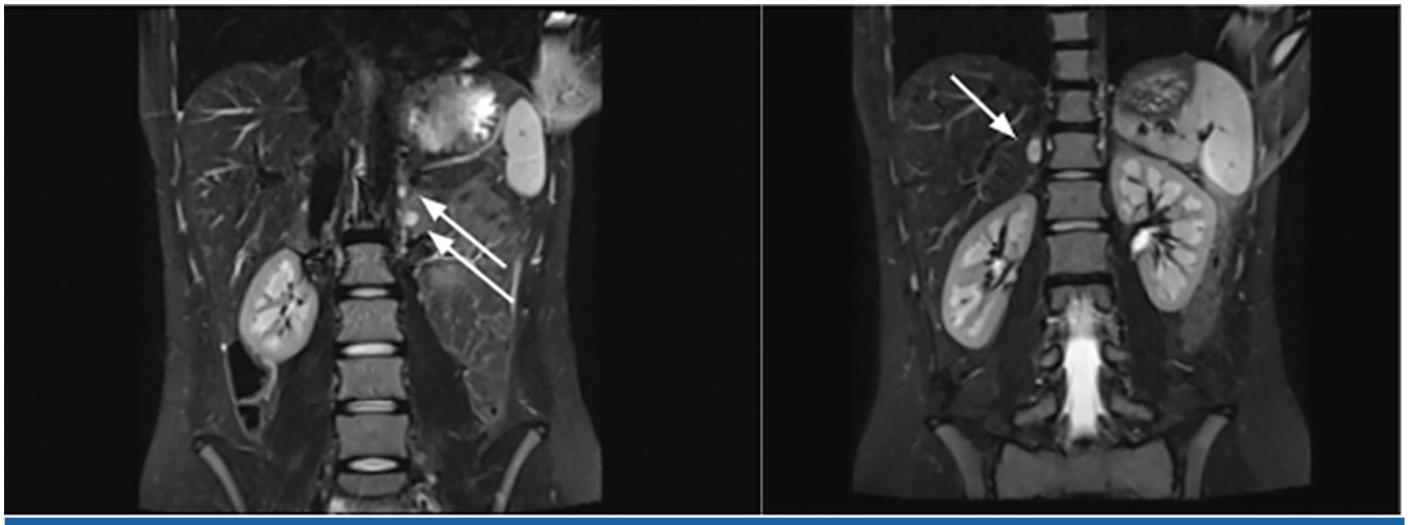

Figure 2. MRI of the abdomen, Patient 4- a lesion in the upper part of the right adrenal gland (arrow) approx. 11x 9 mm ax x 13 mm cc, and in the lower part, size 5 mm, also within the left adrenal gland, small nodules with features of contrast enhancement, size up to 7 mm
MRI: magnetic resonance imaging

children and adolescents, including age at first manifestation, manifestation frequencies, and types, are limited. Launbjerg et al. (10) evaluated 99 patients who had started surveillance before 18 years of age, including 37 Danish vHL patients and 62 international patients described in 15 articles). Seventy percent of patients developed manifestations before 18 years, with a median (range) age at first manifestation of 12 (6-17) years. The majority of manifestations were asymptomatic and only detected because of vHL surveillance. Thirty per cent (30 of 99) had developed more than one manifestation type, with the most frequent being retinal (34%) and CNS (30%) HBs. Eighteen percent of patients developed PHEO before the age of 18 years. In the family described in the presented article all patients were diagnosed with PHEO before the age of 18 years and this diagnosis was the first related to vHL syndrome in all patients. Patient 3 had hypothalamic HB at the age of 18 years, whereas all other vHL-related disorders, excluding PHEO, were recognised in three other patients (Patient 1, Patient 2 and Patient 3) in adulthood. The most common manifestation, apart from PHEO, was NET of the pancreas (Patient 1, Patient 2 and Patient 3), which was diagnosed in these patients at the ages of 61, 43 and 25 years, respectively.

The youngest reported patient with vHL was 2.75 years old at diagnosis of PHEO, and the mean age of PHEO diagnosis in vHL patients is 27 years (9).

In the presented family the youngest patients (Patient 3 and Patient 5) were five years old, and the oldest patient (Patient 1) was 18 years old at the time of PHEO diagnosis. Fugaru et al. (11) reported rapidly progressing PHEO in siblings, and diagnosis was made at the ages of 7 and 11 years, respectively. In the cited article both brothers presented with large PHEOs, despite routine screening.

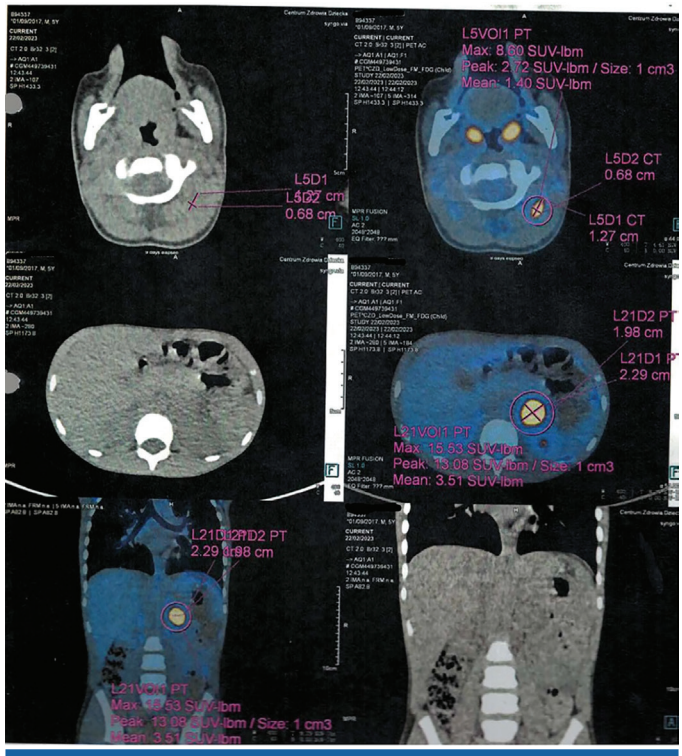

Figure 3. PET, Patient 5. A polycyclic lesion in the left adrenal gland with dimensions 22x20 mm with pathological accumulation of [18]-FDG (SUV_{max} FDG=13.4), above: the possibility of another lesion of dimensions 13x11 mm (SUV_{max} FDG=13.4)
PET: positron emission tomography, [18]-FDG: fluorine-18 fluorodeoxyglucose, SUV_{max}: maximum standardized uptake value

The authors concluded that a more frequent surveillance protocol may be appropriate for vHL families with a high risk of PHEO, which is typical for vHL patients with missense mutations.

In the analysis by Libutti et al. (12) of 389 patients with vHL the mean age of diagnosis of pancreatic NET was 35 years and the youngest patient was 16 years old at the time of diagnosis. In the family presented in this article, the youngest patients was 25 years old when NET of pancreas was diagnosed.

vHL results from pathogenic variants in the *VHL* gene (5). About 80% of patients with vHL have an affected parent, and about 20% result from a *de novo* pathogenic variant (5). The mutations were inherited from an affected parent in the patients presented (but there is no data about the parents of Patient 1).

Clinically, vHL is subdivided into five subtypes based on tumor spectrum, as well as mutation type (7). Clinical manifestation of type I are: retinal angioma, CNS HB, RCC, pancreatic NETs. Type IB is characterized by the occurrence of retinal angioma, CNS HB, and pancreatic NETs while the risk for PHEO and RCC is low.

In type IIA PHEO, retinal angioma and CNS HB occur, while the risk for RCC is low.

In type IIB and IIC the risk of PHEO is high. Moreover, the occurrence of retinal angioma, CNS HB, pancreatic cysts, pancreatic NETs, and RCC is characteristic for type IIB and the occurrence of CNS HB is characteristic for type IIC although pancreatic NETs are rare in type IIC (7).

The type of variant in the *VHL* gene accounts for differences in PHEO risk, with a strong genotype-phenotype correlation (13). Truncating variants or exon deletions in the *VHL* gene are reported among individuals with vHL type I and are associated with a relatively low risk of PHEO (13). In contrast, vHL type II is associated with missense variants that generally do not affect the protein structure and are associated with a relatively higher risk of PHEO (13). Interestingly, missense mutations that cause amino-acid changes on the surface of the *VHL* gene product (pVHL) appear to have a higher risk for PHEO than missense mutations occurring deep within the protein. Surface missense mutations also appear to have a higher risk for PHEO than deletions, non-sense and frameshift mutations (14). Germline mutations that lead to a truncated pVHL are associated with a 40% higher risk of developing RCC compared to patients with germline missense mutations (15). An earlier onset of CNS HB in patients with a truncating variants has been described, while missense variants predispose for an earlier onset of parasympathetic paraganglioma (PPGL) (16).

The presented family had a missense variant in the *VHL* gene (exon 1 g.A451G, p.S80G) and in every patient PHEO occurred before adulthood. In four patients (Patients 1, 2, 3 and 4) PHEO was bilateral, the last patient (Patient 5) is the youngest in this family (6-years-old at the time of the last follow-up) and he is at high risk of developing PHEO in the contralateral adrenal gland.

Screening strategies for PHEO and other tumours in patients with a *VHL* mutations include an annual clinical examination and an annual determination of urinary or plasma methoxycatecholamines. However, there are different recommendations for pediatric screening procedures, including the age at which screening should begin, the conditions under which imaging is performed, and the frequency of these examinations. Table S1 summarizes recommendations for screening patients with vHL from the VHL Alliance consensus panel, consisting of clinicians covering all fields of expertise involved in the management of vHL (17).

Given that patients with type II vHL have an increased risk of PHEO, biochemical screening with plasma-free metanephrines in children harboring *VHL* missense pathogenic variant has been proposed to start immediately after genetic diagnosis, rather than after 5 years old (18). The presented patients' history supports this recommendation.

Conclusion

Performing screening laboratory tests and imaging tests in patients with genetically confirmed vHL may help avoid the occurrence of disease symptoms and enable the performance of elective rather than emergency surgery. Due to the risk of coexisting pathologies and the complexity of the disease, patients with vHL require long-term care including monitoring of small asymptomatic lesions for evidence of progression.

Ethics

Informed Consent: Informed consent for publication was obtained from the patient's parents.

Footnotes

Authorship Contributions

Surgical and Medical Practices: Katarzyna Pasternak-Pietrzak, Agata Kozłowska, Elżbieta Moszczyńska, Concept: Katarzyna Pasternak-Pietrzak, Agata Kozłowska, Elżbieta Moszczyńska, Design: Katarzyna Pasternak-Pietrzak, Agata Kozłowska, Elżbieta Moszczyńska, Data Collection or Processing: Katarzyna Pasternak-Pietrzak, Agata Kozłowska, Elżbieta Moszczyńska, Analysis or Interpretation: Katarzyna Pasternak-Pietrzak, Agata Kozłowska, Elżbieta Moszczyńska, Literature Search: Katarzyna Pasternak-Pietrzak, Writing: Katarzyna Pasternak-Pietrzak, Agata Kozłowska, Elżbieta Moszczyńska.

Financial Disclosure: The authors declared that this study received no financial support.

Supplementary Table: https://d2v96fxpocvxx.cloudfront.net/cf9d60d6-523c-458a-a2e6-78728d3ffbb0/content-images/a4e359fe-79fe-42d6-b84a-1a8dacc90252.pdf

References

1. Chittiboina P, Lonser RR. Von Hippel-Lindau disease. Handb Clin Neurol. 2015;132:139-156.
2. Binderup ML, Galanakis M, Budtz-Jørgensen E, Kosteljanetz M, Luise Bisgaard M. Prevalence, birth incidence, and penetrance of von Hippel-Lindau disease (vHL) in Denmark. Eur J Hum Genet. 2017;25:301-307. Epub 2016 Dec 14
3. Feletti A, Anglani M, Scarpa B, Schiavi F, Boaretto F, Zovato S, Taschin E, Gardi M, Zanoletti E, Piermarocchi S, Murgia A, Pavesi G, Opocher G. Von Hippel-Lindau disease: an evaluation of natural history and functional disability. Neuro Oncol. 2016;18:1011-1020. Epub 2016 Jan 12
4. Lonser RR, Glenn GM, Walther M, Chew EY, Libutti SK, Linehan WM, Oldfield EH. von Hippel-Lindau disease. Lancet. 2003;361:2059-2067.
5. Nielsen SM, Rhodes L, Blanco I, Chung WK, Eng C, Maher ER, Richard S, Giles RH. Von Hippel-Lindau disease: genetics and role of genetic counseling in a multiple neoplasia syndrome. J Clin Oncol. 2016;34:2172-2181. Epub 2016 Apr 25
6. Mete O, Asa SL, Gill AJ, Kimura N, de Krijger RR, Tischler A. Overview of the 2022 WHO Classification of paragangliomas and pheochromocytomas. Endocr Pathol. 2022;33:90-114. Epub 2022 Mar 13
7. Rednam SP, Erez A, Druker H, Janeway KA, Kamihara J, Kohlmann WK, Nathanson KL, States LJ, Tomlinson GE, Villani A, Voss SD, Schiffman JD, Wasserman JD. Von Hippel-Lindau and hereditary pheochromocytoma/paraganglioma syndromes: clinical features, genetics, and surveillance recommendations in childhood. Clin Cancer Res. 2017;23:e68-e75.
8. Bausch B, Wellner U, Peyre M, Boedeker CC, Hes FJ, Anglani M, de Campos JM, Kanno H, Maher ER, Krauss T, Sansó G, Barontini M, Letizia C, Hader C, Schiavi F, Zanoletti E, Suárez C, Offergeld C, Malinoc A, Zschiedrich S, Glasker S, Bobin S, Sterkers O, Ba Huy PT, Giraud S, Links T, Eng C, Opocher G, Richard S, Neumann HP; International Endolymphatic Sac Tumor (ELST) Consortium. Characterization of endolymphatic sac tumors and von Hippel-Lindau disease in the international endolymphatic sac tumor registry. Head Neck. 2016;38 Suppl 1:E673-E679. Epub 2015 Jul 14
9. Sovinz P, Urban C, Uhrig S, Stepan V, Lackner H, Schwinger W, Benesch M, Moser A, Spuller E, Speicher MR. Pheochromocytoma in a 2.75-year-old-girl with a germline von Hippel-Lindau mutation Q164R. Am J Med Genet A. 2010;152A:1752-1755.
10. Launbjerg K, Bache I, Galanakis M, Bisgaard ML, Binderup MLM. von Hippel-Lindau development in children and adolescents. Am J Med Genet A. 2017;173:2381-2394. Epub 2017 Jun 26
11. Fugaru I, Goudie C, Capolicchio JP. Von Hippel-Lindau disease and rapidly progressing pheochromocytomas in siblings. Fam Cancer. 2022;21:229-233. Epub 2021 Apr 20
12. Libutti SK, Choyke PL, Alexander HR, Glenn G, Bartlett DL, Zbar B, Lubensky I, McKee SA, Maher ER, Linehan WM, Walther MM. Clinical and genetic analysis of patients with pancreatic neuroendocrine tumors associated with von Hippel-Lindau disease. Surgery. 2000;128:1022-1027;discussion 1027-1028.
13. Nordstrom-O'Brien M, van der Luijt RB, van Rooijen E, van den Ouweland AM, Majoor-Krakauer DF, Lolkema MP, van Brussel A, Voest EE, Giles RH. Genetic analysis of von Hippel-Lindau disease. Hum Mutat. 2010;31:521-537.
14. Ong KR, Woodward ER, Killick P, Lim C, Macdonald F, Maher ER. Genotype-phenotype correlations in von Hippel-Lindau disease. Hum Mutat. 2007;28:143-149.
15. Gallou C, Chauveau D, Richard S, Joly D, Giraud S, Olschwang S, Martin N, Saquet C, Chrétien Y, Méjean A, Correas JM, Benoît G, Colombeau P, Grünfeld JP, Junien C, Béroud C. Genotype-phenotype correlation in von Hippel-Lindau families with renal lesions. Hum Mutat. 2004;24:215-224.
16. Salama Y, Albanyan S, Szybowska M, Bullivant G, Gallinger B, Giles RH, Asa S, Badduke C, Chiorean A, Druker H, Ezzat S, Hannah-Shmouni F, Hernandez KG, Inglese C, Jani P, Kaur Y, Krema H, Krimus L, Laperriere N, Lichner Z, Mete O, Sit M, Zadeh G, Jewett MAS, Malkin D, Stockley T, Wasserman JD, Xu W, Schachter NF, Kim RH. Comprehensive characterization of a Canadian cohort of von Hippel-Lindau disease patients. Clin Genet. 2019;96:461-467. Epub 2019 Aug 6
17. The VHL Alliance -- https://www.vhl.org/ (Accessed on June 29, 2020).
18. Fagundes GFC, Petenuci J, Lourenco DM Jr, Trarbach EB, Pereira MAA, Correa D'Eur JE, Hoff AO, Lerario AM, Zerbini MCN, Siqueira S, Yamauchi F, Srougi V, Tanno FY, Chambo JL, Latronico AC, Mendonca BB, Fragoso MCBV, Almeida MQ. New insights into pheochromocytoma surveillance of young patients with *VHL* missense mutations. J Endocr Soc. 2019;3:1682-1692.

CASE REPORT

JCRPE Journal of Clinical Research in Pediatric Endocrinology

DOI: 10.4274/jcrpe.galenos.2024.2024-5-4
J Clin Res Pediatr Endocrinol 2026;18(Suppl 1):20-24

A Rare Cause of Proportional Short Stature and Puberty Precocity: Floating-Harbor Syndrome

Duygu Çetinkaya[1], Gönül Büyükyılmaz[2], Esra Kılıç[1]

[1]University of Health Sciences Türkiye, Ankara Bilkent City Hospital, Clinic of Pediatric Genetics, Ankara, Türkiye
[2]University of Health Sciences Türkiye, Ankara Bilkent City Hospital, Clinic of Pediatric Endocrinology, Ankara, Türkiye

Cite this article as: Çetinkaya D, Büyükyılmaz G, Kılıç E. A rare cause of proportional short stature and puberty precocity: floating-harbor syndrome. J Clin Res Pediatr Endocrinol. 2026;18(Suppl 1):20-24

What is already known on this topic?

Floating-Harbor syndrome is a rare autosomal dominant disorder caused by heterozygous SNF2-associated CREB-binding protein activator protein gene mutations. It is characterized by distinctive craniofacial features, proportionate short stature, delayed bone age, and expressive language delay. However, phenotypic variability may complicate diagnosis, requiring careful clinical and molecular evaluation.

What this study adds?

This study presents a clinically and molecularly confirmed case of Floating-Harbor syndrome, highlighting its characteristic phenotype. It underscores that in patients with short stature and delayed bone age, careful assessment of dysmorphic features is crucial for differential diagnosis, contributing to improved recognition and expanding the clinical spectrum of this rare disorder.

ABSTRACT

Floating-Harbor syndrome is a sporadic, autosomal dominantly-inherited, malformation syndrome characterized by typical craniofacial findings, proportional short stature, significantly delayed bone age, delayed expressive language, delayed speech, and normal head circumference. It is caused by heterozygous mutations in the *SNF2-associated CBP activator protein* gene (*SRCAP*) located on chromosome 16. Here, we report a 9.3 years old male patient who presented to the pediatric genetics outpatient clinic with retardation in early developmental stages, dysmorphic facial features, and short stature. A triangular face, short filtrum, posteriorly rotated ear, deep-set eyes, bulbous nose, prominent columella, and low hairline are unique facial features in the syndrome. He also has short stature, significant retardation in bone age, and retardation in expressive language, all suggesting Floating-Harbor syndrome. The diagnosis was confirmed through molecular testing which revealed a

Corresponding Author: Duygu Çetinkaya, University of Health Sciences Türkiye, Ankara Bilkent City Hospital, Clinic of Pediatric Genetics, Ankara, Türkiye
E-mail: drduygukose@gmail.com **ORCID:** orcid.org/0009-0003-0499-7207
Conflict of interest: None declared
Received: 22.05.2024 **Accepted:** 05.09.2024 **Epub:** 23.09.2024 **Publication Date:** 02.06.2026

©Copyright 2026 by Turkish Society for Pediatric Endocrinology and Diabetes / The Journal of Clinical Research in Pediatric Endocrinology published by Galenos Publishing House.
Licensed under a Creative Commons Attribution-NonCommercial-NoDerivatives 4.0 (CC BY-NC-ND) International License.

heterozygous c.7330C>T p.(Arg2444Ter) pathogenic variant in exon 34, of the *SRCAP* gene. Floating-Harbor syndrome should be remembered in the differential diagnosis of patients evaluated for short stature and learning disability with its unique facial features. By reporting a new case of Floating-Harbor syndrome our aim was to expand the clinical and molecular spectrum in this rare syndrome and increase diagnostic awareness for pediatric endocrinology practitioners.

Keywords: Floating-Harbor syndrome, *SRCAP* gene, short stature

Introduction

Floating-Harbor syndrome (FHS) is a rare, hereditary syndrome, characterized by a head circumference in the normal range, low birth weight, proportional short stature, delayed speech, retarded expressive language, and significant retardation in bone age with typical facial features. FHS was first reported in 1973-1974 (1,2). The unique facial features of patients may become less distinctive with age (3). In addition, microcephaly, trigonocephaly, dental problems, abnormal EEG, late-onset hypertension, cone-shaped epiphysis, and Perthes disease may accompany the syndrome (4). FHS occurs due to heterozygous mutations in the *SNF2-associated CBP activator protein* gene (*SRCAP*). *SRCAP* is a 43.2 Kb gene consisting of 34 exons in the 16p11.2 region. It encodes the SNF2-associated CREBBP activator protein. This protein has ATPase activity. It is responsible for cell growth and division by increasing CREB-binding protein (CBP) transcription (5). Here, a boy with FHS who presented to the pediatric genetics outpatient clinic with speech disorder and dysmorphic features and was diagnosed through clinical findings will be reported.

Patient and Methods

A 9-year and 4-month-old male patient was referred to the pediatric genetics outpatient clinic due to delays in early developmental milestones, dysmorphic facial features, and short stature. He was born via Cesarean section at 40 weeks of gestation with a birth weight of 3000 grams [-1.2 standard deviation score (SDS)]. He is the fifth child of healthy, non-consanguineous parents. There is no history of special infant care. On initial physical examination, his weight was 23 kg (-1.6 SDS), height was 118 cm (-2.66 SDS), body mass index (BMI) was 0.01 SDS, arm span was 111 cm, and head circumference was 52 cm (-0.81 SDS). The pubertal examination was normal, with Tanner stage 1, but bone age was approximately 4 years as assessed by X-ray (Figure 1d). The dysmorphic evaluation revealed a triangular face, deep-set eyes, prominent nasal root, low-set ears, bulbous nose, low-hanging columella, and short philtrum (Figure 1a-c). Developmentally, the patient began walking at 1.5 years of age and talking at three years of age. He exhibited significant expressive language delays and shy behavior. Initial hematologic, biochemical, and metabolic parameters were within normal limits. At 10 years and 3 months of age, the patient was evaluated by the pediatric endocrinology department due to short stature and early puberty. Physical examination revealed a weight of 28.8 kg (-0.86 SDS), height of 126.8 cm (-1.9 SDS), BMI of 0.66 SDS, and arm span of 124 cm. Annual growth was 8.8 cm, with an increase in height velocity. Bone age was 6 years (Figure 1e), showing a 2-year increase within 1 year. Testicular volume was 8-10 cc, appropriate for his age. Endocrinological evaluation showed follicle-stimulating hormone (6) level of 2.2 U/L (reference range: 0.3-10.1), luteinizing hormone level of 2.2 U/L (reference range: <6), and testosterone level of 1.02 µg/L. Insulin-like growth factor-1

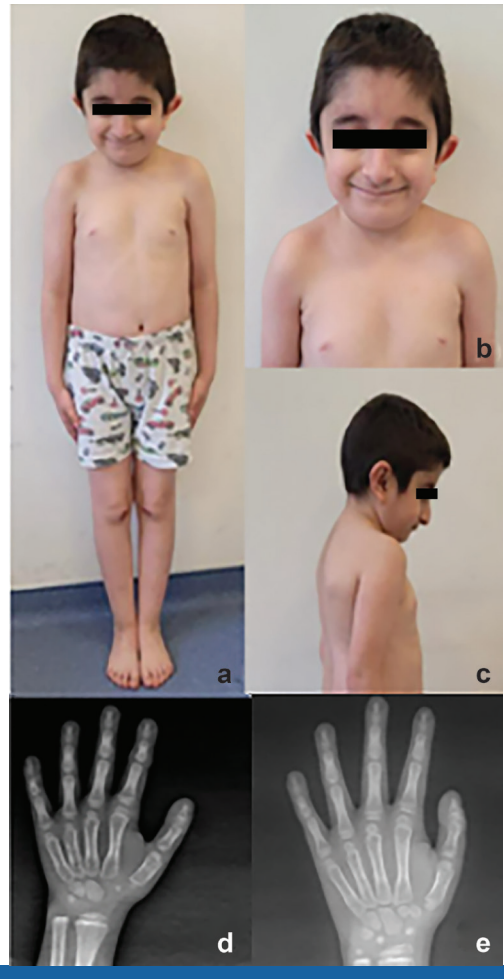

Figure 1. a) Nine years 4 months old male patient. **b** and **c)** Dysmorphologic evaluation triangular face, deep-set eyes, low-set ear, bulbous nose, low hanging columella, short filtrum. d) Bone age consistent with 3 years 6 months. e) Bone age consistent with 6 years

(IGF-1) level was 157 µg/L (reference range: 63-271), and IGF binding protein 3 level was 7.6 (reference range: 2.4-8.4), both within normal ranges. Pituitary and brain magnetic resonance imaging were normal, and follow-up was conducted for early and rapid puberty. Echocardiography and abdominal ultrasound screening showed no major organ abnormalities. Hearing test results were normal, and the ophthalmology department followed the patient for esotropia with corrective glasses. Psychometric evaluation using the Wechsler Intelligence Scale for Children identified mild to moderate intellectual disability. The patient is receiving special education for cognitive and speech delays.

Karyotype analysis revealed a normal 46, XY result. Microarray analysis showed no pathogenic copy number variations [Illumina Infinium CytoSNP 850K "Infinium CytoSNP-850K BeadChip (Illumina, Inc., San Diego, CA, USA)]. Fragile X gene DNA analysis with triplet primer polymerase chain reaction identified 56 CGG repeats, placing the patient in the Fragile X premutation range. Due to the clinical presentation and dysmorphic features suggestive of FHS, sequencing of the *SRCAP* gene was performed. Next Generation Sequencing (NGS) of the *SRCAP* gene revealed a heterozygous c.7330C>T p.(Arg2444Ter) variant in exon 34, which is predicted to cause premature protein termination. This variant is classified as pathogenic according to ACMG-AMP criteria (7). Verification with Sanger sequencing confirmed the presence of this variant in the patient in the heterozygous state. This variant was not detected in the Sanger sequencing of the parents, thus it is interpreted as a disease-causing, *de novo* mutation.

Discussion

FHS is a very rare malformation syndrome with autosomal dominant inheritance characterized by short stature, typical facial features, and significant delay in bone age (1). A total of 100 cases of this extremely rare syndrome have been reported (8). It occurs because of mutations in the *SRCAP* gene located on chromosome 16. The *SRCAP* gene encodes the SNF2-related CREB binding protein. This protein has a role in the activation of the *CREBBP* (CREB binding protein) gene, which is involved in the exchange of histone dimers in the nucleosome and provides transcriptional regulation by remodeling chromatin. CREB binding protein, the protein encoded by the *CREBBP* gene, is involved in cell proliferation and normal growth (9,10). The mutations reported so far are especially clustered in the 34th exon and the variant in our patient was also located in the 34th exon (11). There is no known genotype-phenotype relationship in the reported cases. In the series of 13 cases reported by Hood et al. (12), six patients had the same variant that was present in our patient. Syndrome-specific facial features are the most important differential diagnostic step in FHS (13). Our patient exhibited typical facial features of the syndrome with a triangular face, prominent nasal root, inferiorly located columella, thin upper lip vermillion, and deeply set eyes. Low birth weight has been reported in FHS but it is not characteristic of this syndrome. Our patient was born at 40 weeks with a birth weight of 3000 g (-1.2 SDS). The patient had a normal birth weight based on anthropometric measurements at birth. Thirteen out of 49 (26.5%) patients with FHS were reported to have a birth weight below -2 SDS (11). Short stature is the cardinal sign of FHS, but may vary somewhat in patients with FHS. The exact mechanism by which *SRCAP* mutations cause short stature has not been fully elucidated. It is thought that anomalies that cause irregularity in chondrocyte proliferation and maturation may affect the growth phenotype of patients with FHS by causing a delay in long-bone development (14). It has also been reported that short stature may be associated with growth hormone (GH) deficiency, GH neurosecretory dysfunction, and IGF-1 signaling defects (15). In a series of 52 patients reported from two previous studies, the maximum height in girls was 20th percentile and the majority of the cases were located between -2 and -4 SDS. In boys, the maximum height was 25th percentile and two adults were -4 SDS for height (11). In another study, the heights of 13 patients ranged between -4.3 SDS and -0.6 SDS (12). When the growth parameters of previously reported patients were analyzed, it was reported that head circumference for height was within the normal range (11). Similarly, the presented patient's height was -2.2 SDS and head circumference was 0.81 SDS in the normal range. GH may be one of the treatment alternatives in FHS (16,17). In a study evaluating 22 cases of FHS who received GH treatment, most showed accelerated growth and improved height SDS (15). However, as the IGF-1 level of our patient fell within the normal range for his age, GH treatment was not considered. He is being monitored for potential GH therapy based on an ongoing assessment of his growth rate.

Significant delay in bone age, which is one of the essential features of FHS, was reported in all patients in the series of 13 cases (14). Although there is a significant delay in bone age (≥2 SD below the mean), normalization in bone age is expected between the ages of six and 12 years. The chronological age of our patient was 9 years and 4 months but his bone age was only 3 years and 6 months (12). Interestingly, in the follow-up, a 3-year improvement in bone age was detected in 1 year. This rapid change may also be due to our patient's fast puberty. Puberty precocity is among the features reported in patients with FHS and, again, the underlying mechanism is still unknown (16). Cases have been reported in which GnRH analog treatment was started due to early puberty, and bone maturation was successfully suppressed (18). In the case described by Stagi et al. (18), it was reported that adult height of -1.2 SDS was achieved with both GH and GnRHa treatments. In the presented case, an early and fast puberty was detected and GnRHa treatment will be planned according to the follow-up.

Expressive language delay is another major finding of the syndrome and our patient was receiving speech therapy due to significant delay in expressive language (13). In one study, the frequency of attention deficit hyperactivity disorder was reported to be 28% and in another study, the frequency of behavioral problems was reported to be 60%. In keeping with this, the presented patient was being treated for attention deficit hyperactivity disorder but had no behavioral problems (9,11,12,16). In our patient, premutation was detected with 54 repeats in the CGG 3-repeat analysis for Fragile X syndrome, but we diagnosed FHS with further molecular analysis because of dysmorphic facial finding and short stature. The patient being a Fragile X premutation carrier could potentially affect their behavioral phenotype and intellectual disability profile. In a study of 52 cases, although at least one major organ anomaly was found in 33 of the patients diagnosed with FHS, no specific anomaly was reported to be associated with it, and our patient had no major organ anomaly (11).

FHS must be distinguished from other genetic conditions with short stature. Rubinstein-Taybi syndrome was ruled out due to the absence of its characteristic features and organ anomalies. Silver-Russell syndrome was unlikely because the patient's head circumference and birth weight were normal. 3M syndrome was excluded as the patient did not have the typical skeletal features and had developmental delays. SHORT syndrome was not considered due to the lack of associated symptoms, such as hearing loss and joint laxity. Aarskog syndrome was also excluded because the patient's facial features did not match those of the syndrome.

Conclusion

In conclusion, FHS should be considered in the differential diagnosis of patients being investigated for short stature and learning disability, especially when exhibiting characteristic facial features. Although the presented patient was found to be a premutation carrier on Fragile X analysis carried out for a learning disability, he was diagnosed with FHS with a molecular examination performed because of his characteristic facial findings. Herein, we report a new case of FHS who was diagnosed after evaluation for short stature, precocious puberty, and dysmorphic facial features. We hope to increase the awareness of rare genetic diseases among pediatric endocrinology practitioners who may encounter undiagnosed FHS because of the short stature and or markedly delayed bone age.

Ethics

Informed Consent: Written informed consent was obtained from the family of the patient for publication of this report.

Acknowledgements

We are grateful to the patient and their family for their participation and collaboration in this report. No specific funding from any agency in the public, commercial, or not-for-profit sectors was received for his report.

Footnotes

Authorship Contributions

Surgical and Medical Practices: Duygu Çetinkaya, Gönül Büyükyılmaz, Esra Kılıç, Concept: Duygu Çetinkaya, Esra Kılıç, Design: Duygu Çetinkaya, Gönül Büyükyılmaz, Esra Kılıç, Data Collection and Processing: Duygu Çetinkaya, Esra Kılıç, Analysis or Interpretation: Duygu Çetinkaya, Literature Search: Duygu Çetinkaya, Gönül Büyükyılmaz, Writing: Duygu Çetinkaya, Gönül Büyükyılmaz, Esra Kılıç.

Financial Disclosure: The authors declared that this study received no financial support.

References

1. Pelletier G, Feingold M. Case report 1. In: Bergsma D, editor. Syndrome Identification. White Plains: National Foundation-March of Dimes; 1973. p. 8-9.
2. Leisti HDJ, Rimoin DL. Case report. In: Bergsma D, ed. Syndrome Identification. New York: National Foundation–March of Dimes; 1974. vol. 10, p. 305
3. White SM, Morgan A, Da Costa A, Lacombe D, Knight SJ, Houlston R, Whiteford ML, Newbury-Ecob RA, Hurst JA. The phenotype of Floating-Harbor syndrome in 10 patients. Am J Med Genet A. 2010;152:821-829.
4. Smith DW. Recognizable patterns of human malformation. Genetic, embryologic and clinical aspects. Major Probl Clin Pediatr. 1982;7:1-653.
5. Johnston H, Kneer J, Chackalaparampil I, Yaciuk P, Chrivia J. Identification of a novel SNF2/SWI2 protein family member, SRCAP, which interacts with CREB-binding protein. J Biol Chem. 1999;274:16370-16376.
6. Mohammadi P, Salehi Siavashani E, Mohammadi MF, Bahramy A, Almadani N, Garshasbi M. Whole-exome sequencing identified first homozygous frameshift variant in the COLEC10 gene in an Iranian patient causing 3MC syndrome type 3. Mol Genet Genomic Med. 2021;9:e1834. Epub 2021 Oct 12
7. Richards S, Aziz N, Bale S, Bick D, Das S, Gastier-Foster J, Grody WW, Hegde M, Lyon E, Spector E, Voelkerding K, Rehm HL; ACMG Laboratory Quality Assurance Committee. Standards and guidelines for the interpretation of sequence variants: a joint consensus recommendation of the American College of Medical Genetics and Genomics and the Association for Molecular Pathology. Genet Med. 2015;17:405-424. Epub 2015 Mar 5
8. Alanis S, Blair MP, Kaufman LM, Bhat G, Shapiro MJ. Floating-Harbor syndrome with chorioretinal colobomas. Ophthalmic Genet. 2024;45:207-209. Epub 2023 Sep 18
9. Seifert W, Meinecke P, Krüger G, Rossier E, Heinritz W, Wüsthof A, Horn D. Expanded spectrum of exon 33 and 34 mutations in SRCAP and follow-up in patients with Floating-Harbor syndrome. BMC Med Genet. 2014;15:127.
10. Wong MM, Cox LK, Chrivia JC. The chromatin remodeling protein, SRCAP, is critical for deposition of the histone variant H2A.Z at promoters. J Biol Chem. 2007;282:26132-26139. Epub 2007 Jul 8
11. Nikkel SM, Dauber A, de Munnik S, Connolly M, Hood RL, Caluseriu O, Hurst J, Kini U, Nowaczyk MJ, Afenjar A, Albrecht B, Allanson JE, Balestri P,

Ben-Omran T, Brancati F, Cordeiro I, da Cunha BS, Delaney LA, Destrée A, Fitzpatrick D, Forzano F, Ghali N, Gillies G, Harwood K, Hendriks YM, Héron D, Hoischen A, Honey EM, Hoefsloot LH, Ibrahim J, Jacob CM, Kant SG, Kim CA, Kirk EP, Knoers NV, Lacombe D, Lee C, Lo IF, Lucas LS, Mari F, Mericq V, Moilanen JS, Møller ST, Moortgat S, Pilz DT, Pope K, Price S, Renieri A, Sá J, Schoots J, Silveira EL, Simon ME, Slavotinek A, Temple IK, van der Burgt I, de Vries BB, Weisfeld-Adams JD, Whiteford ML, Wierczorek D, Wit JM, Yee CF, Beaulieu CL; FORGE Canada Consortium; White SM, Bulman DE, Bongers E, Brunner H, Feingold M, Boycott KM. The phenotype of Floating-Harbor syndrome: clinical characterization of 52 individuals with mutations in exon 34 of SRCAP. Orphanet J Rare Dis. 2013;8:63.

12. Hood RL, Lines MA, Nikkel SM, Schwartzentruber J, Beaulieu C, Nowaczyk MJ, Allanson J, Kim CA, Wieczorek D, Moilanen JS, Lacombe D, Gillessen-Kaesbach G, Whiteford ML, Quaio CR, Gomy I, Bertola DR, Albrecht B, Platzer K, McGillivray G, Zou R, McLeod DR, Chudley AE, Chodirker BN, Marcadier J; FORGE Canada Consortium; Majewski J, Bulman DE, White SM, Boycott KM. Mutations in SRCAP, encoding SNF2-related CREBBP activator protein, cause Floating-Harbor syndrome. Am J Hum Genet. 2012;90:308-313. Epub 2012 Jan 19

13. Robinson PL, Shohat M, Winter RM, Conte WJ, Gordon-Nesbitt D, Feingold M, Laron Z, Rimoin DL. A unique association of short stature, dysmorphic features, and speech impairment (Floating-Harbor syndrome). J Pediatr. 1988;113:703-706.

14. Nagasaki K, Asami T, Sato H, Ogawa Y, Kikuchi T, Saitoh A, Ogata T, Fukami M. Long-term follow-up study for a patient with Floating-Harbor syndrome due to a hotspot SRCAP mutation. Am J Med Genet A. 2014;164A:731-735. Epub 2013 Dec 20

15. Bo H, Jiang L, Zheng J, Sun J. Floating-Harbor syndrome treated with recombinant human growth hormone: a case report and literature review. Front Pediatr. 2021;9:747353.

16. Jeon J, Noh ES, Hwang IT. Floating-Harbor syndrome in a Korean patient with short stature and early puberty: a case report. J Clin Res Pediatr Endocrinol. 2026;18:176-180. Epub 2024 Jan 17

17. Turkunova ME, Barbitoff YA, Serebryakova EA, Polev DE, Berseneva OS, Bashnina EB, Baranov VS, Glotov OS, Glotov AS. Molecular genetics and pathogenesis of the floating harbor syndrome: case report of long-term growth hormone treatment and a literature review. Front Genet. 2022;13:846101.

18. Stagi S, Galluzzi F, Bindi G, Lapi E, Cecchi C, Salti R, Chiarelli F. Precocious puberty in a girl with floating-harbor syndrome. J Pediatr Endocrinol Metab. 2007;20:1333-7.

CASE REPORT

JCRPE Journal of Clinical Research in Pediatric Endocrinology

DOI: 10.4274/jcrpe.galenos.2024.2024-6-25
J Clin Res Pediatr Endocrinol 2026;18(Suppl 1):25-29

A Rare Coexistence of Turner Syndrome and Mycosis Fungoides: A Case Report

Ozge Bayrak Demirel[1], Esin Karakilic-Ozturan[1], Tugba Atci[2], Sule Ozturk Sari[3], Can Baykal[2], Asli Derya Kardelen[1], Melek Yildiz[1], Sukran Poyrazoglu[1], Firdevs Bas[1], Feyza Darendeliler[1]

[1]İstanbul University, İstanbul Faculty of Medicine, Department of Pediatrics, Division of Pediatric Endocrinology, İstanbul, Türkiye
[2]İstanbul University, İstanbul Faculty of Medicine, Department of Dermatology and Venereology, İstanbul, Türkiye
[3]İstanbul University, İstanbul Faculty of Medicine, Department of Pathology, İstanbul, Türkiye

Cite this article as: Bayrak Demirel O, Karakilic-Ozturan E, Atci T, Ozturk Sari S, Baykal C, Kardelen AD, Yildiz M, Poyrazoglu S, Bas F, Darendeliler F. A rare coexistence of turner syndrome and mycosis fungoides: a case report. J Clin Res Pediatr Endocrinol. 2026;18(Suppl 1):25-29

What is already known on this topic?

Turner syndrome is linked to an increased prevalence of several autoimmune diseases and certain cancers, especially malignant melanoma, and nervous system and gastrointestinal malignancies. Mycosis fungoides, the most common primary cutaneous T-cell lymphoma, affects adults and children with slow progression that requires careful monitoring.

What this study adds?

This is the first published case of an 11-year-old girl with both Turner syndrome and mycosis fungoides. It highlights the importance of thorough dermatologic evaluation in Turner syndrome patients, especially for atypical skin lesions, suggesting mycosis fungoides as a potential differential diagnosis.

ABSTRACT

Turner syndrome (TS) is the most common sex chromosome abnormality among females, characterized by short stature, hypergonadotropic hypogonadism, congenital heart anomalies, and an increased risk of autoimmune diseases. Although TS does not typically increase the absolute risk of malignancy, specific cancers, such as those affecting the nervous system and gastrointestinal tract and malignant melanoma, may occur more frequently. Mycosis fungoides (MF) is the most common type of primary cutaneous T-cell lymphoma, generally affecting otherwise healthy adults but also seen in children and adolescents. We report an 11.2-year-old girl with TS presenting with substantial weight gain and short stature. Clinical examination revealed characteristic TS features and karyotype analysis confirmed mosaic TS. Following growth hormone (GH)

Corresponding Author: Ozge Bayrak Demirel, MD, İstanbul University, İstanbul Faculty of Medicine, Department of Pediatrics, Division of Pediatric Endocrinology, İstanbul, Türkiye
E-mail: drozgebayrak@gmail.com **ORCID:** orcid.org/0000-0001-7780-0231
Received: 01.07.2024 **Accepted:** 05.09.2024 **Epub:** 23.09.2024 **Publication Date:** 02.06.2026

©Copyright 2026 by Turkish Society for Pediatric Endocrinology and Diabetes / The Journal of Clinical Research in Pediatric Endocrinology published by Galenos Publishing House.
Licensed under a Creative Commons Attribution-NonCommercial-NoDerivatives 4.0 (CC BY-NC-ND) International License.

therapy, the patient developed persistent, erythematous, itchy skin lesions diagnosed as folliculotropic MF. GH therapy was discontinued, and topical steroids controlled the skin lesions effectively. MF in TS is very rare and unexpected, especially in a child. This is the first reported case of MF in a child with TS. This case highlights the importance of carefully evaluating skin lesions in patients with TS and suggests considering MF as a differential diagnosis.

Keywords: Turner syndrome, mycosis fungoides, malignancy, primary cutaneous T-cell lymphoma

Introduction

Turner syndrome (TS) is the most common sex chromosome abnormality among females, caused by the complete or partial absence of one of the X chromosomes, which is characterised by short stature, hypergonadotropic hypogonadism, congenital heart anomalies, and an increased risk of autoimmune disease (1). Although the absolute risk of malignancy has been reported not to increase in TS, some specific types of cancer, such as nervous system malignancies, gastrointestinal tract malignancies, or malignant melanoma, have been suggested to occur more frequently in patients with TS (2,3).

Mycosis fungoides (MF) is the most common type of primary cutaneous T-cell lymphoma. Adults in their fifth decade are predominantly affected by the condition, but it should be remembered that MF is also the most common cutaneous lymphoma in children and adolescents, albeit very rarely (4). MF typically exhibits an indolent course limited to the skin in the early stages when MF presents with skin lesions as patches or plaques. However, it may involve visceral organs in a small number of patients in advanced stages, usually associated with tumoral skin lesions. Epidermotropic tumor infiltration, atypical T-cell proliferation, and a cerebriform appearance are typical histopathologic manifestations of MF (5,6).

To the best of our knowledge, the coexistence of TS and MF has yet to be reported. Therefore, we report the clinical findings and follow-up of an 11-year-old girl with TS who developed MF.

Case Report

An 11.2-year-old girl was admitted to the outpatient clinic due to her parents' concerns about substantial weight gain and short stature. Her family noticed she was shorter than her peers and gained about 10 kg in the last two years. She was born at the 32nd week of gestation, from the first pregnancy of a 31-year-old mother. Her birth measurements were within normal range. The parents were nonconsanguineous, and the family history was uneventful. Her postnatal development had been entirely normal.

Her anthropometric measurements and pubertal status at the time of referral are shown in Table 1. A plethoric face and low posterior hairline were observed during the physical examination. Notably, she had acanthosis nigricans on the nape and purple striae on her thighs. Moreover, the shortening of both 5th metacarpals was remarkable. Apart from these findings, systemic examination was otherwise normal, and blood pressure was within the appropriate range for the patient's gender and height.

Given the suspicion of Cushing's syndrome, investigations were performed and the results of the dexamethasone suppression test, 24-hour urinary cortisol, and midnight salivary cortisol levels were all found to be normal. However, impaired glucose tolerance was detected during the oral glucose tolerance test, leading to the administration of metformin treatment. Furthermore, other laboratory examinations, including luteinizing hormone, follicle-stimulating hormone, and estradiol, were 2.21 mIU/mL, 12.18 mIU/mL, and 12.43 pg/mL, respectively (Table 1). These results suggested a diagnosis of TS. The karyotype analysis supported our suspicion, revealing compatibility with mosaic TS [45, X/46, X,i(Xq)/46, XX(8/3/49)]. Following the diagnosis of TS, growth hormone (GH) therapy was initiated. However, in the third month of GH treatment, the patient developed persistent, itchy, erythematous, follicular papules and plaques on her back, chest, axilla, and nape of the neck (Figure 1). It was learned that these lesions had recurred irregularly over the last three years and had improved with the use of short-term topical corticosteroid creams, as suggested by a dermatologist. There was no aggravation of the lesions following GH therapy. Aside from these skin lesions, the patient had no personal history of atopy, and familial atopy history was also unremarkable. A biopsy and histopathological examination was performed from a plaque lesion and revealed CD4+ MF with epidermotropic and adnexotropic characteristics (Figure 2). GH therapy was discontinued and topical steroid therapy was initiated. No additional treatment was required during the follow-up period as the initial and newly developed skin lesions remained well-controlled with topical steroids.

Discussion

MF usually affects adults around 50 years old, with a slight male predominance (7). However more than 5% of patients are diagnosed in childhood (8). We report a rare case of MF, a cutaneous malignancy uncommon in childhood, developing in an 11-year-old girl with TS. A wide variety of clinical presentations in patients with MF have been reported, including follicular papules, patches, indurated plaques, hypopigmented,

Table 1. Clinical and laboratory findings of the patient

	At time of referral	Last examination
Anthropometric measurements		
Age (years)	11.2	12.2
Weight kg/(SDS)	40.5/(0.2)	53.6/(0.9)
Height cm/(SDS)	132.8/(-2.1)	138.1/(-2.5)
BMI kg/m^2/(SDS)	22.8/(1.4)	28.1/(2.3)
Puberty stage (Tanner)	B2P1	B3P2
Bone age (year)	12	12.5
PAH cm (SDS)	144	146.6
Target height cm (SDS)	159 cm (-0.69)	
Hormonal profile		
LH (mIU/mL)	2.2	5.9
FSH (mIU/mL)	12.2	12.2
E2 (pg/mL)	12.4	14
AMH (ng/mL) (NR 0.62-11)	0.36	
HbA1C (%)	5.1	5.2
	OGTT- glucose (mg/dL) 0.' : 116 30.' : 131 60.' : 125 90.' : 121 120.': 144	**OGTT- insulin (µU/mL)** 0.' : 29 30.' : 168 60.' : 6 90.' : 9 120.': 36
Imaging		
Echocardiogram	Bicuspid aorta	
Renal US	Normal	
Pelvic US	R ovary 2.1 mL, L ovary 1.2 mL, uterus 3.8 mL	

SDS: standard deviation score, BMI: body mass index, PAH: pulmonary arterial hypertension, LH: luteinizing hormone, FSH: follicle-stimulating hormone, E2: estradiol, AMH: anti-Müllerian hormone, OGTT: oral glucose tolerance test, US: ultrasound

Figure 1. Erythematous plaque on (a) the nape and **(b)** the axilla

hyperpigmented, acneiform (comedones, cysts), or keratosis pilaris-like lesions (9). However, it has been reported that skin changes, including hypopigmentation, hyperpigmentation, and alopecia may accompany TS with a frequency of 5% (1). These skin changes in TS may be challenging to diagnose in the early stages, and may mimic various benign skin lesions like eczema, psoriasis, or other non-neoplastic skin disorders. Therefore, the diagnosis of MF, in this girl with late diagnosed TS, was surprising and unexpected. The clinical course of MF is usually chronic but indolent, characterized by a slow and gradual progression over years or even decades, from patches to more infiltrated plaques and then rarely to tumors (7).

MF may simulate a diverse range of benign inflammatory skin disorders both clinically and histopathologically (10). The differential diagnosis of the presented patient's skin lesions initially included psoriasis and pityriasis rosea; in lesions with follicular accentuation, keratosis pilaris, pityriasis rubra pilaris, and adnexotropic MF were considered. Histopathological examination of biopsied skin lesions revealed a thick band-like lymphocytic infiltrate in the superficial dermis and the presence of nonspongiotic epidermotropism, which is typically described in MF, helping to exclude other dermatoses (Figure 2a). The predominance of CD4 positive lymphocytes in both intraepidermal and dermal infiltration further supported the

J Clin Res Pediatr Endocrinol
2026;18(Suppl 1):25-29

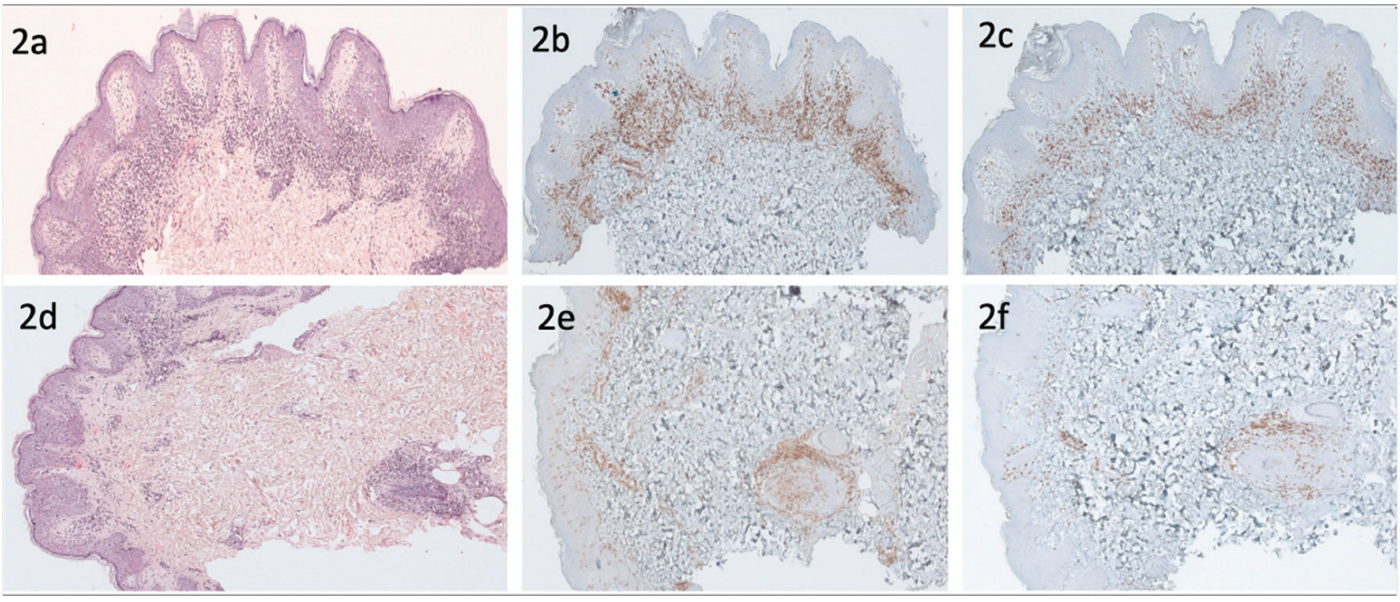

Figure 2. **(a)** Lymphocytic infiltration in the superficial dermis, with a band-like pattern, intermittently contacting the epidermis, in the biopsy taken from the left axilla (H&E, x50), **(b)** Predominance of CD4 staining within the infiltration (CD4, x50), **(c)** CD8 staining of the same specimen (CD8, x50), **(d)** In the biopsy taken from the left side of the trunk, a weaker infiltration is observed in the superficial dermis, while a lymphocytic infiltration around follicles and skin appendages is noticeable in the deeper layers. (H&E, x50), **(e)** Predominant CD4 positivity within the infiltration (CD4, x50), **(f)** Sparse reaction of CD8 staining in dermal lymphocytes (CD8, x50)

diagnosis of MF (Figure 2) (10). Furthermore, biopsies taken from the patient's trunk showed not only epidermotropism but also folliculotropism, supporting the diagnosis of folliculotropic MF.

Due to the presence of recurrent lesions over the last three years, we did not consider that the 3-month GH treatment might be related to MF in our patient. However, given the possibility of increased insulin-like growth factor-1 receptor expression with GH treatment (10), we decided to discontinue the hormonal therapy.

It is known that TS patients have a higher incidence of autoimmune diseases than the general population. Most MF patients are otherwise healthy but other cutaneous or systemic lymphomas have been reported to occur in nearly 7% of patients (11). Furthermore, recent research has indicated an increased prevalence of autoimmune disorders, including inflammatory bowel disease, systemic lupus erythematosus, and type 1 diabetes mellitus, among individuals with MF. This association is believed to stem from T-cell dysregulation (12). The etiology of MF in TS may also be associated with autoimmune dysregulation.

The hormonal abnormalities and treatments in TS may influence the risk of hormone-related malignancies, and the underlying chromosomal abnormality itself may also affect cancer risk (13). Ji et al. (14) reported that patients with TS have an increased risk of solid tumors, particularly malignant melanoma and central nervous system tumors. Another study by Viuff et al. (3) reported that patients with TS with the 45, X karyotype had a two to fivefold increased risk of benign CNS tumors, colorectal malignancies, and malignant melanoma, while TS women with the 45,X/46,XX karyotype had an increased risk of tongue cancer. In the latest guideline, the International Turner Syndrome Consensus Group recommended an annual skin assessment to identify dangerous lymphoedema, dermatitis, infections, autoimmune skin conditions and skin neoplasms, and appropriate evaluation and treatment by a dermatologist, if indicated (15). However, the subtype of neoplastic skin condition was not specified in this guideline. This case also supports an annual assessment by a dermatology specialist which may be beneficial, especially for the presence of skin lesions in cases with TS.

The present report, which describes the development of MF in a girl with TS, contributes to the existing literature concerning TS because, to the best of our knowledge, this is the first published report of the coexistence of MF and TS.

Conclusion

In conclusion, an 11-year-old girl with MF and mosaic TS is described. We believe this to be the first reported instance of this combination. Considering the possible increased risk for malignancies in patients with TS, a thorough evaluation of skin lesions is crucial. We suggest that MF should also be considered as a possible differential diagnosis. A dermatologic assessment may be necessary to confirm the diagnosis and guide appropriate treatment.

Ethics

Informed Consent: Informed consent was granted by the parents of the patient for publication.

Footnotes

Authorship Contributions: Surgical and Medical Practices: Tugba Atci, Sule Oztürk Sari, Can Baykal, Asli Derya Kardelen, Firdevs Bas, Concept: Esin Karakilic-Ozturan, Melek Yildiz, Design: Ozge Bayrak Demirel, Data Collection and Processing: Ozge Bayrak Demirel, Analysis or Interpretation: Sule Ozturk Sari, Can Baykal, Sukran Poyrazoglu, Feyza Darendeliler, Literature Search: Ozge Bayrak Demirel, Esin Karakilic-Ozturan, Melek Yildiz, Writing: Ozge Bayrak Demirel, Tugba Atci, Firdevs Bas.

Conflict of Interest: One author of this article, Feyza Darendeliler, is a member of the Editorial Board of the Journal of Clinical Research in Pediatric Endocrinology. However, the reviewers evaluating this manuscript were blinded and were from different institutions. She was not involved in the editorial review of this manuscript to avoid prejudice that may disrupt impartiality. The other author declares no conflict of interest. **Financial Disclosure:** The authors declared that this study received no financial support.

References

1. Gravholt CH, Viuff MH, Brun S, Stochholm K, Andersen NH. Turner syndrome: mechanisms and management. Nat Rev Endocrinol. 2019;15:601-614. Epub 2019 Jun 18
2. Kim SE, Park SH, Han K, Cho WK, Suh BK, Park YG. Population prevalence, cancer risk, and mortality risk of turner syndrome in South Korean women based on National Health Insurance service data. Yonsei Med J. 2022;63:991-998.
3. Viuff MH, Stochholm K, Lin A, Berglund A, Juul S, Gravholt CH. Cancer occurrence in Turner syndrome and the effect of sex hormone substitution therapy. Eur J Endocrinol. 2021;184:79-88.
4. Baykal C, Atcı T, Pehlivan Ulutaş G. Primary cutaneous lymphomas in pediatric age group: experience of a single dermatology center. Turk Arch Pediatr. 2023;58:229-231.
5. Cervini AB, Torres-Huamani AN, Sanchez-La-Rosa C, Galluzzo L, Solernou V, Digiorge J, Rubio P. Mycosis fungoides: experience in a pediatric hospital. Actas Dermosifiliogr. 2017;108:564-570. Epub 2017 Mar 7
6. Cerroni L. Mycosis fungoides-clinical and histopathologic features, differential diagnosis, and treatment. Semin Cutan Med Surg. 2018;37:2-10.
7. Willemze R, Jaffe ES, Burg G, Cerroni L, Berti E, Swerdlow SH, Ralfkiaer E, Chimenti S, Diaz-Perez JL, Duncan LM, Grange F, Harris NL, Kempf W, Kerl H, Kurrer M, Knobler R, Pimpinelli N, Sander C, Santucci M, Sterry W, Vermeer MH, Wechsler J, Whittaker S, Meijer CJ. WHO-EORTC classification for cutaneous lymphomas. Blood. 2005;105:3768-3785. Epub 2005 Feb 3
8. Yazganoglu KD, Topkarci Z, Buyukbabani N, Baykal C. Childhood mycosis fungoides: a report of 20 cases from Turkey. J Eur Acad Dermatol Venereol. 2013;27:295-300. Epub 2011 Dec 19
9. Willemze R. Mycosis fungoides variants-clinicopathologic features, differential diagnosis, and treatment. Semin Cutan Med Surg. 2018;37:11-17.
10. Hodak E, Amitay-Laish I. Mycosis fungoides: a great imitator. Clin Dermatol. 2019;37:255-267. Epub 2019 Jan 11
11. Joshi TP, Black TA, Fernandez B, Friske S, Stafford H, Strouphauer E, Duvic M. Comorbidities associated with mycosis fungoides: a case-control study in the All of Us database. J Am Acad Dermatol. 2023;88:686-688. Epub 2022 Jul 8
12. Schoemaker MJ, Swerdlow AJ, Higgins CD, Wright AF, Jacobs PA; UK Clinical Cytogenetics Group. Cancer incidence in women with Turner syndrome in Great Britain: a national cohort study. Lancet Oncol. 2008;9:239-246. Epub 2008 Feb 20
13. Ji J, Zöller B, Sundquist J, Sundquist K. Risk of solid tumors and hematological malignancy in persons with Turner and Klinefelter syndromes: a national cohort study. Int J Cancer. 2016;139:754-758. Epub 2016 Apr 19
14. Gravholt CH, Andersen NH, Christin-Maitre S, Davis SM, Duijnhouwer A, Gawlik A, Maciel-Guerra AT, Gutmark-Little I, Fleischer K, Hong D, Klein KO, Prakash SK, Shankar RK, Sandberg DE, Sas TCJ, Skakkebæk A, Stochholm K, van der Velden JA; International Turner Syndrome Consensus Group; Backeljauw PF. Clinical practice guidelines for the care of girls and women with Turner syndrome. Eur J Endocrinol. 2024;190:G53-G151.

CASE REPORT

JCRPE Journal of Clinical Research in Pediatric Endocrinology

DOI: 10.4274/jcrpe.galenos.2024.2024-3-5
J Clin Res Pediatr Endocrinol 2026;18(Suppl 1):30-36

Unraveling a Genetic Puzzle: Could *MAP3K7* Be a Candidate Gene for RASopathies?

Sirmen Kızılcan Çetin[1], Zeynep Şıklar[1], Zehra Aycan[1], Elif Özsu[1], Serdar Ceylaner[2], Merih Berberoğlu[1]

[1]Ankara University Faculty of Medicine, Department of Pediatric Endocrinology, Ankara, Türkiye
[2]Intergen Genetic Diagnosis and Research Center, Department of Medical Genetics, Ankara, Türkiye

Cite this article as: Kızılcan Çetin S, Şıklar Z, Aycan Z, Özsu E, Ceylaner S, Berberoğlu M. Unraveling a genetic puzzle: could *MAP3K7* be a candidate gene for RASopathies? J Clin Res Pediatr Endocrinol. 2026;18(Suppl 1):30-36

What is already known on this topic?

MAP3K7 variants have been associated with disorders such as cardiospondylocarpofacial syndrome and frontometaphyseal dysplasia 2. The incidence of Noonan syndrome (NS) is approximately 1:1000, and while genetic confirmation is ideal, it may not be possible for all cases. Moreover, negative genetic test results do not necessarily exclude NS, emphasizing the importance of clinical evaluation.

What this study adds?

The patient's clinical features, including short stature, valvular heart disease, and facial dysmorphismwere compatible with NS despite the *MAP3K7* variant being classified as a variant of uncertain significance. This case raises the question of whether *MAP3K7* may be a candidate gene for NS.

ABSTRACT

Noonan syndrome (NS) diagnosis may be challenging because of diverse clinical manifestations. This case report highlights a novel role for *MAP3K7* in NS. A 10.4-year-old female patient presented with short stature and clinical findings suggestive of RASopathy. Despite atypical facial features, the patient met two major van der Burgt diagnostic criteria. Initial genetic testing for known NS-associated genes did not find any variants. Later, whole exome sequencing identified a unique *de novo* heterozygous variant [c.65C>A, p.(P22H)] in *MAP3K7*. This variant, categorized as a variant of uncertain significance by the American College of Medical Genetics and Genomics criteria, raised questions about its potential role in NS. The patient's clinical presentation deviated from classical manifestations of *MAP3K7*-associated syndromes, highlighting

Corresponding Author: Sirmen Kızılcan Çetin, MD, Ankara University Faculty of Medicine, Department of Pediatric Endocrinology, Ankara, Türkiye
E-mail: drsrmnkzlcn@gmail.com **ORCID:** orcid.org/0000-0001-7397-3071
Received: 10.03.2024 **Accepted:** 07.10.2024 **Epub:** 17.10.2024 **Publication Date:** 02.06.2026

©Copyright 2026 by Turkish Society for Pediatric Endocrinology and Diabetes / The Journal of Clinical Research in Pediatric Endocrinology published by Galenos Publishing House.
Licensed under a Creative Commons Attribution-NonCommercial-NoDerivatives 4.0 (CC BY-NC-ND) International License.

the complexity of *MAP3K7* genetic and molecular mechanisms. Notably, this is the first case reported to associate *MAP3K7* variants with NS. Despite the known challenges in NS diagnosis, proper management, including recombinant growth hormone therapy, is important to optimize growth potential. The case suggests that *MAP3K7* may be a potential candidate gene for NS, but more functional genetic investigations are required to clarify the delicate interaction between genetic abnormalities, the RAS/mitogen-activated protein kinase pathway, and clinical manifestations observed in NS cases.

Keywords: Noonan syndrome, short stature, *MAP3K7*

Introduction

The group of diseases, collectively known as rasopathies, is caused by pathogenic gene changes that encode parts of the intracellular signaling pathway rat sarcoma/mitogen-activated protein kinase (RAS/MAPK). These diseases are characterized by common clinical traits, including distinctive facial features, short stature, and congenital heart disease (1). Noonan syndrome (NS) is the most predominant disorder among the rasopathies. Its prevalence ranges from 1 in 1,000 to 1 in 2,500 live births (2,3). The diagnosis of NS presents a challenge due to the wide range of clinical manifestations. However, since 1994, a scoring method devised by van der Burgt et al. (4) and van der Burgt (5) has significantly assisted in diagnosing NS accurately. A diagnosis of NS is confirmed if there is either a typical facial appearance coupled with one major and two minor clinical characteristic findings or if facial features indicative of NS are present together with two major or three minor clinical features (4,5). This system considers major criteria to include typical facial dysmorphology, cardiac anomalies (such as pulmonary valve stenosis and characteristic electrocardiographic findings), short stature (below the 3rd percentile), chest wall deformities (such as pectus carinatum, pectus excavatum), and additional features (intellectual disability, cryptorchidism, or lymphatic dysplasia). Minor criteria are suggestive facial dysmorphology, non-major heart defects, short stature (below the 10th percentile), broad chest, and suggestive features in first-degree relatives.

Nearly 20 genes (including *PTPN11, SOS1, SOS2, KRAS, NRAS, RIT1, RRAS, RASA1, RASA2, MRAS, RAF1, BRAF, MAP2K1, MAP3K8, SHOC2, PPP1CB, SPRY1, LZTR1, MYST4, A2ML1, CBL*), which are involved in the RAS/MAPK pathway and NS manifestation, have been described thus far (6,7). As a result, around 85% of cases can now be explained by known genetic factors. However, negative tests do not necessarily rule out the NS. Thus, clinical diagnosis remains vital (7,8). The etiology of the cases where the genetic pathogenesis remains unidentified provides an opportunity to expand the genetic repertoire and novel mechanisms in NS in the future, highlighting the importance of recognizing clinical features for precise diagnosis of NS.

In this case report, we present a patient with a *de novo* heterozygous variant in *MAP3K7*, c.65C>A, p.(P22H),, exhibiting facial features suggestive of NS and meeting two major van der Burgt criteria, thereby fulfilling the NS diagnostic criteria. This case highlights a potential novel role for *MAP3K7* in NS, prompting reconsideration of the intricate interplay between genetic anomalies, the RAS/MAPK pathway, and the diverse clinical manifestations observed in NS.

Case Report

A 10.4-year-old girl attended the outpatient clinic because of short stature. Her medical history revealed that she was born to non-consanguineous parents at 38 weeks of gestation, with a birth weight of 2500 g. She had undergone a number of clinical assessments. Her diagnosis had remained uncertain for a very long time. She had pulmonary valve stenosis, pectus excavatum, and failure to thrive in early infancy, so she was suspected to have NS. Karyotype was 46, XX (100 metaphases). Targeted gene panel sequencing of *PTPN11, SOS1,* and *RAF1* were unremarkable and microarray analysis was normal. On follow-up, her height was 110.8 cm [-3.3 standard deviation (SD)]. Treatment with recombinant growth hormone (rhGH) was initiated at 0.2 mg/kg/week at the age of 8.5 years. Linear growth during rhGH treatment was 5 cm/year in the first year and 8 cm/year in the second year of treatment. Whole exome sequencing (WES) revealed a novel heterozygous c.65C>A, p.(Pro22His) variant in *MAP3K7* (NM_145331.3) (Figure 1). The American College of Medical Genetics and Genomics (ACMG) criteria classify this variant as a variant of uncertain significance (VUS). The parents were informed by their doctor that all genetic tests were normal.

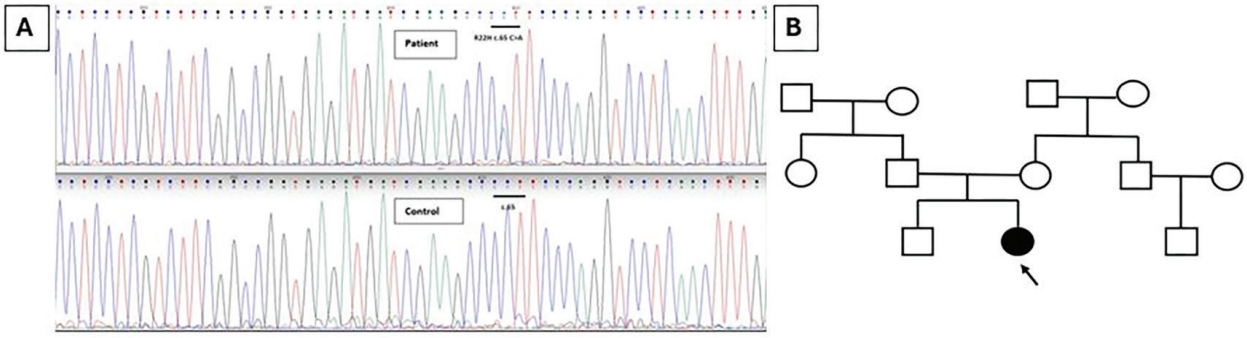

Figure 1. Electropherograms of the Sanger sequencing and the family tree of the patient

On first presentation to our clinic, her height was 124.5 cm (-2.57 SD), and her body mass index (BMI) was 14.58 kg/m^2 (-1.38 SD). The target height was 153.5 cm (-1.23 SD). Physical examination revealed phenotypic features including synophrys, prominent supraorbital ridges, mild ptosis, low set ears, full cheeks, broad nasal tip, deep elongated philtrum, thin upper vermillion, low anterior hairline, triangular face, short webbed neck, superior pectus carinatum and inferior pectus excavatum, short metacarpals and metatarsals, clinodactyly, syndactyly, intellectual disability, and dyslexia (Figure 2A).

Laboratory tests reported normal hemogram and biochemical parameters including blood glucose, thyroid function, tissue transglutaminase autoantibody immunoglobin A (IgA), serum total IgA, and liver and kidney function. Her urine test results were also normal. GH stimulation tests with clonidine excluded GH deficiency (peak GH of 9.63 ng/mL). The bone age was seven years and ten months, and the bone survey was normal with incidental accessory bone, os tibiale externum. Pituitary magnetic resonance imaging (MRI), showed a hypophyseal length of 2.5 mm (normal range: 4.5±0.6 mm) and cranial MRI was normal. Before the current presentation, she had not been followed up properly, her diagnosis was not certain and the rhGH treatment was experimental. Her growth velocity slowed by 1 cm/six months during follow-up at our clinic, so rhGH was stopped. Insulin-like growth factor 1 (IGF-1) levels were within the acceptable range for pubertal stage, gender, and age. There was no pathology on laboratory tests. The radiographic bone survey was normal (Figure 3). There was no finding suggestive of skeletal dysplasia. The patient underwent regular monitoring

Figure 2. A) Physical characteristics of the patient (synophrys, prominent supraorbital ridges, mild ptosis, low set ears, full cheeks, broad nasal tip, deep elongated philtrum, thin upper vermillion, low anterior hairline, short webbed neck, superior pectus carinatum, and inferior pectus excavatum. **B)** Pointed chin appearance of the patient

Figure 3. The radiographic bone survey of the patient

through electrocardiography, echocardiography, and abdominal and pelvic ultrasonography, which revealed no abnormal ultrasonographic findings. Subsequent echocardiograms showed a minimal atrial septal defect with no evidence of hypertrophic cardiomyopathy.

The *MAP3K7* c.65C>A variant was not identified in either parent through family segregation analysis, indicating a *de novo* occurrence. Clinically, the patient was diagnosed with NS based on Van der Burgt scoring (characterized by NS-like facial appearance, major short stature, cardiac symptoms, and pectus excavatum). Puberty (Tanner stage 2) began at 10.6 years of age.

Throughout follow-up, height velocity of only 1 cm/6 months was noted so rhGH treatment was restarted at 0.35 mg/kg/week, which was the recommended dosage for NS. Adjustments were made to the dose based on IGF-1 levels, eventually reducing it to 0.20 mg/kg/week (Figure 2).

At the latest evaluation, at 13 years of age, the patient was Tanner stage 3 with a height of 138 cm (-3.2 SD) and a BMI of 15.23 kg/m^2 (-2.18 SD score). During the approximately 3-years clinical follow-up at our clinic, a more pronounced pointed-chin appearance has become evident (Figure 2B). Yearly follow-ups included abdominal and pelvic ultrasonography and echocardiographic assessments, all revealing no pathological findings.

Methods

Genomic DNA was isolated from the patient's peripheral blood samples using established protocols. Genetic analyses were conducted through next-generation sequencing (Miseq, Illumina, San Diego, CA, USA) in accordance with the manufacturer's guidelines.

Results

The identified variant in the patient is exceptionally rare (gnomAD Allele Frequency 6.207e-7) and results in a change within a highly conserved gene across species. Computational tools predict it to be "disease causing," supported by MutationTaster, and deleterious with a Combined Annotation Dependent Depletion score of 23.0. Notably, this variant has not been documented in major databases such as ClinVar or dbSNP.

Discussion

Diagnosing NS in patients who lack the phenotypic characteristics presents a clinical challenge and atypical clinical anomalies may lead to a misdiagnosis. This diagnostic difficulty may also delay appropriate management and interventions. Although genetic testing has advanced, it is noteable that around 15% of patients with a clinical diagnosis of NS lack a definitive genetic diagnosis (7). Therefore, clinical assessment remains important even though there is widespread availability of genetic testing. Moreover, understanding and interpretation of WES findings is important for identifying potential variants related to NS, as the 15% of NS patients without genetic confirmation suggest there may be a number of variants or genes that play a pathogenic role in NS that are yet to be identified. Effective collaboration between clinicians and geneticists with expertise in dysmorphology and disease-specific features may help to identify these unidentified genetic associations. The guidelines established by the ACMG provide a framework for analyzing VUS, highlighting the need for collaboration between doctors and genetics professionals in resolving these uncertainties. The evolution of VUS classifications from "uncertain significance" to "likely pathogenic" or "pathogenic" is characteristic of the dynamic nature of genetic research and the potential for reclassification as our understanding improves (9).

MAP3K7 (MIM*602614) is a 17-exon gene located on chromosome 6q15. The MAPKs, (MAPKs), also known as extracellular signal-regulated kinases, are activated by a wide range of stimuli and serve as a convergence point for signaling pathways (1). Of note, with an autosomal inheritance pattern, NS is often caused by *de novo* variants (7). Segregation analysis, which demonstrates that neither of the proband's parents had the detected *MAP3K7* variant, supports the suggestion that the variant presented in the case described earlier was pathogenic. However, it is important to consider the effect of incomplete penetrance and variable expressivity, particularly in dominantly inherited conditions like those observed in RASopathy spectrum disorders. The parents might have also carried the variant with milder or asymptomatic presentations, highlighting the complexity of genetic inheritance and phenotypic expression in RASopathy spectrum disorders.

Pathogenic variants in *MAP3K7* have recently been linked to two disorders; cardiospondylocarpofacial syndrome (CSCFS) and frontometaphyseal dysplasia 2 (FMD2) (10,11,12,13,14,15). Interestingly, her presentation was not consistent with the typical features associated with either CSCFS or FMD2, particularly the absence of spinal and bone fusions in CSCFS (10,11,12) and the incongruence with flexion contractures of the elbow seen in FMD2 (13,14,15). The unique clinical manifestation, combined with the discovery of a novel likely pathogenic variant [c.125_127del, p.(Val42del)] in *MAP3K7* in another case reported by AbuBakr et al. (16), reinforces the benefit of comprehensive functional studies to clarify the precise mechanisms linking these genetic variants to the observed phenotypic traits. However, the patient described by AbuBakr et al. (16) displayed spinal and bone fusions in the hands and feet, which were associated with CSCFS (10,11,12), and elbow flexion contractures, a characteristic of FMD2 (13,14,15), though not CSCFS; the patient exhibited apparent "opposite" features. The two *MAP3K7*-associated syndromes that overlap may indicate the presence of a single disorder. This patient was misdiagnosed as NS for years based on the Var der Burgt criteria (16). The complexity of this case extends beyond the phenotypic range of CSCFS and FMD2, raising concerns about the underlying genetic and molecular mechanisms. The clinical features resembled the underlying mechanism of neurofibromatosis-NS (NFNS). NF1 and NS may exhibit similar features in some patients, leading to NFNS. The genetic basis of NFNS is not fully understood, and there is an ongoing debate about whether NFNS represents a variable manifestation of NF1 or NS or a distinct clinical entity. Some NFNS patients have variants in both *PTPN11* and *NF1*, but the majority only have *NF1* variants. As a result, most authors attribute NFNS to *NF1* variants (17,18). In another case report, an Asian male with CSCFS presented with a novel missense variant in *MAP3K7* (NM_145331.3: c.467A>T: p.Asp156Val)) and exhibited a mixed phenotype resembling Ehlers-Danlos syndrome and NS. This overlap in phenotypes suggested potential diagnostic implications for identifying CSCFS. In contrast, our case is exceptional because she did not exhibit clinical features typical of either CSCFS or FMD2 (19). This highlights the variability in clinical presentations associated with *MAP3K7* variants, contributing to the complexity of clinical diagnosis and genetic characterization. At the time of writing, *MAP3K7* had not been associated with NS. The patient's comprehensive bone X-ray examination revealed no findings of skeletal dysplasia, which ruled out both CSCFS or FMD2. The intriguing possible association between *MAP3K7* and NS may suggest a new insight into the underlying genetics of this condition.

This finding encouraged us to further investigate the interplay between genetic variants, the RAS/MAPK pathway, and the variable clinical manifestations. To further explore the potential impact of the c.65C>A, p.(Pro22His) variant in *MAP3K7*, according to the Kyoto Encyclopedia of Genes and Genome pathway database was interrogated. The *MAP3K7* is a key gene in the MAPK signaling pathway (hsa04010), which interacts with several other genes known to cause RASopathies, such as *KRAS, BRAF*, *RAF1, SOS1* and *NF1*. The involvement of *MAP3K7* in this pathway underscores its potential role in the pathogenesis of RASopathies. In our case, the absence of evidence of skeletal dysplasia suggested *MAP3K7* as the direct cause of the NS clinical presentation. Whether this gene is directly related to the NS clinical condition in our patient or if its interaction with a different

gene in the RASopathy pathway is a question that remains to be answered, ideally through future functional analysis studies. The absence of functional testing to support this assumption is the major limitation of our case report. Remarkably, our patient is the second documented case featuring a *MAP3K7* variant that did not result in the two recognized types of skeletal dysplasia and, more importantly, the first case with clinical evidence of its relationship with NS, based on the Van der Burgt criteria. We suggest that *MAP3K7* may be a candidate gene for NS. While this association is encouraging, more functional genetic research focusing on the precise pathways to which *MAP3K7* variants contribute is necessary to establish a definitive connection. The identified variant in the patient is exceptionally rare (gnomAD allele frequency=6.207e-7). Functional validation through protein structure modeling or *in vitro* studies will be crucial to elucidate this specific variant's impact on protein function and disease pathogenesis and to establish a definite association or not.

Without functional analysis, the pathogenicity of this variant and its role in the phenotypic presentation of NS remains unproven.

Moreover, the delayed diagnosis of NS has a domino effect on initiating appropriate medical interventions. In NS, rGH is effective and positively contributes to final height (20,21). Most adults' heights remain below the 3rd percentile without rGH treatment (21). Other pathologies that would cause low BMI were not suggested by clinical or laboratory evaluations. In NS patients, the growth response is more favorable when rGH treatment is initiated earlier and maintained longer. The duration of rGH usage before puberty and the height at the onset of puberty also impact near-final height (21). Delayed diagnosis will likely postpone growth hormone therapy initiation, limiting optimal growth potential, as was the situation with the current case. The relationships within the RAS/MAPK pathway will vary, depending on specific genotypic variations. In addition, differences in growth characteristics may depend on whether other pathways related to RAS/MAPK, including the PI3K/AKT and JAK2/STATb5 pathways, are affected or unaffected (21).

It is well-established that the RAS/MAPK pathway is implicated in various malignancies (20). Therefore, it will also be important to investigate the incidence of cancers in disorders associated with *MAP3K7* mutations, particularly in relation to the decision to initiate rGH therapy. In the presented case, detailed information was provided to the family, and rGH therapy was initiated with their consent. The patient was monitored at three-month intervals, including close IGF-1 level monitoring and abdominal-pelvic imaging studies.

She also had a low BMI. There is no difference in macronutrient intake in NS patients compared to healthy children, which might be attributed to increased energy expenditure (22). The distinctive chest deformity of the presented case with pectus carinatum in the upper section and pectus excavatum in the lower part of the chest is a remarkable anomaly (23,24). The dysmorphic characteristics of NS exhibit variations depending on age, with more pronounced characteristics in infancy, while facial features may not be readily noticeable during adolescence and adulthood. During the adolescent and young adult periods, the face takes on a more triangular contour (25). Throughout approximately three years of follow-up, there was a notable enhancement of the patient's jawline. All clinical findings were consistent with NS.

In conclusion, the identification of a novel *de novo* heterozygous variant [c.65C>A, p.(P22H)] in the *MAP3K7* raises intriguing questions about a potential role in NS pathogenesis. This is the first documented case associating a *MAP3K7* variant with clinically diagnosed NS, potentially expanding our understanding of genetic factors implicated in NS although functional *in silico* and/or *in vitro* studies will be required to strengthen this association. The unique clinical presentation in the described case, with no features of the classical manifestations of *MAP3K7*-related syndromes, highlights the intricate nature of genetic and molecular mechanisms. This finding raises questions about how the RAS/MAPK system, clinical symptoms seen in NS patients, and *MAP3K7* variants interact.

Ethics

Informed Consent: Informed consent for publication was obtained from the patient's parents.

Footnotes

Authorship Contributions

Surgical and Medical Practices: Sirmen Kızılcan Çetin, Zeynep Şıklar, Zehra Aycan, Elif Özsu, Serdar Ceylaner, Merih Berberoğlu, Concept: Sirmen Kızılcan Çetin, Zeynep Şıklar, Merih Berberoğlu, Design: Sirmen Kızılcan Çetin, Zeynep Şıklar, Serdar Ceylaner, Merih Berberoğlu, Data Collection or Processing: Sirmen Kızılcan Çetin, Zeynep Şıklar, Zehra Aycan, Elif Özsu, Merih Berberoğlu, Analysis or Interpretation: Sirmen Kızılcan Çetin, Zeynep Şıklar, Zehra Aycan, Elif Özsu, Literature Search: Sirmen Kızılcan Çetin, Zeynep Şıklar, Elif Özsu, Serdar Ceylaner, Writing: Sirmen Kızılcan Çetin, Zeynep Şıklar, Elif Özsu, Merih Berberoğlu.

Conflict of Interest: One author of this article, Merih Berberoğlu is a member of the Editorial Board of the Journal of Clinical Research in Pediatric Endocrinology. However, she did not involved in any stage of the editorial decision of the manuscript. The editors who evaluated this manuscript are from different institutions. The other authors declared no conflict of interest.

Financial Disclosure: The authors declared that this study received no financial support.

References

1. Tidyman WE, Rauen KA. The RASopathies: developmental syndromes of Ras/MAPK pathway dysregulation. Curr Opin Genet Dev. 2009;19:230-236. Epub 2009 May 19
2. Lepri FR, Scavelli R, Digilio MC, Gnazzo M, Grotta S, Dentici ML, Pisaneschi E, Sirleto P, Capolino R, Baban A, Russo S, Franchin T, Angioni A, Dallapiccola B. Diagnosis of Noonan syndrome and related disorders using target next generation sequencing. BMC Med Genet. 2014;15:14.
3. Tartaglia M, Zampino G, Gelb BD. Noonan syndrome: clinical aspects and molecular pathogenesis. Mol Syndromol. 2010;1:2-26. Epub 2010 Jan 15
4. van der Burgt I, Berends E, Lommen E, van Beersum S, Hamel B, Mariman E. Clinical and molecular studies in a large Dutch family with Noonan syndrome. Am J Med Genet. 1994;53:187-191.
5. van der Burgt I. Noonan syndrome. Orphanet J Rare Dis. 2007;2:4.
6. Malaquias AC, Jorge AAL. Activation of the MAPK pathway (RASopathies) and partial growth hormone insensitivity. Mol Cell Endocrinol. 2021;519:111040. Epub 2020 Oct 1
7. Roberts AE. Noonan syndrome. 2001 Nov 15 [updated 2025 Dec 4]. In: Adam MP, Bick S, Mirzaa GM, Pagon RA, Wallace SE, Amemiya A, editors. GeneReviews® [Internet]. Seattle (WA): University of Washington, Seattle; 1993-2026.
8. Ranke MB, Heidemann P, Knupfer C, Enders H, Schmaltz AA, Bierich JR. Noonan syndrome: growth and clinical manifestations in 144 cases. Eur J Pediatr. 1988;148:220-227.
9. Richards S, Aziz N, Bale S, Bick D, Das S, Gastier-Foster J, Grody WW, Hegde M, Lyon E, Spector E, Voelkerding K, Rehm HL; ACMG Laboratory Quality Assurance Committee. Standards and guidelines for the interpretation of sequence variants: a joint consensus recommendation of the American College of Medical Genetics and Genomics and the Association for Molecular Pathology. Genet Med. 2015;17:405-424. Epub 2015 Mar 5
10. Sousa SB, Baujat G, Abadie V, Bonnet D, Sidi D, Munnich A, Krakow D, Cormier-Daire V. Postnatal growth retardation, facial dysmorphism, spondylocarpal synostosis, cardiac defect, and inner ear malformation (cardiospondylocarpofacial syndrome?)--a distinct syndrome? Am J Med Genet A. 2010;152A:539-546.
11. Le Goff C, Rogers C, Le Goff W, Pinto G, Bonnet D, Chrabieh M, Alibeu O, Nistchke P, Munnich A, Picard C, Cormier-Daire V. Heterozygous mutations in MAP3K7, encoding TGF-β-activated kinase 1, cause cardiospondylocarpofacial syndrome. Am J Hum Genet. 2016;99:407-413. Epub 2016 Jul 14
12. Morlino S, Castori M, Dordoni C, Cinquina V, Santoro G, Grammatico P, Venturini M, Colombi M, Ritelli M. A novel MAP3K7 splice mutation causes cardiospondylocarpofacial syndrome with features of hereditary connective tissue disorder. Eur J Hum Genet. 2018;26:582-586. Epub 2018 Feb 21
13. Basart H, van de Kar A, Adès L, Cho TJ, Carter E, Maas SM, Wilson LC, van der Horst CM, Wade EM, Robertson SP, Hennekam RC. Frontometaphyseal dysplasia and keloid formation without FLNA mutations. Am J Med Genet A. 2015;167:1215-1222. Epub 2015 Apr 21
14. Wade EM, Daniel PB, Jenkins ZA, McInerney-Leo A, Leo P, Morgan T, Addor MC, Adès LC, Bertola D, Bohring A, Carter E, Cho TJ, Duba HC, Fletcher E, Kim CA, Krakow D, Morava E, Neuhann T, Superti-Furga A, Veenstra-Knol I, Wieczorek D, Wilson LC, Hennekam RC, Sutherland-Smith AJ, Strom TM, Wilkie AO, Brown MA, Duncan EL, Markie DM, Robertson SP. Mutations in MAP3K7 that alter the activity of the TAK1 signaling complex cause frontometaphyseal dysplasia. Am J Hum Genet. 2016;99:392-406. Epub 2016 Jul 15
15. Costantini A, Wallgren-Pettersson C, Mäkitie O. Expansion of the clinical spectrum of frontometaphyseal dysplasia 2 caused by the recurrent mutation p.Pro485Leu in MAP3K7. Eur J Med Genet. 2018;61:612-615. Epub 2018 Apr 14
16. AbuBakr F, Jeffries L, Ji W, McGrath JM, Lakhani SA. A novel variant in *MAP3K7* associated with an expanded cardiospondylocarpofacial syndrome phenotype. Cold Spring Harb Mol Case Stud. 2020;6:a005207.
17. Ekvall S, Sjörs K, Jonzon A, Vihinen M, Annerén G, Bondeson ML. Novel association of neurofibromatosis type 1-causing mutations in families with neurofibromatosis-Noonan syndrome. Am J Med Genet A. 2014;164A:579-587. Epub 2013 Dec 19
18. De Luca A, Bottillo I, Sarkozy A, Carta C, Neri C, Bellacchio E, Schirinzi A, Conti E, Zampino G, Battaglia A, Majore S, Rinaldi MM, Carella M, Marino B, Pizzuti A, Digilio MC, Tartaglia M, Dallapiccola B. NF1 gene mutations represent the major molecular event underlying neurofibromatosis-Noonan syndrome. Am J Hum Genet. 2005;77:1092-1101. Epub 2005 Oct 26
19. Minatogawa M, Miyake N, Tsukahara Y, Tanabe Y, Uchiyama T, Matsumoto N, Kosho T. Expanding the phenotypic spectrum of cardiospondylocarpofacial syndrome: from a detailed clinical and radiological observation of a boy with a novel missense variant in *MAP3K7*. Am J Med Genet A. 2022;188:350-356.
20. Şıklar Z, Genens M, Poyrazoğlu Ş, Baş F, Darendeliler F, Bundak R, Aycan Z, Savaş Erdeve Ş, Çetinkaya S, Güven A, Abalı S, Atay Z, Turan S, Kara C, Can Yılmaz G, Akyürek N, Abacı A, Çelmeli G, Sarı E, Bolu S, Korkmaz HA, Şimşek E, Çatlı G, Büyükinan M, Çayır A, Evliyaoğlu O, İşgüven P, Özgen T, Hatipoğlu N, Elhan AH, Berberoğlu M. The growth characteristics of patients with Noonan syndrome: results of three years of growth hormone treatment: a nationwide multicenter study. J Clin Res Pediatr Endocrinol. 2016;8:305-312. Epub 2016 Apr 29
21. Rodríguez F, Gaete X, Cassorla F. Etiology and treatment of growth delay in Noonan syndrome. Front Endocrinol (Lausanne). 2021;12:691240.
22. da Silva FM, Jorge AA, Malaquias A, da Costa Pereira A, Yamamoto GL, Kim CA, Bertola D. Nutritional aspects of Noonan syndrome and Noonan-related disorders. Am J Med Genet A. 2016;170:1525-1531. Epub 2016 Apr 1
23. Romano AA, Allanson JE, Dahlgren J, Gelb BD, Hall B, Pierpont ME, Roberts AE, Robinson W, Takemoto CM, Noonan JA. Noonan syndrome: clinical features, diagnosis, and management guidelines. Pediatrics. 2010;126:746-759. Epub 2010 Sep 27
24. Allanson JE, Roberts AE. Noonan syndrome. Cassidy and Allanson's management of genetic syndromes. 2021:651-69.
25. Roberts AE, Allanson JE, Tartaglia M, Gelb BD. Noonan syndrome. Lancet. 2013;381:333-342. Epub 2013 Jan 10

CASE REPORT

JCRPE Journal of Clinical Research in Pediatric Endocrinology

DOI: 10.4274/jcrpe.galenos.2024.2024-7-18
J Clin Res Pediatr Endocrinol 2026;18(Suppl 1):37-44

Gonadoblastoma with Dysgerminoma in a Virilized Adolescent with Karyotype 46,XX: A Case Report and Review of the Literature

Tugce Kandemir[1], Esin Karakilic Ozturan[1], Ozlem Dural[2], Ayca Dilruba Aslanger[3], Elif Inan Balci[1], Aysel Bayram[4], Semen Onder[4], Asli Derya Kardelen[1], Melek Yildiz[1], Sukran Poyrazoglu[1], Firdevs Bas[1], Feyza Darendeliler[1]

[1]İstanbul University, İstanbul Faculty of Medicine, Department of Pediatric Endocrinology, İstanbul, Türkiye
[2]İstanbul University, İstanbul Faculty of Medicine, Department of Obstetrics and Gynecology, İstanbul, Türkiye
[3]İstanbul University, İstanbul Faculty of Medicine, Department of Medical Genetics, İstanbul, Türkiye
[4]İstanbul University, İstanbul Faculty of Medicine, Department of Medical Pathology, İstanbul, Türkiye

Cite this article as: Kandemir T, Karakilic Ozturan E, Dural O, Aslanger AD, Inan Balci E, Bayram E, Onder S, Kardelen AD, Yildiz M, Poyrazoglu S, Bas F, Darendeliler F. Gonadoblastoma with dysgerminoma in a virilized adolescent with karyotype 46,XX: a case report and review of the literature. J Clin Res Pediatr Endocrinol. 2026;18(Suppl 1):37-44

What is already known on this topic?

Gonadoblastomas typically affect individuals with 46,XY gonadal dysgenesis or females with Y chromosome material, rarely occurring in 46,XX women. Preventive gonadectomy is recommended for those with partial or complete gonadal dysgenesis due to the high malignancy risk associated with the Y chromosome material.

What this study adds?

The case expands the published evidence concerning gonadoblastoma by detailing its presentation, diagnosis, and management in a progressively virilized 46,XX patient. For progressive hirsutism and virilization without typical symptoms like abdominal pain, diagnostic laparoscopy and biopsy may be considered when conventional methods are inconclusive. Confirming the Y chromosomal material status is crucial when gonadal dysgenesis is suspected.

ABSTRACT

Gonadoblastoma is a rare gonadal tumor composed of sex cord cells and primitive germ cells. While the majority of gonadoblastomas are found in individuals with 46,XY gonadal dysgenesis, they are also rarely seen in patients with a 46,XX karyotype. We report a case of a 14.5 year-old girl presenting with an uncommon cause of virilization; a virilizing ovarian tumor. The patient underwent bilateral salpingo-oophorectomy. Upon histopathological examination, the excised tumor was confirmed to be bilateral gonadoblastoma, with dysgerminoma on the left side.

Corresponding Author: Tugce Kandemir, MD, İstanbul University, İstanbul Faculty of Medicine, Department of Pediatric Endocrinology, İstanbul, Türkiye
E-mail: tgcknd mr@gmail.com **ORCID:** orcid.org/0000-0003-1561-2862
Received: 30.07.2024 **Accepted:** 08.10.2024 **Epub:** 10.10.2024 **Publication Date:** 02.06.2026

©Copyright 2026 by Turkish Society for Pediatric Endocrinology and Diabetes / The Journal of Clinical Research in Pediatric Endocrinology published by Galenos Publishing House.
Licensed under a Creative Commons Attribution-NonCommercial-NoDerivatives 4.0 (CC BY-NC-ND) International License.

Malignant gonadal tumors should be considered in cases of primary gonadal insufficiency with a 46,XX karyotype and progressive virilization. Even when laboratory and imaging tests show no abnormalities, a gonadal biopsy should be considered.

Keywords: Dysgerminoma, gonadoblastoma, virilization, XX gonadal dysgenesis

Introduction

Hyperandrogenism and the resulting manifestations in young female children can stem from various inherited and acquired causes. In some cases, androgen-producing tumors in the ovaries or adrenal glands can quickly lead to virilization. Gonadoblastomas are uncommon ovarian tumors composed of sex cord and primitive germ cell components. While gonadoblastomas are typically benign, they are often found alongside invasive germ cell malignancies. Typically, the tumor is observed in individuals with certain gonadal gene mutation syndromes, such as pure or mixed gonadal dysgenesis. The majority of gonadoblastomas are found in individuals with 46,XY gonadal dysgenesis, as well as in females carrying Y chromosome material. However, it is exceptionally rare for gonadoblastoma to occur in women with a normal 46,XX karyotype (1,2). We present a case report of a 14.5-year-old girl with a normal 46,XX karyotype who was diagnosed with gonadoblastoma accompanied by dysgerminoma. We describe the clinical symptoms exhibited by the patient and the outcome of her treatment, along with a comprehensive analysis of previously reported cases of gonadoblastoma occurring in individuals with a typical 46,XX karyotype.

Case Report

A 14.5-year-old girl was referred to our outpatient clinic because of significant hirsutism developing over the preceeding two months. She was born at term, appropriate for gestational age, to first-degree consanguineous parents after an uneventful pregnancy, and her developmental milestones were normal. Puberty began at the age of 10.5 years, but menarche has not yet occurred.

At presentation, her weight, height, and body mass index (BMI) were 42.7 kg [-1.95 standard deviation score (SDS)], 158.1 cm (-0.5 SDS), and 17.08 kg/m^2 (1.85 SDS), respectively. The pubertal stage was Tanner 4, and her external genitalia were remarkable for marked clitoromegaly, measuring 1.5x1 cm, with symmetrical labioscrotal folds and no palpable gonads. The modified Ferriman-Gallwey (mFG) score was 16, and a significant deepening of her voice was notable. Otherwise, the systemic examination was normal.

Hormonal evaluation revealed high serum luteinizing hormone (43.4 mIU/L) and follicle-stimulating hormone (87.6 mIU/L) levels, confirming the diagnosis of hypergonadotropic hypogonadism. In addition, serum total testosterone concentration was elevated (1.07 ng/mL). Basal levels of androgen precursors were normal (see Table 1), and adrenal-derived hyperandrogenism was ruled out with a normal response to a corticotropin stimulation test. Tumor markers, including b-human chorionic gonadotropin (β-hCG), α-fetoprotein (αFP), and lactate dehydrogenase (LDH), were normal. Abdominal ultrasound (US) showed no abnormalities, and bilateral adrenal glands were normal. Pelvic US showed that the size of the uterus and ovaries were appropriate for the pubertal stage. In this hypergonadotropic hypogonadism patient with hyperandrogenism, cytogenetic analysis revealed a normal female karyotype (46,XX).

Unfortunately, the patient missed follow-up visits for two years. At the age of 16.3 years, she was re-evaluated. During the past two years, she had become increasingly uncomfortable due to progressive hirsutism and needed laser hair removal session every two weeks on her whole body. At this time, the mFG score was 22, and clitoral length was measured at 3 cm. Fibrotic ovarian tissue was detected; however, no abdominal or gonadal

Table 1. Clinical, laboratory and radiological examination of the patient during follow up

	At initial presentation	Before gonadectomy	After gonadectomy
Age (years)	14.6	16.3	17.2
Anthropometric evaluation			
Height, cm (SDS)	158.1 (-0.5)	159.5 (-0.51)	159.5 (-0.6)
Weight, kg (SDS)	42.7 (-1.95)	42.4 (-2.47)	40.6 (-3.0)
BMI, kg/m^2 (SDS)	17.08 (-1.85)	16.6 (-2.72)	15.9 (-3.7)
Puberty Tanner Clitoromegaly	B4/4 P5 2-1.5 cm	B4/4 P5 3 cm	B5/5 P5 2.5x2 cm
Ferriman-Gallwey score	16	22	NA

Table 1. Continued

	At initial presentation	Before gonadectomy	After gonadectomy
Hormonal findings			
LH, mIU/mL (N=0.4-11.7)	43.4	32	43.7
FSH, mIU/mL (N=1-9.2)	87.6	85	86.6
E_2, pg/mL (N=12.5-166)	26.7	20	32
T, ng/mL (N=0.23-1.39)	1.07	1.57	0.07
DHT, pg/mL (N=30-180)	114	NA	NA
T/DHT	9.3	NA	NA
AMH, ng/mL (N=0.62-7.8)	3.05	3	NA
DHEA-S, ug/dL (N=44-248)	331	317	NA
Cortisol, ug/dL (N=8-19)	18.2	NA	NA
ACTH, pg/mL (N=6-48)	19	17	NA
17-OHP, ng/mL (N=0.44-2.35)	0.57	NA	0.8
1,4 AS, ng/mL (N=0.5-2.24)	1	4.1	1.6
AS/T (N≥0.8)	0.93	2.6	22.9
P, ng/mL (N=0.057-0.893)	0.37	NA	NA
SHBG, nmol/L (N=36-125)	NA	24.7	NA
CA 19.9, U/mL (N=0-34)	NA	NA	13.6
β-hCG, mIU/mL (N≤5)	0.93	NA	NA
AFP, ng/mL (N≤13.6)	2.2	1.9	1.8
LDH, U/L (N=150-300)	166	223	170
Imaging			
Pelvic US	**Uterus:** 41x17x65 mm **Right adnexa:** 9.5 mL **Left adnexa:** 10.9 mL	**Uterus:** 28x13.3x63 mm cervix/fundus:1 **Adnexa:** Bilateral ovaries could not be clearly distinguished. Isoechoic tissue areas containing cystic openings, which may be compatible with the follicle cyst, whose volume was measured as 1.1 mL on the right and 1 ml on the left, were observed in the ovarian lobes. Fibrotic ovarian tissue?	
Pelvic MRI		**Uterus:** Uterine size, parenchyma and echogenicity are normal **Ovaries:** Could not be seen	**Uterus:** 43x18x11 mm, its dimensions are reduced. **Ovaries:** Bilateral ovaries were not seen.
Histopathology			
		Bilateral gonadoblastoma and unilateral (left) dysgerminoma	

ACTH: Adrenocorticotropic hormone, AFP: α-fetoprotein, AMH: Anti-Mullerian hormone, BMI: Body mass index, CA 19-9: Carbohydrate antigen 19-9, 1,4 AS: 1,4 Androstenedione, DHEA-S: Dehydroepiandrosterone sulfate, DHT: Dihydrotestosterone, E2: Estradiole, FSH: Follicle-stimulating hormone , β-hCG: Human chorionic gonadotrophin, LDH: Lactate dehyrogenase, LH: Luteinizan hormone, 17-OHP: 17-hydroxy progesterone, N: Normal value, NA: Not avaliable, P: Progesterone, SHBG: Sex hormone binding globuline, T: Total testosterone, US: Ultrasonography, MRI: Magnetic resonance imaging

mass was visualised on US. Abdominal magnetic resonance imaging (MRI) revealed similar findings (as shown in Table 1). Fluorescence *in situ* hybridization analysis showed no alterations in the *SRY* gene. Polymerase chain reaction (PCR) analysis for the *SRY* gene sequence in the DNA sample obtained from ovarian tissue did not show the presence of *SRY*. In addition, whole exome sequencing was performed to comprehensively assess all known genetic disorders, with a particular focus on sex-determining genes, such as *WT1*, *SOX9*, and *DAX1*. A laparoscopic gonad biopsy was performed and it revealed bilateral gonadoblastoma and unilateral (left) dysgerminoma. Ultimately, the patient underwent bilateral oophorectomy. Macroscopic pathological examination of the salpingo-oophorectomy material revealed a right ovary measuring 3×1×0.5 cm, while the left ovary was slightly larger, measuring 2.7×1.5×3 cm.

Histopathological microscopic analysis provided further insight into the cellular composition. The specimen revealed the presence of primitive germ cells alongside sex cord stromal cells, surrounded by ovarian-type stroma. Notably, morphological analysis identified a dysgerminoma in the left ovary. This tumor exhibited characteristic cell cords, featuring both clear and eosinophilic cytoplasm, and measured approximately 0.5 cm in diameter. Immunohistochemical staining was performed to further classify the cellular components. The sex cord cells within the gonadoblastoma stained positively for inhibin, confirming their identity. In contrast, the germ cells within the dysgerminoma stained positively for C-kit, which is a known marker for germ cell tumors. These staining patterns facilitated the differentiation of the various cell types present within the tumor (see Figure 1). No pathological F-18 fluorodeoxyglucose uptake was detected on positron emission tomography/computed tomography, and she did not require or receive any chemotherapy. The bone mineral density z-score was -1.7, and hormone replacement therapy was commenced following gonadectomy. Pelvic MRI and tumor markers were subsequently checked at 6-month intervals, with no abnormal findings evident.

Discussion

We describe a girl with a 46,XX karyotype who exhibited virilization, a condition rarely caused by gonadoblastoma. The etiology of virilization in this girl was clinically challenging due to the variety of potential causes. Various inherited and acquired conditions may contribute to virilization, including disorders of sex development (DSD), virilizing ovarian tumors, adrenal tumors, and exposure to exogenous androgens. Among the DSD conditions, different forms of congenital adrenal hyperplasia, ovotesticular DSD, and aromatase deficiency may manifest with hyperandrogenic features in females. These conditions contribute to the clinical spectrum of causes that need to be considered when evaluating virilization in a young girl. The severity of virilization served as an important clinical indicator, suggesting an ovarian cause as the underlying factor in this girl. The rapid and severe nature of the virilization, combined with the exclusion of adrenal causes by a normal corticotropin stimulation test and normal adrenal precursor levels, directed the clinical suspicion toward an androgen-secreting ovarian tumor.

Gonadoblastoma was first recognized as a distinct entity by Scully (1) in 1953. Histologically, it is characterized by the presence of distinct clusters consisting of germ cells and sex cord elements that resemble immature Sertoli or granulosa cells. Histopathologically, the present case exhibited sex cord cells in the gonadoblastoma and germ cells in the dysgerminoma.

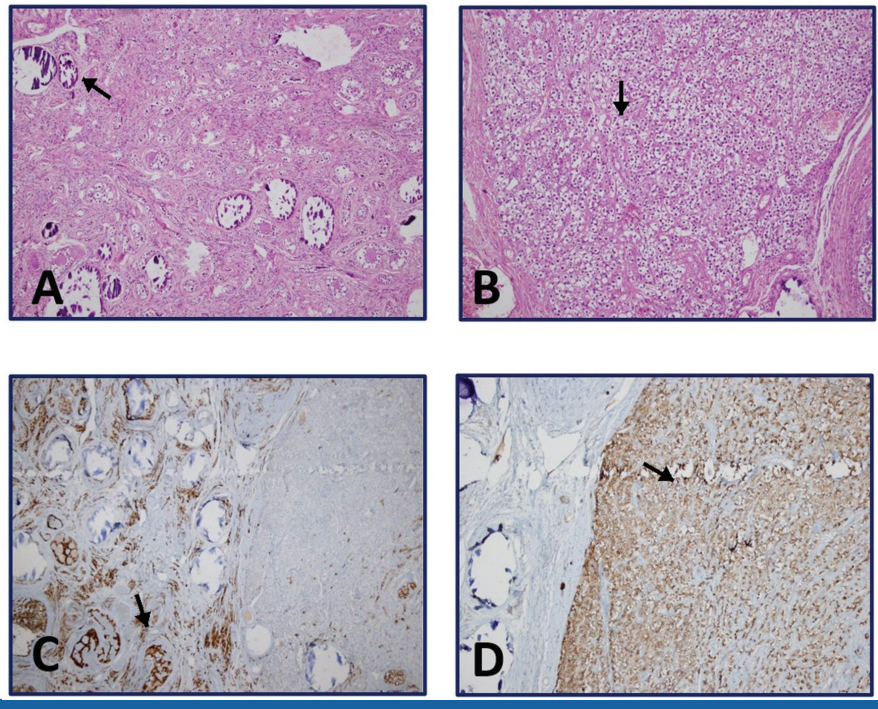

Figure 1. The figure illustrates the histopathological appearance of the biopsy specimens. **A**) Area of gonadoblastoma with calcification. Hematoxylin and eosin, x40 magnification. **B**) An area of dysgerminoma consisting of germ cells. Hematoxylin and eosin, x100 magnification. **C**) Staining of sex cord cells in gonadoblastoma with inhibin. x20 magnification. **D**) Staining of germ cells in the area of dysgerminoma with C-kit. x40 magnification

Gonadoblastoma has a high incidence in patients with various syndromes of gonadal maldevelopment that are characterized by the presence of the Y chromosome (2). Gonadoblastomas are observed in approximately 25% to 30% of patients with XY gonadal dysgenesis and in approximately 15% to 20% of individuals with a karyotype of 45,X/46,XY (2). However, a number of cases have been reported in females with a normal 46,XX karyotype. Pratt-Thomas and Cooper (3) reported a case where unilateral gonadoblastoma that was found in association with a ruptured ectopic tubal pregnancy, and the cytogenetic evaluation of peripheral leukocytes revealed a karyotype of 46,XX/45,XO.

In individuals with a 46,XX karyotype, the mechanism underlying the development of gonadoblastoma in the absence of a Y chromosome remains unclear. However, potential contributing factors may include somatic mutations, epigenetic changes, or hormonal influences. Somatic mutations in genes such as *WT1* and *SF1* may disrupt gonadal development, leading to tumorigenesis. Epigenetic alterations, including DNA methylation or histone modifications, may silence or activate genes inappropriately, leading to abnormal gonadal development (4,5). Hormonal influences, such as elevated gonadotropin levels, are thought to potentially play a role in the development of gonadoblastoma but the precise mechanisms underlying this association have yet to be fully elucidated (6). Future studies are essential to elucidate these alternative pathways, and understanding such mechanisms may reveal novel targets for early detection and treatment in the 46,XX population of patients with gonadoblastoma.

While gonadoblastomas are typically considered benign, they often coexist with invasive germ cell malignant tumors. The most prevalent malignancy found in association with gonadoblastomas is pure dysgerminoma. However, other variants, such as immature teratoma, embryonal carcinoma, yolk sac tumor, and choriocarcinoma, have also been reported. In Scully's review of 74 gonadoblastoma cases approximately 50% of the tumors were accompanied by dysgerminoma as a coexisting germ cell tumor. This is similar to the presented case and consistent with previous studies. Other types of germ cell tumors, such as embryonal carcinoma, yolk sac tumor, and teratoma, were also reported in a few cases (1,7).

In our review of the literature since 1990, we identified 14 cases of gonadoblastoma in females with a normal 46,XX karyotype (7-20). Table 2 presents a summary of the clinical characteristics observed in these 14 cases as documented in the literature and also includes the presented case for comparison. While abdominal symptoms, such as abdominal pain or the presence of a mass, were the most common complaints in the 15 reported cases (66%, 10/15 cases), it is important to note that cases have also presented with symptoms such as vaginal bleeding, menstrual disorders, and virilization. Our case unusual because of several distinctive findings. Firstly, there was an absence of abdominal pain, which is a common complaint in similar cases. Moreover, both physical examination and imaging tests (US and MRI) did not identify any masses. Furthermore, the levels of tumor markers, including αFP, β-HCG, and LDH were not significantly elevated. Given these unique characteristics, an important aspect of the present case was that the diagnosis made through diagnostic laparoscopy. In the case reported by Chandrapattan et al. (19), and similar to our case, the chief complaint was virilization. Furthermore, contrasexual pubertal development was observed in that particular case.

In individuals with partial or complete gonadal dysgenesis, preventive bilateral gonadectomy is commonly recommended due to the markedly increased risk of gonadal malignancy (15% to 50%) associated with the presence of the Y chromosome (20). Therefore, it is important to confirm if Y chromosomal material is present or not. Typically, peripheral blood lymphocyte karyotyping is performed to detect Y chromosomes in the germline but this approach carries the risk of missing small chromosomal fragments containing Y chromosome material. In the presented case, PCR analysis for the *SRY* gene sequence in the DNA sample obtained from the ovarian tissue did not demonstrate the presence of *SRY*.

Surgery is the primary treatment method for the management of gonadoblastomas. The specific surgical approach may vary depending on the extent and characteristics of the tumor. It is important to consider individual patient factors and provide appropriate adjunct therapies, such as chemotherapy, to support the overall treatment plan. Out of the 14 previously documented cases, chemotherapy was administered in nine (64.3%) cases. Due to the localized and small nature of the tumor in our patient, chemotherapy was deemed unnecessary.

Conclusion

It is important to consider that when managing hirsutism and progressive virilization, laparoscopy should be performed so that biopsies may provide guidance when imaging methods and laboratory tests fail to yield a definitive diagnosis. Further studies are needed to elucidate the etiopathogenesis of reported cases.

J Clin Res Pediatr Endocrinol
2026;18(Suppl 1):37-44

Table 2. A review of published female cases of gonadoblastoma with karyotype 46,XX

No	Author	Year	Age at diagnosis	Clinical presentation	Fertile status	Hormonal abnormalities	Laterality	Karyotype	Tumor size	Surgical procedure	Pathological findings in addition to gonadoblastoma	Adjuvant therapy
1	Erhan et al. (8)	1992	26	Abdominal mass during pregnancy	Fertile	NR	Right	46, XX	20 cm	TAH + BSO	Dysgerminoma	Chemotherapy
2	Obata et al. (7)	1995	10	Abdominal discomfort	No	NR	Bilateral	46, XX	8 cm	USO + right Ovarian cystectomy	Left with dysgerminoma, right with dysgerminoma and yolk sac tumor	Chemotherapy
3	Zhao et al. (9)	2000	27	Abdominal pain	Fertile	NR	Right	46, XX	10x8x6 cm	USO + chemotherapy + later TAH + USO + LND + omentectomy	Choriocarcinoma, embryonal carcinoma, yolk sac tumor, immature teratoma and dysgerminoma	Chemotherapy
4	Erdemoglu and Ozen (12)	2007	19	Abdominal mass and pain	No	NR	Unilateral	46, XX	25x22x20 cm	USO	Endodermal sinus tumor	None
5	Yilmaz et al. (10)	2010	20	Abdominal mass	No	NR	Bilateral	46, XX	21x21x11 cm	BSO	Bilateral with dysgerminoma	Radiation and chemotherapy
6	Koo et al. (11)	2011	34	Vaginal bleeding	Fertile	NR	Left	46, XX	12 x9x 7 cm	USO + paraaortic LND	Dysgerminoma	Chemotherapy
7	Esin et al. (13)	2011	15	Vaginal bleeding	No	NR	Left	46, XX	0.5 cm	USO	Dysgerminoma	None
8	Kanagal et al. (14)	2013	14	Abdominal distension	No	Elevated testosterone level	Left	46, XX	30x25x10 cm	USO + pelvic and para-aortic LND + infracolic omentectomy	Dysgerminoma	Chemotherapy
9	Kulkarni et al. (15)	2016	20	Abdominal pain	Fertile	NR	Left	46, XX	8x6x6 cm	USO + omental biopsy	Dysgerminoma	None
10	McCuaig et al. (16)	2017	20	Oligomenorrhea and menorrhagia	No	NR	Left	46, XX	2.5x2x1.5 cm	USO	Dysgerminoma	None
11	Roth et al. (17)	2019	9	Abdominal pain and a right adnexal mass	No	NR	Right	46, XX	8.9×5.7×5.2 cm	USO	Mixed germ cell tumor	Chemotherapy
12	Raafey et al. (18)	2020	10	Abdominal pain, abdominal distention and fever	No	NR	Left	46, XX	16x10x9 cm	USO	Dysgerminoma	Chemotherapy

Table 2. Continued

No	Author	Year	Age at diagnosis	Clinical presentation	Fertile status	Hormonal abnormalities	Laterality	Karyotype	Tumor size	Surgical procedure	Pathological findings in addition to gonadoblastoma	Adjuvant therapy
13	Chandrapattan et al. (19)	2022	9	Signs of virilization and contrasexual pubertal development	No	NR	Right	46, XX	15x10 cm	USO + pelvic LND + infracolic omentectomy	Dysgerminoma	Chemotherapy
14	Yin et al. (20)	2022	11	Abdominal pain	NR	Elevated FSH, LH, progesterone, 11-deoxycortisole, ACTH, corticosterone decreased cortisol, E2, testosterone	Right	46, XX, gonadal karyotype Y chromosome negative	10x8x6 cm	USO	Dysgerminoma	17a-hydroxylase /17,20-lyase deficiency Glucocorticoid replacement therapy
15	Present case	2024	14.6	Hirsutism	No	Elevated FSH, LH, total testosterone	Bilateral	46, XX *SRY* negative	3x1x0.5 cm (right) 2.7x1.5x3 cm (left) 0.5 cm (left) dysgerminoma	BSO	Bilateral gonadoblastoma and unilateral (left) dysgerminoma	None

BSO, bilateral salpingo-oophorectomy; USO, unilateral salpingo-oophorectomy; LND, lymph node dissection; TAH, total abdominal hysterectomy; NR, not report

Ethics

Informed Consent: Informed consent for publication was obtained from the patient's parents.

Footnotes

Authorship Contributions

Surgical and Medical Practices: Ozlem Dural, Ayca Dilruba Aslanger, Aysel Bayram, Semen Onder, Concept: Tugce Kandemir, Design: Tugce Kandemir, Data Collection or Processing: Tugce Kandemir, Esin Karakilic Ozturan, Analysis or Interpretation: Tugce Kandemir, Literature Search: Tugce Kandemir, Writing: Tugce Kandemir, Esin Karakilic Ozturan, Elif Inan Balci, Asli Derya Kardelen, Melek Yildiz, Sukran Poyrazoglu, Firdevs Bas, Feyza Darendeliler.

Conflict of Interest: One author of this article, Feyza Darendeliler, is a member of the Editorial Board of the Journal of Clinical Research in Pediatric Endocrinology. However, she did not involved in any stage of the editorial decision of the manuscript. The editors who evaluated this manuscript are from different institutions. The other authors declared no conflict of interest.

Financial Disclosure: The authors declared that this study received no financial support.

References

1. Scully RE. Gonadoblastoma; a gonadal tumor related to the dysgerminoma (seminoma) and capable of sex-hormone production. Cancer. 1953;6:455-463.
2. Kim M-J, Ahn H-J, Kim J-Y, Kim K-R. Gonadoblastoma overgrown by dysgerminoma in women with 46, XX karyotype. The Korean Journal of Pathology. 2003;37:66-70.
3. Pratt-Thomas HR, Cooper JM. Gonadoblastoma with tubal pregnancy. Am J Clin Pathol. 1976;65:121-125.
4. Ferrari MTM, Silva ESDN, Nishi MY, Batista RL, Mendonca BB, Domenice S. Testicular differentiation in 46,XX DSD: an overview of genetic causes. Front Endocrinol (Lausanne). 2024;15:1385901.
5. Costanzo M, Touzon MS, Marino R, Guercio G, Ramirez P, Mattone MC, Pérez Garrido N, Bailez MM, Vaiani E, Ciaccio M, Galluzzo Mutti ML, Belgorosky A, Berensztein E. Gonadal tumor development in 46,XX disorders of gonadal development. Eur J Endocrinol. 2022;187:451-462.
6. Looijenga LH, Hersmus R, Oosterhuis JW, Cools M, Drop SL, Wolffenbuttel KP. Tumor risk in disorders of sex development (DSD). Best Pract Res Clin Endocrinol Metab. 2007;21:480-495.
7. Obata NH, Nakashima N, Kawai M, Kikkawa F, Mamba S, Tomoda Y. Gonadoblastoma with dysgerminoma in one ovary and gonadoblastoma with dysgerminoma and yolk sac tumor in the contralateral ovary in a girl with 46XX karyotype. Gynecol Oncol. 1995;58:124-128.
8. Erhan Y, Toprak AS, Ozdemir N, Tiras B. Gonadoblastoma and fertility. J Clin Pathol. 1992;45:828-829.
9. Zhao S, Kato N, Endoh Y, Jin Z, Ajioka Y, Motoyama T. Ovarian gonadoblastoma with mixed germ cell tumor in a woman with 46, XX karyotype and successful pregnancies. Pathol Int. 2000;50:332-335.
10. Yilmaz B, Gungor T, Bayramoglu H, Soysal S, Mollamahmutoglu L. Bilateral ovarian gonadoblastoma with coexisting dysgerminoma in a girl with 46, XX karyotype. J Obstet Gynaecol Res. 2010;36:697-700.
11. Koo YJ, Chun YK, Kwon YS, Lee IH, Kim TJ, Lee KH, Lim KT. Ovarian gonadoblastoma with dysgerminoma in a woman with 46XX karyotype. Pathol Int. 2011;61:171-173.

12. Erdemoglu E, Ozen S. Ovarian gonodoblastoma with yolk sac tumor in a young 46, XX female: case report. Eur J Gynaecol Oncol. 2007;28:516-518.

13. Esin S, Baser E, Kucukozkan T, Magden HA. Ovarian gonadoblastoma with dysgerminoma in a 15-year-old girl with 46, XX karyotype: case report and review of the literature. Arch Gynecol Obstet. 2012;285:447-451. Epub 2011 Aug 31

14. Kanagal DV, Prasad K, Rajesh A, Kumar RG, Cherian S, Shetty H, Shetty PK. Ovarian Gonadoblastoma with Dysgerminoma in a Young Girl with 46, XX Karyotype: A Case Report. J Clin Diagn Res. 2013;7:2021-2022. Epub 2013 Aug 10

15. Kulkarni MM, Sinai Khandeparkar SG, Joshi AR, Bhayekar PV. Unilateral gonadoblastoma with dysgerminoma in normal fertile woman having a child: Extremely rare occurrence with characteristic immunohistomorphology. Indian J Pathol Microbiol. 2016;59:527-529.

16. McCuaig JM, Noor A, Rosen B, Casper RF, Mitri F, Colgan T, Kim RH. Case Report: Use of tumor and germline Y chromosomal analysis to guide surgical management in a 46, XX female presenting with gonadoblastoma with dysgerminoma. Int J Gynecol Pathol. 2017;36:466-470.

17. Roth LM, Davis MM, Czernobilsky B. Classic and “dissecting” gonadoblastoma in a phenotypic girl with a 46, XX peripheral karyotype and no evidence of a disorder of sex development. Int J Gynecol Pathol. 2019;38:581-587.

18. Raafey MA, Abdulwaasey M, Fatima SS, Uddin Z, Tariq MU. Bilateral gonadoblastoma with dysgerminoma in a phenotypically normal female with 46XX karyotype: report of a rare case and literature review. Cureus. 2020;12:e8990.

19. Chandrapattan P, Jena A, Patnayak R, Mangaraj S, Naik S, Panda S. Gonadoblastoma with dysgerminoma presenting as virilizing disorder in a young child with 46, XX karyotype: a case report and review of the literature. Case Rep Endocrinol. 2022;2022:5666957.

20. Yin M, Yang J, Tian Q, Zhang X. Ovarian gonadoblastoma with dysgerminoma in a girl with 46,XX karyotype 17a-hydroxylase/17, 20-lyase deficiency: A case report and literature review. Front Endocrinol (Lausanne). 2022;13:989695.

CASE REPORT

JCRPE Journal of Clinical Research in Pediatric Endocrinology

DOI: 10.4274/jcrpe.galenos.2024.2024-7-11
J Clin Res Pediatr Endocrinol 2026;18(Suppl 1):45-49

Permanent Neonatal Diabetes with High Insulin Requirements due to a New Variant in the *INS* Gene

Johana Andrea Botero Hernández[1], Gina González-Valencia[1], Vanessa Suarez[2], Gabriel del Castillo[2]

[1]University of Antioquia Faculty of Medicine, Department of Pediatric Endocrinology, Medellín, Colombia
[2]Fundación Hospital Infantil Los Ángeles, Clinic of Pediatric Endocrinology, Pasto, Nariño, Colombia

Cite this article as: Hernández JAB, González-Valencia G, Suarez V, del Castillo G. Permanent neonatal diabetes with high insulin requirements due to a new variant in the INS gene. J Clin Res Pediatr Endocrinol. 2026;18(Suppl 1):45-49

What is already known on this topic?

The three most frequent pathogenic variants that cause permanent neonatal diabetes involve the *ABCC8, KCNJ11,* and *INS* genes. The latter is responsible for 10-20% of cases and results in variable clinical behavior, associated with intrauterine growth restriction, maturity onset diabetes of youth-type diabetes, and permanent or transient neonatal diabetes.

What this study adds?

This study reports a novel pathogenic variant within the *INS* gene, not documented in databases. Unlike neonatal diabetes due to *ABCC8* and *KCNJ11* variants, the *INS*-related form does not respond to sulfonylurea treatment and requires insulin for glycemic control, posing a challenge for breastfeeding patients. This report further supports the need for a clinical approach motivated by early molecular diagnosis.

ABSTRACT

Neonatal diabetes is an infrequent disorder that may present as transient, permanent, or syndromic. It is most commonly caused by pathogenic variants involving the *ABCC8, KCNJ11,* and *INS* genes. This report describes a neonate with permanent diabetes mellitus due to a previously unreported variant in the *INS* gene, outlining the diagnostic complexities, therapeutic interventions, and related clinical challenges. The neonate with a history of symmetrical intrauterine growth restriction presented with severe hyperglycemia not associated with ketosis or infectious. He had high insulin requirements and did not respond to sulfonylurea management. Anti-insulin and anti-islet pancreatic antibodies were negative. Genetic sequencing revealed a homozygous missense variant (c.3G>A, p.Met1Ile) in *INS*, which had not been previously reported. Timely molecular diagnosis of neonatal diabetes enabled optimization of management strategies, mitigating the long-term impact on growth, neurodevelopment, and the occurrence of hypoglycemic episodes.

Keywords: Neonatal diabetes mellitus, newborn, insulin gene

Corresponding Author: Gina González-Valencia, University of Antioquia Faculty of Medicine, Department of Pediatric Endocrinology, Medellín, Colombia
E-mail: gina.gonzalezv@udea.edu.co **ORCID:** orcid.org/0009-0002-6547-8462
Conflict of interest: None declared.
Received: 05.08.2024 **Accepted:** 11.11.2024 **Epub:** 20.12.2024 **Publication Date:** 02.06.2026

©Copyright 2026 by Turkish Society for Pediatric Endocrinology and Diabetes / The Journal of Clinical Research in Pediatric Endocrinology published by Galenos Publishing House.
Licensed under a Creative Commons Attribution-NonCommercial-NoDerivatives 4.0 (CC BY-NC-ND) International License.

Introduction

Neonatal diabetes mellitus (NDM) is a rare genetic condition, with a prevalence ranging from 1/21,000 to 1/300,000 live births, varying by geographical location (1,2). In Europe, the prevalence is estimated to be between 1/90,000 to 1/300,000 live births (3). In regions with high consanguinity, such as the southeastern Anatolia region of Türkiye and the Middle East, the prevalence may increase to between 1/21,000 and 1/48,000 live births (1). The onset of NDM typically occurs within the first six months of life, although cases with later presentation, between 9 to 12 months, have been documented (2,3).

The diagnosis of NDM should be suspected when plasma glucose levels exceed 150-250 mg/dL, particularly after excluding other potential causes of hyperglycemia, including sepsis, low birth weight, or prematurity-associated complications, and medications such as phenytoin, glucocorticoids, ionotropic or high dextrose infusions (4,5,6). Autoimmune diabetes should also be ruled out through negative antibodies testing against glutamic acid decarboxylase, insulin, zinc transporter, and tyrosine phosphatase. A key biochemical feature of NDM is reduced levels of basal insulin and C-peptide (4,5).

To date, over 40 genes have been implicated in the pathogenesis of NDM, with different inheritance patterns. These genes affect insulin synthesis, action, and secretion by altering beta cell development (aplasia and pancreatic hypoplasia), increasing beta cell destruction by apoptosis or protein misfolding with consequent endoplasmic reticulum stress due to retained proteins, and altering beta cell membrane depolarization leading to failure to secrete synthesized insulin into the circulation (3). The three most frequently involved genes are *ABCC8*, *KCNJ11*, and *INS*. The latter is located on chromosome 11p15.5, is responsible for 6.7 to 18% of cases, and results in variable clinical behavior associated with intrauterine growth restriction (IUGR) and maturity onset diabetes of youth-type diabetes (1,7).

This report presents a case of NDM due to a novel pathogenic variant in the *INS* gene, with strikingly high insulin requirements. This report also highlights the role of molecular diagnostics in establishing timely and effective management.

Case Report

A male neonate, aged two days, was admitted to the neonatal unit. The patient's mother, aged 18 years, was experiencing her first pregnancy. The baby was delivered via Cesarean section at 35 weeks of gestation, with a birth weight of 1,310 grams, length of 44 cm, and a head circumference of 29 cm (length-for-age Z score -1.05, weight-for-age Z score -2.71, and head circumference-for-age Z score -2.27 by Intergrowth-21 standards) (8). There was no familial history of consanguinity.

The neonate initially demonstrated adequate adaptation but developed clinical deterioration within the first two days of life, which was characterized by severe anemia necessitating transfusion, intermittent sinus bradycardia with a normal echocardiogram, and persistent hyperglycemia with blood glucose levels reaching 574 mg/dL. After the exclusion of infectious etiologies, familial medical history, and medication-induced hyperglycemia, a diagnosis of NDM was considered. Notably, the early onset severe anemia was not attributable to this condition; occult perinatal blood loss was considered, although not documented, and other causes, including hemolysis and sepsis, were evaluated but not demonstrated.

The patient was initially managed with an intravenous insulin infusion at a rate of 0.07 U/kg/h. Subsequently, insulin Detemir was introduced at a maximum dose of 0.8 U/kg/every 12 hours, in conjunction with insulin Aspart administered in a flexible scheme. Due to the high prevalence of *ABCC8* and *KCNJ11* mutations in NDM, a therapeutic trial with sulfonylurea was conducted, but this yielded no improvement in glycemic control. Following sufficient weight gain, Detemir was replaced with insulin Glargine, and the patient continued with preprandial insulin Aspart, necessitating a progressive dose increase. He was discharged from the neonatal unit at three months of age, requiring 1.7 U/kg/day of insulin and has been followed up every 3-4 months. Insulin requirements have been variable (min. 0.726 U/kg/day-max. 1.26 U/kg/day). Improvement in his World Health Organization standard deviations for height was also documented [from -2.24 standard deviation (SD) at 3 months to -1.41 SD at 50 months].

His neurodevelopment has been normal, but at 2 years and 4 months, he experienced seizures not associated with hypoglycemia. An electroencephalogram detected an occipital focus of discharge, without morphological abnormalities. He has been treated with oxcarbazepine and has been seizure-free since the age of 2.

C-peptide levels were not measured due to the lack of availability of this assay in all regions of the country, as it requires external processing. Antibody testing for anti-insulin antibodies by enzyme immunoassay (0.8 U/m) and anti-pancreatic islet antibodies (0.5 U/m) was negative. Genetic testing was performed using a targeted clinical exome for neonatal diabetes, which identified a novel homozygous missense *INS* variant (c.3G>A, p.Met1Ile), classified as pathogenic according to American College of Medical Genetics and Genomics guidelines (NM_00101042376.3; rs397515521) Results were available at 12 months of age.

Discussion

Neonatal diabetes represents a heterogeneous group of monogenic disorders, with diverse clinical manifestations (3). Its symptoms are nonspecific and include tachypnea, lethargy,

irritability, dehydration, failure to thrive, polyuria, convulsions, or hypotonia (9). Biochemical alterations that suggest the diagnosis include glycosuria, ketonuria, and hyperketonemia (4). The diagnosis in this patient was suspected when persistent hyperglycemia and high insulin requirements were noted. As part of the study, antibodies against pancreatic islets were requested; unfortunately, we could only obtain islet cell cytoplasmic antibodies (against cytoplasmic proteins in the beta cell) and anti-insulin, which results were negative.

The three main genes involved in permanent neonatal diabetes are *KCNJ11*, *ABCC8*, and *INS*, all located on chromosome 11. Pathogenic variants in the first two genes are the most frequent, accounting for 30 to 50% of all cases, and are responsible for encoding the subunits of the ATP-sensitive potassium channels of the beta cell (2,7,10). Pathogenic variants in the *INS* gene are mostly *de novo*, and their diagnosis is usually made before six months of age (7). However, some publications, such as that of Ngoc et al. (7), report later ages of diagnosis of 9.7±1.9 months in up to 30% of cases.

Heterozygous missense variants in the *INS* gene have been associated with misfolding of the proinsulin molecule and consequently altered final insulin synthesis; these variants usually appear *de novo* in 80% of cases (3). Homozygous recessive pathogenic variants in this gene, as in our case, can impair insulin biosynthesis through mechanisms such as reduced mRNA stability, misfolding of proinsulin, and defective protein processing, leading to endoplasmic reticulum stress and β-cell apoptosis (2,3,7,9,11). Ngoc et al. (7) reported missense variants in exons 2, 3, and intronic region 2. In the present case, the location of the variant is in exon 2. It has been reported by *in silico* studies that the methionine residue at this position is at the start of protein translation, which is highly conserved between species and, therefore, supports its pathogenicity.

Other genes less frequently associated with neonatal diabetes are *SLC2A2*, *SLC19A2*, *EIF2AK3*, *GCK* (Glucokinase), *IPF1* (Insulin Promoting Factor), *PTF1A* (Pancreatic Transcription Factor Subunit 1 Alpha), *HNF1B* (Hepatocyte Nuclear Factor Homebox 1B), *FOXP3* (Forkhead Box P3), *ZFP57* (Zinc Finger Protein 57), *GLIS3* and *GATA6*. These genes should be considered in cases with a strong suspicion of NDM but with negative genetic studies for *KCNJ11*, *ABCC8* and *INS* variants (2,5,12).

Early genetic study is recommended when hyperglycemia persists longer than 2-3 weeks of life or when serum glucose levels greater than 1000 mg/dL are present without an apparent cause (5). In the present case, having hyperglycemia peaks higher than 500 mg/dL for more than two months of duration and high insulin requirements of up to 1.7 IU/kg/day made him a candidate for an early molecular study. However, his result was only available at around nine months of age.

Molecular testing by Next Generation Sequence or methylation-specific multiplex ligation-dependent probe amplification can provide a timely diagnosis to guide management and define prognosis (9,13). In the presented patient, since the results of the genetic panel were not available, a trial with sulfonylurea was performed, given that the most frequent cause of transient and permanent NDM involves the *KCNJ11* and *ABCC8* genes which are both responsive to treatment with sulfonylurea (3,13,14,15). The lack of response to treatment with oral medication suggested a different genetic etiology, which was corroborated by molecular testing.

Case series of patients with pathogenic variants for the *INS* gene report a higher prevalence of IUGR. This finding was corroborated in our patient by anthropometric data at birth. IUGR is a common feature and is explained by *in utero* insulin deficiency, which is directly related to prenatal growth (16,17,18,19). In the long term, patients with NDM due to *INS* may present a risk of low weight, as is the current case, or low height, for which it is important to optimize glycemic control (20).

Glycemic control and insulin management are a challenge in neonatal diabetes. Newborns have an irregular amount and frequency of food intake that makes glycemic control less stable. The use of continuous glucose monitoring has been described as a method to guide insulin management and maintain blood glucose values within the normal range for a longer time (21). In clinical studies, continuous glucose monitoring has been described as safe, although with some technical limitations due to the small subcutaneous area available for sensor application in newborns and infants, especially those with low weight or poor fat accumulation, as well as increased risk of infection at the application site and local skin reactions that can be minimized by rotating the sensor sites (20,21,22). Despite being a useful tool, its use in children under two years of age is not authorized in our country, which limited this patient's access to this technology. It would have been particularly beneficial, as the patient may have experienced inadvertent hypoglycemia suggested by low glycated hemoglobin levels that could not be detected by the blood glucometer used in this case.

Finally, in neonates it is recommended to start with preprandial short-acting subcutaneous insulin at doses of 0.1-0.15 IU/kg/dose or guided by the response to insulin infusion (22). In this case, it is striking the high doses of insulin required during the first months of life (up to 1.77 U/kg/d), but with a progressive decrease in the requirements, reaching a dose of 0.7 U/kg/d at 18 months of age. Studies such as the one carried out in the Vietnamese population report insulin requirements at lower doses, with the highest insulin need reported at 1.1 U/kg/d, and this may be due to either genetic variability and/or clinical heterogeneity (7).

Conclusion

Neonatal diabetes is a rare condition with transient, permanent, and syndromic presentations.

This case highlights the necessity of early molecular diagnostics, which can inform personalized therapeutic strategies and improve long-term outcomes. In resource-limited settings, increased access to genetic testing may uncover previously unidentified mutations, contributing to global genetic databases and advancing our understanding of this rare condition. In this case, the novel homozygous variant in the *INS* gene highlights the complexity of NDM and the importance of ongoing research to refine treatment protocols and improve quality of life for affected individuals.

Ethics

Informed Consent: Informed consent was obtained from the parents to authorize the publication of this case. It was submitted for review by the Ethics Committee of the Medical School of the Universidad de Antioquia, Medellín, Colombia.

Acknowledgements

We would like to thank the patient's family for participating in the study.

Footnotes

Authorship Contributions

Surgical and Medical Practices: Vanesa Suarez, Gabriel del Castillo, Concept: Johana Andrea Botero Hernández, Gina González-Valencia, Design: Johana Andrea Botero Hernández, Gina González-Valencia, Data Collection and Processing: Gina González-Valencia, Vanessa Suarez, Analysis or Interpretation: Johana Andrea Botero Hernández, Gina González-Valencia, Literature Search: Johana Andrea Botero Hernández, Gina González-Valencia, Writing: Johana Andrea Botero Hernández, Gina González-Valencia, Vanessa Suarez.

Financial Disclosure: The authors declared that this study received no financial support.

References

1. Abali ZY, De Franco E, Karakilic Ozturan E, Poyrazoglu S, Bundak R, Bas F, Flanagan SE, Darendeliler F. Clinical characteristics, molecular features, and long-term follow-up of 15 patients with neonatal diabetes: a single-centre experience. Horm Res Paediatr. 2020;93:423-432. Epub 2021 Jan 26
2. Jahnavi S, Poovazhagi V, Mohan V, Bodhini D, Raghupathy P, Amutha A, Suresh Kumar P, Adhikari P, Shriraam M, Kaur T, Das AK, Molnes J, Njolstad PR, Unnikrishnan R, Radha V. Clinical and molecular characterization of neonatal diabetes and monogenic syndromic diabetes in Asian Indian children. Clin Genet. 2013;83:439-445. Epub 2012 Aug 20
3. Kocova M. Genetic spectrum of neonatal diabetes. Balkan J Med Genet. 2021;23:5-15. eCollection 2020 Nov
4. De León DD, Pinney SE. Permanent neonatal diabetes mellitus. 2008 Feb 8 [updated 2025 Sep 25]. In: Adam MP, Bick S, Mirzaa GM, Pagon RA, Wallace SE, Amemiya A, editors. GeneReviews®[Internet]. Seattle (WA): University of Washington, Seattle; 1993-2026.
5. Lemelman MB, Letourneau L, Greeley SAW. Neonatal diabetes mellitus: an update on diagnosis and management. Clin Perinatol. 2018;45:41-59. Epub 2017 Dec 16
6. Balasundaram P, Shah M. Neonatal hyperglycemia. 2025 Dec 13. In: StatPearls [Internet]. Treasure Island (FL): StatPearls Publishing; 2026 Jan-.
7. Ngoc CTB, Dung VC, De Franco E, Lan NN, Thao BP, Khanh NN, Flanagan SE, Craig ME, Hoang NH, Dien TM. Genetic Etiology of neonatal diabetes mellitus in Vietnamese infants and characteristics of those with *INS* gene mutations. Front Endocrinol (Lausanne). 2022;13:866573.
8. Papageorghiou AT, Ohuma EO, Altman DG, Todros T, Cheikh Ismail L, Lambert A, Jaffer YA, Bertino E, Gravett MG, Purwar M, Noble JA, Pang R, Victora CG, Barros FC, Carvalho M, Salomon LJ, Bhutta ZA, Kennedy SH, Villar J; International Fetal and Newborn Growth Consortium for the 21st Century (INTERGROWTH-21st). International standards for fetal growth based on serial ultrasound measurements: the Fetal Growth Longitudinal Study of the INTERGROWTH-21st Project. Lancet. 2014;384:869-879. Erratum in: Lancet. 2014;384:1264.
9. Dahl A, Kumar S. Recent advances in neonatal diabetes. Diabetes Metab Syndr Obes. 2020;13:355-364.
10. Ngoc CTB, Dien TM, De Franco E, Ellard S, Houghton JAL, Lan NN, Thao BP, Khanh NN, Flanagan SE, Craig ME, Dung VC. Molecular genetics, clinical characteristics, and treatment outcomes of K_{ATP}-channel neonatal diabetes mellitus in Vietnam National Children's Hospital. Front Endocrinol (Lausanne). 2021;12:727083.
11. Demiral M, Demirbilek H, Çelik K, Okur N, Hussain K, Ozbek MN. Neonatal diabetes due to homozygous INS gene promoter mutations: Highly variable phenotype, remission and early relapse during the first 3 years of life. Pediatr Diabetes. 2020;21:1169-1175. Epub 2020 Aug 7
12. Zübarioğlu AU. Neonatal diabetes mellitus. Med Bull Sisli Etfal Hosp. 2018 [cited 2022 Sep 29]; Available from: https://www.journalagent.com/sislietfaltip/pdfs/SETB_52_2_71_78.pdf
13. Ali Khan I. Do second generation sequencing techniques identify documented genetic markers for neonatal diabetes mellitus? Heliyon. 2021;7:e07903.
14. Li M, Han X, Ji L. Clinical and genetic characteristics of *ABCC8* nonneonatal diabetes mellitus: a systematic review. J Diabetes Res. 2021;2021:9479268.
15. Støy J, Steiner DF, Park SY, Ye H, Philipson LH, Bell GI. Clinical and molecular genetics of neonatal diabetes due to mutations in the insulin gene. Rev Endocr Metab Disord. 2010;11:205-215.
16. Garin I, Edghill EL, Akerman I, Rubio-Cabezas O, Rica I, Locke JM, Maestro MA, Alshaikh A, Bundak R, del Castillo G, Deeb A, Deiss D, Fernandez JM, Godbole K, Hussain K, O'Connell M, Klupa T, Kolouskova S, Mohsin F, Perlman K, Sumnik Z, Rial JM, Ugarte E, Vasanthi T; Neonatal Diabetes International Group; Johnstone K, Flanagan SE, Martínez R, Castaño C, Patch AM, Fernández-Rebollo E, Raile K, Morgan N, Harries LW, Castaño L, Ellard S, Ferrer J, Perez de Nanclares G, Hattersley AT. Recessive mutations in the INS gene result in neonatal diabetes through reduced insulin biosynthesis. Proc Natl Acad Sci U S A. 2010;107:3105-3110. Epub 2010 Jan 28
17. Hughes AE, Hattersley AT, Flanagan SE, Freathy RM. Two decades since the fetal insulin hypothesis: what have we learned from genetics? Diabetologia. 2021;64:717-726. Epub 2021 Feb 11
18. Hammoud B, Greeley SAW. Growth and development in monogenic forms of neonatal diabetes. Curr Opin Endocrinol Diabetes Obes. 2022;29:65-77.
19. Aguilar-Bryan L, Bryan J. Neonatal diabetes mellitus. Endocr Rev. 2008;29:265-291. Epub 2008 Apr 24

20. Rabbone I, Barbetti F, Marigliano M, Bonfanti R, Piccinno E, Ortolani F, Ignaccolo G, Maffeis C, Confetto S, Cerutti F, Zanfardino A, Iafusco D. Successful treatment of young infants presenting neonatal diabetes mellitus with continuous subcutaneous insulin infusion before genetic diagnosis. Acta Diabetol. 2016;53:559-565. Epub 2016 Feb 1

21. Beardsall K, Thomson L, Guy C, Iglesias-Platas I, van Weissenbruch MM, Bond S, Allison A, Kim S, Petrou S, Pantaleo B, Hovorka R, Dunger D; REACT collaborative. Real-time continuous glucose monitoring in preterm infants (REACT): an international, open-label, randomised controlled trial. Lancet Child Adolesc Health. 2021;5:265-273. Epub 2021 Feb 10

22. Kim MS, Kim SE, Lee NY, Kim SK, Kim SH, Cho WK, Cho KS, Jung MH, Suh BK, Ahn MB. Transient neonatal diabetes mellitus managed with continuous subcutaneous insulin infusion (CSII) and continuous glucose monitoring. Neonatal Med. 2021;28:41-47.

CASE REPORT

JCRPE Journal of Clinical Research in Pediatric Endocrinology

DOI: 10.4274/jcrpe.galenos.2024.2024-8-9
J Clin Res Pediatr Endocrinol 2026;18(Suppl 1):50-53

A Novel *SRD5A2* Loss-of-Function Variant in a Chinese Child with 5α-reductase Type 2 Deficiency

Peng Zhou[1,2], Juanjuan Lyu[1,2], Xiaomei Sun[1,2], Ying Liu[1,2], Chuanjie Yuan[1,2], Jin Wu[1,2]

[1]Sichuan University, West China Second University Hospital, Department of Pediatrics, Chengdu, China
[2]Sichuan University, West China Second University Hospital, Key Laboratory of Birth Defects and Related Diseases of Women and Children, Ministry of Education, Chengdu, China

Cite this article as: Zhou P, Lyu J, Sun X, Liu Y, Yuan J, Wu J. A novel *SRD5A2* loss-of-function variant in a Chinese child with 5α-reductase type 2 deficiency. J Clin Res Pediatr Endocrinol. 2026;18(Suppl 1):50-53

What is already known on this topic?

Variants in the *SRD5A2* gene can lead to 5-alpha-reductase type 2 (5α-RD2) deficiency, a condition categorized under differences/disorders of sex development (DSD). An elevated testosterone/dihydrotestosterone ratio following human chorionic gonadotropin stimulation is a key diagnostic indicator of 5α-RD2 deficiency.

What this study adds?

This study reports a newly identified compound heterozygous variant in *SRD5A2* that caused 5α-RD2 deficiency in a Chinese child. The findings expand the spectrum of known *SRD5A2* variants associated with 5α-RD2 deficiency. Notably, the child presented with atypical external genitalia, including hypertrophy of the labioscrotal folds, which should prompt consideration of DSD in similar cases. The study also highlights the importance of genetic testing, including copy number variation analysis, for accurate diagnosis and genetic counseling in DSD cases.

ABSTRACT

Differences or disorders of sex development (DSD) represent a range of congenital conditions that lead to discrepancies among a person's sex chromosomes, gonads, and anatomical sex. Variants in the *SRD5A2* gene can lead to 5-alpha-reductase type 2 (5α-RD2) deficiency, a condition within the DSD spectrum. Here, we report a case of 5α-RD2 deficiency in a Chinese child, resulting from a newly identified compound heterozygous variant in *SRD5A2*. The proband, a 2-month-old child assigned female at birth, was initially observed to have bilateral hypertrophy of the labial folds during routine child healthcare visits at a local hospital. An ultrasound scan revealed testicular structures on both sides of the

Corresponding Author: Jin Wu, MD, PhD, Sichuan University, West China Second University Hospital, Department of Pediatrics, Chengdu, China
E-mail: wangdo620@163.com **ORCID:** orcid.org/0000-0002-6721-5431
Conflict of interest: None declared
Received: 27.08.2024 **Accepted:** 12.12.2024 **Publication Date:** 02.06.2026

©Copyright 2026 by Turkish Society for Pediatric Endocrinology and Diabetes / The Journal of Clinical Research in Pediatric Endocrinology published by Galenos Publishing House.
Licensed under a Creative Commons Attribution-NonCommercial-NoDerivatives 4.0 (CC BY-NC-ND) International License.

labial folds. The testosterone/dihydrotestosterone ratio after stimulation was 37, consistent with 5α-RD2 deficiency. Whole-exome sequencing and copy number variation analysis identified a novel compound heterozygous variant in *SRD5A2*, consisting of a 175.06 Kb deletion (including exon 1) located at chr2:31802204-31977267 and a c.607G>A (p.G203S) point mutation. Cytogenetic analysis confirmed a 46,XY karyotype. This case highlights a previously unreported compound heterozygous variant in *SRD5A2* associated with 5α-RD2 deficiency in a Chinese child.

Keywords: 5α-reductase type 2 deficiency, *SRD5A2*, disorders of sex development (DSD), gene deletion

Introduction

Differences or disorders of sex development (DSD) are a range of congenital conditions characterized by discrepancies among a person's sex chromosomes, gonads, and/or anatomical sex. Individuals with DSD who have a 46,XY karyotype are commonly referred to as having 46,XY DSD (1). It is estimated that 7% to 25% of individuals with 46,XY DSD receive a diagnosis with 5-alpha-reductase type 2 (5α-RD2) deficiency (2).

Individuals affected by 5α-RD2 deficiency exhibit a wide spectrum of genital ambiguity, ranging from mild under-virilization in males to completely female external genitalia. Common clinical features include clitoromegaly, hypospadias, micropenis, and cryptorchidism. The severity of these phenotypes is largely determined by the extent of retained SRD5A2 enzyme activity (3).

The prevalence of 5α-RD2 deficiency in the general population remains unknown, but over 180 different variants of the *SRD5A2* gene have been documented to date (3). As genetic analysis becomes more accessible, an increasing number of genetic factors contributing to 5α-RD2 deficiency are being reported. Herein, we present a child of Chinese origin with 5α-RD2 deficiency, in whom genetic analysis revealed a compound heterozygous variant. This included a newly identified 175.06 Kb deletion (encompassing exon 1) located at chr2:31802204-31977267, which was identified as pathogenic, alongside a c.607G>A (p.G203S) variant, also classified as pathogenic in *SRD5A2*.

Case Report

The proband, a child of Chinese origin, presented at two months of age for routine child healthcare evaluation at a local hospital. During the examination, bilateral hypertrophy of the labioscrotal folds was noted. An ultrasound scan performed at that time revealed testicular and epididymal structures on both sides of the labioscrotal folds. The child had exhibited no symptoms of vomiting, diarrhea, poor weight gain, or dehydration since birth. Subsequently, the proband was referred to our hospital for further diagnostic evaluation and management.

On physical examination, the child assigned female gender at birth had a height measured at an standard deviation score (SDS) of -0.05, and a weight measured at an SDS of 0.91. The proband presented with bilateral hypertrophy of the labial folds. Palpable masses, approximately 1.0 cm×0.5 cm×0.5 cm in size, were identified on both sides of the labial folds. The clitoris was slightly enlarged, with no visible vaginal opening or pigmentation. The External Genital Masculinization Score (EMS) was assessed as 3/12 points with a score of 12 indicating fully masculinized external genitalia, with both gonads located in the labial folds.

Laboratory investigations revealed the following hormone levels: follicle-stimulating hormone 2.2 U/L, luteinizing hormone 3.3 U/L (Reference range: <0.1 U/L), total testosterone (T) 2.28 ng/mL (Reference range: <0.89 ng/mL), estradiol <11.8 pg/mL, androstenedione 1.61 ng/mL, dehydroepiandrosterone sulfate 24.40 µg/dL, anti-Müllerian hormone >18.00 ng/mL, inhibin B 327.54 pg/mL, adrenocorticotropic hormone 33.00 pg/mL, prolactin 16.4 ng/mL, and progesterone 0.97 ng/mL. Notably, the serum testosterone level was elevated during the mini-puberty phase.

The T/dihydrotestosterone (T/DHT) ratio after human chorionic gonadotropin (hCG) stimulation test was 37, as shown in Table 1, strongly suggesting 5α-RD2 deficiency. Additional laboratory evaluations, including thyroid function and electrolyte levels, were all within normal ranges.

Ultrasound examination of the labial folds identified potential testicular tissue measuring 1.4 cm×0.6 cm×0.7 cm on the right and 1.1 cm×0.5 cm×0.5 cm on the left. Pelvic magnetic resonance imaging (MRI) revealed abnormal signal nodules in the right labial folds and left inguinal region, with no ovarian, uterine, or vaginal structures observed. Cytogenetic analysis confirmed a 46,XY karyotype, with normal results for the *Sex-determining Region Y (SRY)* gene and Y chromosome microdeletions.

Whole-exome sequencing and copy number variation analysis conducted on the child and both parents revealed a compound heterozygous variant in the *SRD5A2* gene. The proband inherited the c.607G>A (p.G203S) variant from the mother, while the novel 175.06 Kb deletion (including exon 1) variant located at

Table 1. Results of the hCG stimulation test

	Pre-hCG	Day-3 post-hCG
Testosterone (pg/mL)	1670	10060
Dihydrotestosterone (pg/mL)	163.00	270.24

hCG: human chorionic gonadotropin

J Clin Res Pediatr Endocrinol
2026;18(Suppl 1):50-53

chr2:31802204-31977267 was inherited from the father, who carried a slightly smaller 174.9 Kb deletion (including exon 1) located at chr2:31802326-31977379 (Figure 1). Based on the guidelines from American College of Medical Genetics and Genomics (ACMG), the c.607G>A (p.G203S) variant was classified as pathogenic with evidence levels PS3_Supporting+PM1+PM3_ VeryStrong+ PP3, and the novel 175.06 Kb deletion was similarly identified as pathogenic, supported by evidence levels PVS1+PM3+PM2_ Supporting. These findings confirmed the diagnosis of 5α-RD2 deficiency. Following the final diagnosis of 5α-RD2 deficiency, the parents expressed a need for time to consider the sex assignment and available treatment options.

Discussion

5α-RD2 deficiency was first described in 1974 in studies involving individuals from the Dominican Republic and Dallas, Texas, USA (4,5). The *SRD5A2* gene, which is located on chromosome 2p23, consists of five exons and four introns, with variants identified across all exons. Exons 1 and 4 have been identified as mutation hotspots (3), and exon 3 has also been suggested as a hotspot in studies involving the Turkish population (6,7). In the presented case, the variant c.607G>A (p.G203S) is located in exon 4, while the novel 175.06 Kb deletion includes exon 1.

This case report describes an infant with female external genitalia (EMS=3) and bilateral hypertrophy of the labial folds, where masses were palpable on both sides of the labial folds.

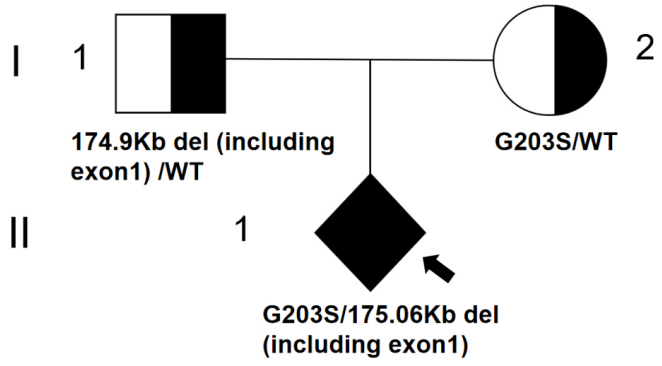

Figure 1. Pedigree diagram of the family. Circles represent females, and squares represent males. Half-shaded symbols indicate unaffected heterozygous carriers, and solid symbols represent affected individuals. The proband, subject II-1 (indicated by the arrow), was compound heterozygous for the *SRD5A2* gene, carrying both a novel 175.06 Kb deletion (including exon 1) variant located in chr2:31802204-31977267 and the c.607G>A (p.G203S) variant. The unaffected father (I-1) was heterozygous for a novel 174.9 Kb deletion (including exon 1) variant located in chr2:31802326-31977379, and the unaffected mother (I-2) was heterozygous for the G203S variant.

Ultrasound examination also revealed potential testicular tissue in the labial folds, resulting in a DSD diagnosis. Cytogenetic testing verified a 46,XY karyotype, consistent with a diagnosis of 46,XY DSD. This condition can be broadly categorized into two groups: sex determination disorders marked by abnormal gonadal development, and sex differentiation disorders marked by abnormal production or response to male hormones (8). In this case, the patient exhibited high testosterone levels during mini-puberty, and MRI confirmed the presence of testicles without the presence of ovaries or a uterus, effectively ruling out gonadal dysgenesis and testosterone synthesis disorders. To differentiate 5α-RD2 deficiency, the hCG test demonstrates higher diagnostic sensitivity than the initial plasma T/DHT ratio. A stimulated T/DHT ratio of ≥8.5 provides optimal sensitivity for diagnosing this condition during minipuberty (6). Given the elevated T/DHT ratio of 37 following hCG stimulation, 5α-RD2 deficiency was strongly suspected. Whole-exome sequencing and copy number variation analysis ultimately identified a compound heterozygous variant in *SRD5A2*, including the novel 175.06 Kb deletion (encompassing exon 1) and the c.607G>A (p.G203S) variant, both classified as pathogenic by ACMG criteria. The final diagnosis of 5α-RD2 deficiency was thus confirmed.

The 5α-reductase type 2 enzyme, encoded by *SRD5A2*, is a protein composed of 254 amino acids, featuring an androgen-binding domain at the N-terminal and an NADPH cofactor-binding domain at the C-terminal. This enzyme catalyzes the conversion of testosterone into DHT, an androgen with greater potency, which is crucial for the proper development of male external genitalia, the prostate, and the urethra (3). Delayed diagnosis of 5α-RD2 deficiency is common, especially in cases where the phenotype presents as female external genitalia. Early diagnosis is essential for sex of rearing, quality of life, future sexual function and fertility (1). In our case, the proband's atypical genital presentation, including hypertrophy of the labial folds, raised suspicion of DSD, warranting investigation.

In this patient, the c.607G>A (p.G203S) missense variant was identified as pathogenic based on ACMG guidelines and is known to be associated with reduced enzyme activity, with *in vitro* functional assays showing a 60% reduction (3). This variant is considered a potential founder mutation within the Chinese cohort (2). The second variant, a novel 175.06 Kb deletion (encompassing exon 1), also classified as pathogenic, has not been previously reported in association with 5α-RD2 deficiency. A compound heterozygous mutation, involving c.146C>A and a smaller 10 Kb deletion encompassing exon 1, was reported in two siblings with 5α-RD2 deficiency, who exhibited female external genitalia along with testes located bilaterally in the inguinal region at birth, consistent with our case (9). However, the deletion identified in our case was significantly larger.

This size difference makes the genomic alteration found in our patient unique and suggests potential implications for the phenotypic variability observed in 5α-RD2 deficiency. Our findings highlight the need for further genetic investigations in this condition, which may enhance the understanding of the genotype-phenotype correlation in affected individuals.

While our findings contribute to the expanding spectrum of *SRD5A2* mutations associated with 5α-RD2 deficiency, this case also highlights the limitations of our current understanding. Functional assays were not conducted to validate the pathogenic potential of the novel deletion, which represents a limitation of this study. Future research should focus on functional assays to elucidate the specific effects of these variants on enzyme activity and phenotype expression.

Conclusion

We describe a newly identified compound heterozygous variant in the *SRD5A2* gene, consisting of a 175.06 Kb deletion including all of exon 1 and the previously reported c.607G>A (p.G203S) variant, in a Chinese child with 5α-RD2 deficiency. This case report also reinforces the importance of considering DSD in children presenting with atypical external genitalia, such as hypertrophy of the labial folds, and highlights the critical role of genetic testing including copy number variation analysis in confirming the diagnosis. Early identification and diagnosis of 5α-RD2 deficiency are essential for appropriate management and counseling. Our findings contribute to the growing body of evidence regarding the genetic underpinnings of DSD and emphasize the need for further research to understand the functional impact of these variants. Future studies should focus on elucidating the mechanisms by which these genetic alterations affect enzyme function and contribute to the phenotype, ultimately improving the diagnosis and management of 5α-RD2 deficiency in diverse populations.

Ethics

Informed Consent: Informed consent was obtained from the parents to authorize the publication of this case.

Acknowledgements

We would like to thank the family who participated in the study.

Footnotes

Authorship Contributions

Surgical and Medical Practices: Peng Zhou, Juanjuan Lyu, Xiaomei Sun, Ying Liu, Chuanjie Yuan, Jin Wu, Concept: Peng Zhou, Juanjuan Lyu, Xiaomei Sun, Ying Liu, Chuanjie Yuan, Jin Wu, Design: Peng Zhou, Juanjuan Lyu, Xiaomei Sun, Ying Liu, Chuanjie Yuan, Jin Wu, Data Collection and Processing: Peng Zhou, Juanjuan Lyu, Xiaomei Sun, Ying Liu, Chuanjie Yuan, Jin Wu, Analysis or Interpretation: Peng Zhou, Juanjuan Lyu, Xiaomei Sun, Ying Liu, Chuanjie Yuan, Jin Wu, Literature Search: Peng Zhou, Juanjuan Lyu, Xiaomei Sun, Ying Liu, Chuanjie Yuan, Jin Wu, Writing: Peng Zhou, Juanjuan Lyu, Xiaomei Sun, Ying Liu, Chuanjie Yuan, Jin Wu.

Financial Disclosure: The authors declared that this study received no financial support.

References

1. Wisniewski AB, Batista RL, Costa EMF, Finlayson C, Sircili MHP, Dénes FT, Domenice S, Mendonca BB. Management of 46,XY differences/disorders of sex development (DSD) throughout life. Endocr Rev. 2019;40:1547-1572.
2. Gui B, Song Y, Su Z, Luo FH, Chen L, Wang X, Chen R, Yang Y, Wang J, Zhao X, Fan L, Liu X, Wang Y, Chen S, Gong C. New insights into 5α-reductase type 2 deficiency based on a multi-centre study: regional distribution and genotype-phenotype profiling of *SRD5A2* in 190 Chinese patients. J Med Genet. 2019;56:685-692. Epub 2019 Jun 11
3. Seo J, Shin S, Kim SW, Kim SJ, Lee M, Song K, Suh J, Lee ST, Lee YS, Chae HW, Kim HS, Choi JR, Han S, Kwon A. The genotype-phenotype correlation in human 5α-reductase type 2 deficiency: classified and analyzed from a SRD5A2 structural perspective. Int J Mol Sci. 2023;24:3297.
4. Imperato-McGinley J, Guerrero L, Gautier T, German JL, Peterson RE. Steroid 5alpha-reductase deficiency in man. An inherited form of male pseudohermaphroditism. Birth Defects Orig Artic Ser. 1975;11:91-103.
5. Walsh PC, Madden JD, Harrod MJ, Goldstein JL, MacDonald PC, Wilson JD. Familial incomplete male pseudohermaphroditism, type 2. Decreased dihydrotestosterone formation in pseudovaginal perineoscrotal hypospadias. N Engl J Med. 1974;291:944-949.
6. Abacı A, Çatlı G, Kırbıyık Ö, Şahin NM, Abalı ZY, Ünal E, Şıklar Z, Mengen E, Özen S, Güran T, Kara C, Yıldız M, Eren E, Nalbantoğlu Ö, Güven A, Çayır A, Akbaş ED, Kor Y, Çürek Y, Aycan Z, Baş F, Darcan Ş, Berberoğlu M. Genotype-phenotype correlation, gonadal malignancy risk, gender preference, and testosterone/dihydrotestosterone ratio in steroid 5-alpha-reductase type 2 deficiency: a multicenter study from Turkey. J Endocrinol Invest. 2019;42:453-470. Epub 2018 Aug 21
7. Akcay T, Fernandez-Cancio M, Turan S, Güran T, Audi L, Bereket A. AR and SRD5A2 gene mutations in a series of 51 Turkish 46,XY DSD children with a clinical diagnosis of androgen insensitivity. Andrology. 2014;2:572-578. Epub 2014 Apr 16
8. Bertelloni S, Tyutyusheva N, Valiani M, D'Alberton F, Baldinotti F, Caligo MA, Baroncelli GI, Peroni DG. Disorders/differences of sex development presenting in the newborn with 46,XY karyotype. Front Pediatr. 2021;9:627281.
9. Kocova M, Plaseska-Karanfilska D, Noveski P, Kuzmanovska M. Novel genotype in two siblings with 5α-reductase 2 deficiency: different clinical course due to the time of diagnosis. Balkan J Med Genet. 2019;22:69-76.

CASE REPORT

JCRPE Journal of Clinical Research in Pediatric Endocrinology

DOI: 10.4274/jcrpe.galenos.2024.2024-10-5
J Clin Res Pediatr Endocrinol 2026;18(Suppl 1):54-58

A Rare Cause of Neonatal Salt Wasting Syndrome: Clinical Management of a Case Diagnosed with Pseudohypoaldosteronism due to a Novel Homozygous Variant in the *SCNN1B* Gene

Berna Singin[1], Zeynep Donbaloğlu[1], Ebru Barsal Çetiner[1], Kürşat Çetin[1], Nurten Özkan Zarif[2], Kıymet Çelik[2], Ercan Mıhçı[3], Özden Altıok Clark[4], Hale Tuhan[1], Mesut Parlak[1]

[1]Akdeniz University Hospital, Department of Pediatric Endocrinology, Antalya, Türkiye
[2]Akdeniz University Hospital, Department of Neonatology, Antalya, Türkiye
[3]Akdeniz University Hospital, Department of Pediatric Genetics, Antalya, Türkiye
[4]Akdeniz University Hospital, Department of Medical Genetics, Antalya, Türkiye

Cite this article as: Singin B, Donbaloğlu Z, Barsal Çetiner E, Çetin K, Özkan Zarif N, Çelik K, Mıhçı E, Altıok Clark Ö, Tuhan H, Parlak M. A rare cause of neonatal salt wasting syndrome: clinical management of a case diagnosed with pseudohypoaldosteronism due to a novel homozygous variant in the *SCNN1B* gene. J Clin Res Pediatr Endocrinol. 2026;18(Suppl 1):54-58

What is already known on this topic?

Pseudohypoaldosteronism is a rare, salt-wasting syndrome characterized by marked resistance to aldosterone in peripheral target tissues. Differentiating between various adrenal insufficiencies is crucial because the treatment approaches differ. In addition, patient adherence can be challenging due to the necessity of taking large amounts of oral medications.

What this study adds?

This article outlines our experience treating a patient with pseudohypoaldosteronism caused by an *SCNN1B* variant, emphasizing the difficulties faced in clinical management. In the present case, a homozygous variant c.1234dup (p.Glu412Glyfs*39) was identified in exon 8 of the *SCNN1B* gene. This variant has not been previously reported.

Corresponding Author: Mesut Parlak, MD, Akdeniz University Hospital, Department of Pediatric Endocrinology, Antalya, Türkiye
E-mail: mesutparlak@akdeniz.edu.tr **ORCID:** orcid.org/0000-0002-3550-1425
Conflict of interest: None declared.
Received: 11.10.2024 **Accepted:** 12.12.2024 **Epub:** 26.12.2024 **Publication Date:** 02.06.2026

©Copyright 2026 by Turkish Society for Pediatric Endocrinology and Diabetes / The Journal of Clinical Research in Pediatric Endocrinology published by Galenos Publishing House.
Licensed under a Creative Commons Attribution-NonCommercial-NoDerivatives 4.0 (CC BY-NC-ND) International License.

ABSTRACT

Pseudohypoaldosteronism (PHA) is a rare disorder that, if not promptly recognized and treated, can lead to life-threatening hyperkalemia resulting in cardiac arrest and death. Systemic PHA is caused by variants that deactivate the epithelial sodium channel subunits. Management is challenging due to high-dose oral replacement therapy, and patients with systemic PHA require lifelong treatment. Here, we present the clinical course of a newborn diagnosed with PHA at seven days of age due to severe dehydration, inadequate feeding, vomiting, and lethargy. The infant was found to be homozygous for the variant c.1234dup (p.Glu412Glyfs*39) in exon 8 of the *SCNN1B* gene. The patient had multiple hospitalizations during follow-up and died at the age of 10 months due to pneumonia. Maintaining a high clinical suspicion for PHA is crucial for initiating treatment and preventing potential cardiac arrest and death in these patients. Further research is needed to determine the significance of such novel mutations in this disease.

Keywords: Systemic pseudohypoaldosteronism, hyponatremia, hyperkalemia, salt wasting, sodium polystyrene sulfonate, calcium polystyrene sulfonate

Introduction

Pseudohypoaldosteronism (PHA) is a rare, salt-wasting syndrome characterized by marked resistance to aldosterone in peripheral target tissues. There are two main types of PHA: type 1 PHA and type 2 PHA. Type 1 PHA may be inherited in an autosomal dominant (AD) or autosomal recessive (AR) manner. The AD form (renal form) is associated with mutations affecting the mineralocorticoid receptor (MR) in principal cells of the kidney, affecting sodium transport. The AR form (systemic form), on the other hand, is linked to mutations in the epithelial sodium channel (ENaC), expressed in various organs including renal tubules, lungs, colon, sweat glands, and salivary glands, which can exacerbate the severity of this form (1). The systemic form, which requires lifelong management, tends to have a more severe course while the renal form often improves within the first two years of life. Type 1 PHA typically presents with symptoms of salt wasting, growth retardation, hyperkalemia, and acidosis, similar to those seen in infants diagnosed with congenital adrenal hyperplasia (CAH) (2). Decreased sodium reabsorption from epithelial cells and the cortical collecting duct leads to volume depletion, thereby reducing the electrochemical gradient that normally supports potassium and hydrogen ion secretion. Besides renal dysfunction, the systemic form of Type 1 PHA is also associated with respiratory tract infections and a positive sweat test (3). Type 2 PHA, known as Gordon syndrome or familial hyperkalemic hypertension, is characterized by hypertension, hyperkalemia, metabolic acidosis, normal kidney function, low-normal plasma renin activity, and aldosterone concentration (4). Type 2 PHA exhibits AD inheritance.

This article discusses our experience in managing a patient with PHA due to an *SCNN1B* variant, highlighting the challenges encountered in clinical management.

Case Report

A 7-day-old female infant, born via repeat cesarean section from the second pregnancy of a 23-year-old mother, presented to the hospital with symptoms of vomiting, pallor, lethargy, poor feeding, and sleepiness. The infant was born at term, weighing 3500 grams (between the 50th and 90th percentile), with a length of 51 cm (50th percentile) and a head circumference of 36 cm (50th percentile). Due to the findings of hyponatremia and hyperkalemia upon initial evaluation, a preliminary diagnosis of CAH was considered, prompting referral to our center. There is a history of consanguinity (second-degree cousins) between the mother and father. The infant has a healthy 3.5-year-old male sibling.

On physical examination, her general condition was fair to poor, with altered skin turgor and milia and pustular erythematous rash on her face and neck. There were no ambiguous genitalia or hyperpigmentation noted. Examination of other systems was unremarkable. The patient's laboratory test results are shown in Table 1. Venous blood gas analysis showed a pH of 7.36, bicarbonate (HCO_3) of 11.5 mmol/L, and base excess (BE) of -11.3 mmol/L. Due to hyperkalemia, the patient was started on appropriate fluid therapy and received treatments including calcium gluconate, glucose-insulin infusion, $NaHCO_3$ infusion, and inhaled salbutamol. A 25-mg loading dose of IV hydrocortisone was administered, followed by 5 mg of IV stress dosing every 6 hours. In addition, fludrocortisone 0.1 mg twice daily was initiated. However, despite these interventions, the patient's hyperkalemia and hyponatremia remained resistant. Oral calcium polystyrene sulfonate at a dose of 1 g/kg/day and oral salt supplementation (4x1 g/day) were gradually increased. Laboratory findings upon admission to our clinic included spot urine analysis showed sodium levels of 156 mEq/L (normal range: 54-150 mEq/L) and potassium levels of 3.5 mEq/L (normal range: 6.7-21.3 mEq/L) concurrent with serum sodium of 118 mmol/L and potassium of 9.8 mmol/L. The calculated transtubular potassium gradient was low. Based on these laboratory results, hydrocortisone therapy was halted. Fludrocortisone therapy was continued but did not provide benefit. Considering the patient's presentation in the neonatal period, laboratory findings of hyponatremia and hyperkalemia with increased urinary sodium excretion, elevated aldosterone levels, and normal blood pressure, systemic PHA was suspected. Secondary PHA

J Clin Res Pediatr Endocrinol
2026;18(Suppl 1):54-58

Table 1. Patient's laboratory results

	Result	Normal range
Na (mmol/L)	118	136-145
K (mmol/L)	9.8	3.5-5.1
BUN (mg/dL)	25	4-19
Creatinine (mg/dL)	0.52	0.17-0.42
Uric acid (mg/dL)	6.5	2.4-5.7
17-OHP (ng/mL)	9.6	0.051-2.35
ACTH (ng/L)	5.66	7.2-63.3
Serum cortisol (ug/dL)	32.9	4.82-19.5
Renin (ng/mL/hour)	13.1	2.4-37
Aldosterone (ng/dL)	200	3-16

Na: sodium, K: potassium, BUN: blood urea nitrogen, 17-OHP: 17-hydroxyprogesterone, ACTH: adrenocorticotropic hormone

was ruled out based on normal urine analysis, urine culture, and urinary system ultrasonography. Despite increasing the dose of calcium polystyrene sulfonate to 4 g/kg/day and other conventional treatments, the patient's hyperkalemia persisted, necessitating peritoneal dialysis. Potassium levels decreased from 8.2 mmol/L pre-dialysis to 4.3 mmol/L on follow-up. The patient remained stable on treatment with 4x1 g oral salt and 10 g/day of calcium polystyrene sulfonate. She gained 1360 grams during hospitalization, weighing 4620 grams at discharge on the 37th day, with treatment being appropriately managed.

This infant was diagnosed with electrolyte imbalance at two months of age, pneumonia at 3.5 months, and again with electrolyte imbalance at six months, requiring hospitalization and treatment each time.

At eight months of age, the patient was brought to the emergency department due to vomiting and diarrhea. Initial tests upon arrival showed sodium at 123 mmol/L and potassium at 10.7 mmol/L. Due to respiratory distress and desaturation, the patient underwent endotracheal intubation and was admitted to the pediatric intensive care unit. Following 55 days of hospitalization for pneumonia, the patient passed away at 10 months of age (Figure 1).

Considering the clinical and laboratory findings suggestive of systemic type 1 PHA, the patient's related genes were examined using next-generation sequencing. Informed consent was obtained from the parents for this study. A homozygous variant c.1234dup (p.Glu412Glyfs*39) in exon 8 of the *SCNN1B* gene was identified in the infant. This variant, a nucleotide duplication, has not been reported in population genetics studies and is classified as "likely pathogenic" according to ACMG (American College of Medical Genetics) criteria (21). We plan to conduct genetic testing for the patient's family as well, but this remains outstanding at the time of writing.

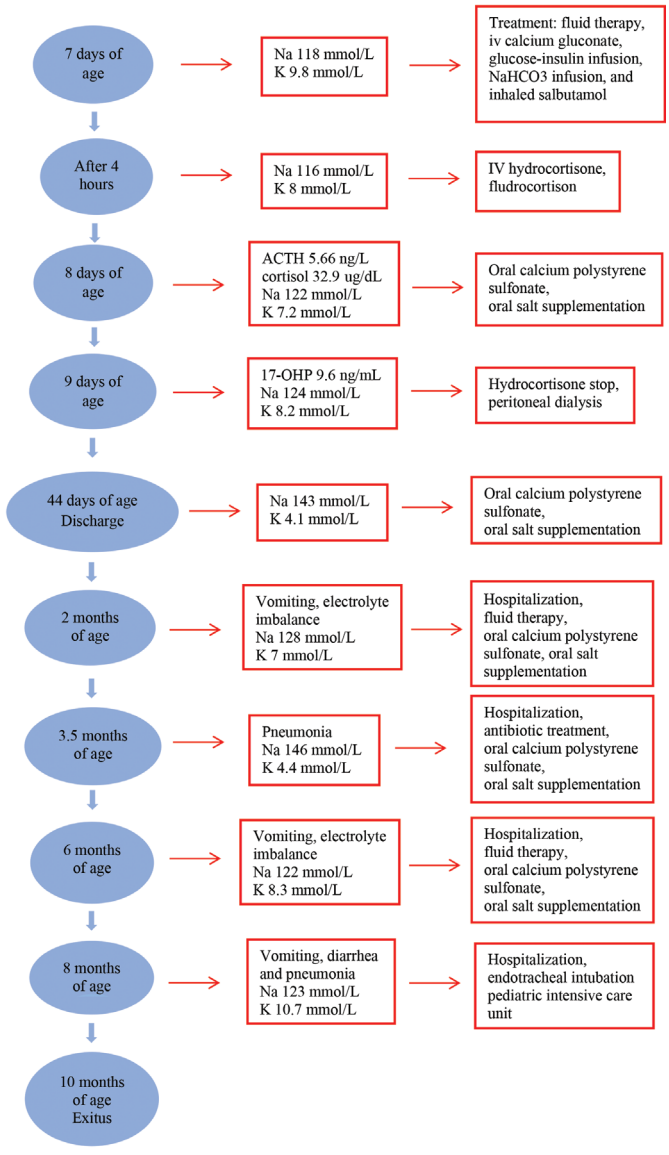

Figure 1. Timeline of case
Na: sodium, K: potassium, 17-OHP: 17-hydroxyprogesterone, ACTH: adrenocorticotropic hormone, HCO3: bicarbonate

Discussion

In this article, we present our observations and the challenges encountered during the treatment process of a newborn with multisystem PHA type 1. Systemic Type 1 PHA is a rare, life-threatening condition. In the neonatal period, salt-wasting syndromes present with various clinical manifestations. Patients may present with nonspecific symptoms such as vomiting, weakness, feeding difficulties, failure to thrive, and increased tendency to sleep, or severe dehydration leading to shock (5). Typically, neonates presenting with these symptoms may initially be misdiagnosed with conditions such as CAH due

to 21-hydroxylase or 3-beta-hydroxysteroid dehydrogenase deficiency, or primary hypoaldosteronism causing salt loss in the neonatal period. The diagnosis of type 1 PHA relies on high plasma aldosterone and renin levels, especially when high-dose mineralocorticoid therapy fails to correct potassium and salt imbalance. Moreover, measurements of 17-hydroxyprogesterone, adrenocorticotropin hormone, cortisol, renin, and aldosterone levels provide clues to distinguish between CAH and type 1 PHA (6). Our patient presented with hyponatremia and hyperkalemia alongside normal genitalia. Hydrocortisone and fludrocortisone were initiated until adrenal androgen results were obtained. The diagnosis of systemic type 1 PHA was confirmed as adrenal hormone levels remained within normal ranges during follow-up. Differential diagnosis in our case included transient aldosterone resistance secondary to urinary tract infection, which was ruled out due to normal urine analysis, urine culture, and urinary system ultrasonography. The co-occurrence of high aldosterone levels with hyponatremia and hyperkalemia supported renal aldosterone resistance guiding our patient's treatment.

Type 1 PHA is classified into renal (OR) and systemic (OD) forms based on mutations in the *NR3C2* gene encoding MR or *SCNN1A*, *SCNN1B*, and *SCNN1G* genes encoding ENaC subunits. The systemic form of type 1 PHA leads to systemic salt loss involving kidneys, colon, sweat, and salivary glands (7). In the presented case, a homozygous variant c.1234dup (p.Glu412Glyfs*39) was identified in exon 8 of the *SCNN1B* gene. The *SCNN1B* gene, comprising 13 exons and encoding a transmembrane protein with two transmembrane segments totaling 640 amino acids (8), has been associated with pathogenic variants linked to type 1 PHA and Liddle syndrome. It is anticipated that the identified homozygous variant in the *SCNN1B* gene at nucleotide position 1234, a duplication variant, affects protein functions. This variant has not been previously reported in the literature.

A case with a homozygous mutation detected in the promoter region of the ENaC in the *SCNN1B* gene also exhibited recurrent lung infections, similar to our patient. However, in this case, over time, the frequency and severity of these respiratory illnesses showed a tendency to decrease, and the lung condition stabilized after the age of six years (9). In another study reporting a case with a mutation detected in the *SCNN1B* gene, additional clinical features included persistent clear nasal discharge, frequent lower respiratory tract infections associated with wheezing, and developmental delay. This case, which required a gastrostomy at 14 months, showed a significant reduction in hospital admissions (1-2 per year) following the gastrostomy, although recurrent lower respiratory tract infections were still reported despite being four years old when reported (10). Similarly, another case reported recurrent chronic bronchitic attacks during childhood (11). In another case with a homozygous c.1266-1G > C variant mutation in intron 8 of the *SCNN1B* gene, vomiting and feeding difficulties similar to those observed in our patient were reported (12). The skin findings observed in our patient, which persisted despite treatment, have also been observed in other patients with mutations in the *SCNN1B* gene. Belot et al. (13) observed bullous dermatitis, while Gopal-Kothandapani et al. (8) reported severe eczema. Similarly, another case with a homozygous mutation in the *SCNN1B* gene presented with features mimicking pustular miliaria rubra, crystal deposition on the forehead, Meibomian gland swelling on the eyelids, and dental-like protrusions (11). These skin and ocular findings can aid in distinguishing type 1 PHA from other conditions causing salt loss, like CAH, prompting the evaluation of serum electrolytes through blood tests (14). In the literature, gastrostomy has been required in four cases due to salt loss (10,11,13,15). Although not needed in our patient, during episodes of vomiting, an orogastric tube was used to administer oral therapies. Hyperkalemia can be life-threatening due to the risk of cardiac arrhythmias. Publications have reported peritoneal dialysis being performed to correct hyperkalemia, as required in the present case (6,8,16,17,18,19).

Since systemic Type 1 PHA can be more refractory to treatment, it is essential to learn from less commonly known approaches. Further guidance for sodium polystyrene sulfonate (brand name: Kayexalate, kalexate, and kionex; molecular weight 70,000 atomic mass units; concentration 15 g/60 mL) administration in neonates and infants under the care of endocrinology is necessary (20). There is limited guidance in the literature on specifically how to give sodium polystyrene sulfonate to neonates and infants, specifically the optimally safe method of transitioning from decanting formula to giving it directly. Sodium polystyrene sulfonate dosing in several children between the ages of 1.75 and 3.25 years old ranged from 0.4 to 3.4 g/kg/day; however, the dosing and method of administration varied (2). Initial direct administration is not always feasible in neonates, to minimize risks such as gastrointestinal bleeding (2). Sodium polystyrene sulfonate can effectively treat hyperkalemia in type 1 PHA, but it is not routinely available in our country. Therefore, we used calcium polystyrene sulfonate in the treatment of our patient.

Conclusion

Clinical suspicion of PHA, aggressive treatment with IV hydration, sodium and bicarbonate supplementation, and correction of hyperkalemia are crucial. Publishing patients' clinical symptoms and genetic changes, and establishing clearer links between reported mutations and clinical outcomes, will lead to earlier clinical diagnosis and effective genetic counseling for families affected by PHA.

Ethics

Informed Consent: Written informed consent of the parents was obtained for this case report.

Footnotes

Authorship Contributions

Surgical and Medical Practices: Berna Singin, Zeynep Donbaloğlu, Ebru Barsal Çetiner, Kürşat Çetin, Nurten Özkan Zarif, Kıymet Çelik, Hale Tuhan, Mesut Parlak, Concept: Berna Singin, Zeynep Donbaloğlu, Ebru Barsal Çetiner, Kürşat Çetin, Hale Tuhan, Mesut Parlak, Design: Berna Singin, Zeynep Donbaloğlu, Ercan Mıhçı, Mesut Parlak, Data Collection and Processing: Berna Singin, Zeynep Donbaloğlu, Ebru Barsal Çetiner, Kürşat Çetin, Nurten Özkan Zarif, Kıymet Çelik, Ercan Mıhçı, Özden Altıok Clark, Hale Tuhan, Mesut Parlak, Analysis or Interpretation: Berna Singin, Zeynep Donbaloğlu, Ercan Mıhçı, Özden Altıok Clark, Literature Search: Berna Singin, Mesut Parlak, Writing: Berna Singin, Mesut Parlak.

Financial Disclosure: The authors declared that this study received no financial support.

References

1. Pujo L, Fagart J, Gary F, Papadimitriou DT, Claës A, Jeunemaître X, Zennaro MC. Mineralocorticoid receptor mutations are the principal cause of renal type 1 pseudohypoaldosteronism. Hum Mutat. 2007;28:33-40.
2. Nur N, Lang C, Hodax JK, Quintos JB. Systemic pseudohypoaldosteronism type I: a case report and review of the literature. Case Rep Pediatr. 2017;2017:7939854. Epub 2017 Apr 18
3. Amin N, Alvi NS, Barth JH, Field HP, Finlay E, Tyerman K, Frazer S, Savill G, Wright NP, Makaya T, Mushtaq T. Pseudohypoaldosteronism type 1: clinical features and management in infancy. Endocrinol Diabetes Metab Case Rep. 2013;2013:130010. Epub 2013 Aug 30
4. Bonny O, Rossier BC. Disturbances of Na/K balance: pseudohypoaldosteronism revisited. J Am Soc Nephrol. 2002;13:2399-2414.
5. Akın MA, Çoban D, Kurtoğlu S, Akın L, Akçakuş M. Yenidoğanda iki tuz kaybı olgusu: primer ve sekonder psödohipoaldesteronizm. Erciyes Tıp Dergisi. 2010;32:207-212. [Turkish]
6. Gao Z, Sun J, Cai C, Gong X, Ma L. Pseudohypoaldosteronism type 1b in fraternal twins of a Chinese family: report of two cases and literature review. Arch Endocrinol Metab. 2023;67:e000620.
7. Riepe FG. Clinical and molecular features of type 1 pseudohypoaldosteronism. Horm Res. 2009;72:1-9. Epub 2009 Jun 30
8. Gopal-Kothandapani JS, Doshi AB, Smith K, Christian M, Mushtaq T, Banerjee I, Padidela R, Ramakrishnan R, Owen C, Cheetham T, Dimitri P. Phenotypic diversity and correlation with the genotypes of pseudohypoaldosteronism type 1. J Pediatr Endocrinol Metab. 2019;32:959-967.
9. Thomas CP, Zhou J, Liu KZ, Mick VE, MacLaughlin E, Knowles M. Systemic pseudohypoaldosteronism from deletion of the promoter region of the human Beta epithelial na(+) channel subunit. Am J Respir Cell Mol Biol. 2002;27:314-319.
10. Edelheit O, Hanukoglu I, Gizewska M, Kandemir N, Tenenbaum-Rakover Y, Yurdakök M, Zajaczek S, Hanukoglu A. Novel mutations in epithelial sodium channel (ENaC) subunit genes and phenotypic expression of multisystem pseudohypoaldosteronism. Clin Endocrinol (Oxf). 2005;62:547-553.
11. Nobel YR, Lodish MB, Raygada M, Rivero JD, Faucz FR, Abraham SB, Lyssikatos C, Belyavskaya E, Stratakis CA, Zilbermint M. Pseudohypoaldosteronism type 1 due to novel variants of SCNN1B gene. Endocrinol Diabetes Metab Case Rep. 2016;2016:150104. Epub 2016 Jan 7
12. Dogan CS, Erdem D, Mesut P, Merve A, Sema A, Iffet B, Afig B. A novel splice site mutation of the beta subunit gene of epithelial sodium channel (ENaC) in one Turkish patient with a systemic form of pseudohypoaldosteronism Type 1. J Pediatr Endocrinol Metab. 2012;25:1035-1039.
13. Belot A, Ranchin B, Fichtner C, Pujo L, Rossier BC, Liutkus A, Morlat C, Nicolino M, Zennaro MC, Cochat P. Pseudohypoaldosteronisms, report on a 10-patient series. Nephrol Dial Transplant. 2008;23:1636-1641.
14. Reddy G, Panigrahy N. Unusual skin and eyelid changes in a neonate with pseudohypoaldosteronism. Archives of Disease in Childhood-Fetal and Neonatal Edition. 2023;108:285-.
15. Saxena A, Hanukoglu I, Saxena D, Thompson RJ, Gardiner RM, Hanukoglu A. Novel mutations responsible for autosomal recessive multisystem pseudohypoaldosteronism and sequence variants in epithelial sodium channel alpha-, beta-, and gamma-subunit genes. J Clin Endocrinol Metab. 2002;87:3344-3350.
16. Güran T, Değirmenci S, Bulut İK, Say A, Riepe FG, Güran Ö. Critical points in the management of pseudohypoaldosteronism type 1. J Clin Res Pediatr Endocrinol. 2011;3:98-100. Epub 2011 Jun 8
17. Saravanapandian N, Paul S, Matthai J. Pseudohypoaldosteronism type 1: a rare cause of severe dyselectrolytemia and cardiovascular collapse in neonates. J Clin Neonatol. 2012;1:224-226.
18. Sharma R, Pandey M, Kanwal SK, Zennaro MC. Pseudohypoaldosteronism type 1: management issues. Indian Pediatr. 2013;50:331-333.
19. Karacan Küçükali G, Çetinkaya S, Tunç G, Oğuz MM, Çelik N, Akkaş KY, Şenel S, Güleray Lafcı N, Savaş Erdeve Ş. Clinical management in systemic type pseudohypoaldosteronism due to SCNN1B variant and literature review. J Clin Res Pediatr Endocrinol. 2021;13:446-451. Epub 2020 Aug 25
20. Alkhatib EH, Bartlett D, Kanakatti Shankar R, Regier D, Merchant N. Case report: Early molecular confirmation and sodium polystyrene sulfonate management of systemic pseudohypoaldosteronism type I. Front Endocrinol (Lausanne). 2024;14:1297335.
21. Richards S, Aziz N, Bale S, Bick D, Das S, Gastier-Foster J, Grody WW, Hegde M, Lyon E, Spector E, Voelkerding K, Rehm HL; ACMG Laboratory Quality Assurance Committee. Standards and guidelines for the interpretation of sequence variants: a joint consensus recommendation of the American College of Medical Genetics and Genomics and the Association for Molecular Pathology. Genet Med. 2015;17:405-424. Epub 2015 Mar 5

CASE REPORT

JCRPE Journal of Clinical Research in Pediatric Endocrinology

DOI: 10.4274/jcrpe.galenos.2024.2024-8-4
J Clin Res Pediatr Endocrinol 2026;18(Suppl 1):59-63

Clinical and Molecular Landscape of Weiss-Kruszka Syndrome: A Case Report and Literature Review

Lele Li, Chunxiu Gong

Beijing Children's Hospital, the Capital Medical University, National Center for Children's Health, Department of Endocrinology, Genetics, Metabolism and Adolescent Medicine, Beijing, China

Cite this article as: Li L, Gong C. Clinical and molecular landscape of Weiss-Kruszka syndrome: a case report and literature review. J Clin Res Pediatr Endocrinol. 2026;18(Suppl 1):59-63

What is already known on this topic?

Weiss-Kruszka syndrome (WSKA; OMIM#618619) is a rare condition with multiple congenital anomalies. The syndrome is linked to a heterozygous pathogenic variant in the zinc finger protein 462 gene (*ZNF462*, MIM#617371) and deletion of the 9q31.2 chromosome region involving *ZNF462*.

What this study adds?

This study describes a patient with WSKA from Northern China caused by a novel *de novo* splicing variant in the *ZNF462* gene. We also review and analyze reported cases to describe the clinical and molecular landscape of WSKA and improve clinical diagnosis and management of this rare syndrome.

ABSTRACT

Weiss-Kruszka syndrome (WSKA; OMIM#618619) is a rare condition with multiple congenital anomalies. This study describes a patient with WSKA from Northern China. The patient was a 9.75-year-old boy who presented with growth retardation (growth velocity: 3-4 cm/year at school age), delayed motor and speech development, and eating difficulty. The patient's weight was 22 kg (<3rd percentile), and his height was 125.6 cm (<3rd percentile) at the first visit. He had craniofacial anomalies characterized by heavily arched eyebrows, mild bilateral ptosis, inner epicanthal folds, uneven teeth, macrodontia of the upper central incisors, and low-set ears. A transverse palmar crease was observed on the right palm. The serum insulin-like growth factor-1 level was 73.1 ng/mL (normal range: 74-388 ng/mL). His bone age was appropriate at 9-10 years. Cranial magnetic resonance imaging results revealed a small pituitary gland. Trio whole-exome sequencing was performed because of the patient's non-specific dysmorphic features and a phenotype indistinguishable from many other inherited disorders with growth retardation.

Corresponding Author: Chunxiu Gong, MD, Beijing Children's Hospital, the Capital Medical University, National Center for Children's Health, Department of Endocrinology, Genetics, Metabolism and Adolescent Medicine, Beijing, China

E-mail: chunxiugong@sina.com **ORCID:** orcid.org/0000-0002-1262-7383

Conflict of interest: None declared

Received: 05.09.2024 **Accepted:** 30.12.2024 **Epub:** 19.03.2025 **Publication Date:** 02.06.2026

©Copyright 2026 by Turkish Society for Pediatric Endocrinology and Diabetes / The Journal of Clinical Research in Pediatric Endocrinology published by Galenos Publishing House. Licensed under a Creative Commons Attribution-NonCommercial-NoDerivatives 4.0 (CC BY-NC-ND) International License.

A *de novo* splicing variant, c.6833-2A>T, was identified in the *ZNF462* gene (NM_021224). Recombinant human growth hormone therapy was started (dose, 0.15 IU/kg/day) and administered as daily subcutaneous injections. His growth velocity increased (5 cm/6 months). This case has been added to the limited number of publications reporting WSKA. This study also reports the genotypic and phenotypic landscape of WKSA, providing clinical and genetic data to support the etiology of haploinsufficiency of the *ZNF462* gene, as postulated by previous studies.

Keywords: *ZNF462* gene, genotypic, phenotypic, Weiss-Kruszka syndrome

Introduction

Weiss-Kruszka syndrome (WSKA; OMIM#618619) is a rare genetic condition characterized by multiple congenital anomalies. Typical features include mild global developmental delay, ptosis, and distinctive dysmorphic craniofacial abnormalities, such as metopic ridging or synostosis, and a triangular-shaped forehead with or without autistic features. Brain imaging may reveal abnormalities in the corpus callosum; however, developmental delays may present as global, motor, or speech delays. Additional features may include ear anomalies, feeding difficulties, or congenital heart defects (1,2).

The syndrome is inherited in an autosomal dominant manner, demonstrating complete penetrance but variable expressivity within and across affected families. The syndrome is linked to a heterozygous pathogenic variant in the zinc finger protein 462 gene (*ZNF462*, MIM#617371) and deletion of the 9q31.2 chromosome region involving *ZNF462* (3). To date, only 30 affected individuals from 28 families have been described, no genotype-phenotype correlations have been identified (2,3,4,5,6,9), and the underlying mechanisms remain unclear. With the increasing number of cases worldwide, the original phenotype has expanded, including several complications, such as complete growth hormone deficiency associated with empty sella syndrome (7), Kallmann syndrome (8), and oncological diseases (10).

This study describes a patient with WSKA from Northern China, caused by a novel *de novo* splicing variant in the *ZNF462* gene. A secondary aim of the report is to improve the clinical diagnosis and management of this very rare syndrome by reviewing and analyzing previously reported cases to describe the clinical and molecular characteristics of WSKA.

Case Report

The patient was a 9-year-9-month-old boy admitted to the Department of Endocrinology and Metabolism at Beijing Children's Hospital (Beijing, China) for evaluation of growth retardation as his growth velocity (GV) was 3-4 cm/year, which is below the normal range for his age (GV 5-7cm). He was the second child of healthy, non-consanguineous Chinese parents with no previous abortions and a well-controlled, echographically normal pregnancy. The family had no history of congenital malformations, short stature, intellectual disability, autism spectrum disorder, or other genetic disorders. The first child of this family was a healthy boy without any growth or developmental issues, but he unfortunately died in an accident at 15 years of age. The patient was born at full term via vaginal delivery, with a birth weight of 3.25 kg [-0.175 standard deviation score (SDS)] and a length of 50 cm (-0.22 SDS). No postnatal problems, such as microphallus, cryptorchidism, hypoglycemia, prolonged jaundice, or hypotonia, were reported. He had no history of trauma or chronic illnesses. According to his parents, he could sit and walk unassisted at 8 months and 18 months of age, respectively. However, his language development was delayed when he was young. He started to gain his adult dentition at 8 years of age. He was a picky eater and ate little food but had normal daily activities and sleep duration. No additional congenital anomalies, such as congenital heart defects, optic nerve hypoplasia, papilledema, or hearing impairment, were reported. The patient had no mild hypotonia or other neurological symptoms.

Physical examination: The patient weighed 22 kg (<3rd percentile, -1.87 SD), and his height was 125.6 cm (<3rd percentile, -2.21 SD) at the first visit. The heights of his father and mother were 172 cm and 162 cm, respectively, giving a mid-parental height of 173.5±5 cm. His height was -2.27 SDs below the expected range, falling short of the target family height. He had craniofacial anomalies characterized by heavily arched eyebrows, mild bilateral ptosis, inner epicanthal folds, uneven teeth, macrodontia of the upper central incisors, and low-set ears. A transverse palmar crease was observed on his right palm. His pubertal stage was assessed as Tanner Stage 1 for external genitalia development (testis volume, 2 mL) and pubic hair.

Laboratory and imaging analyses: Laboratory test results for routine blood and urine, including liver and kidney function, and electrolyte levels were within the normal range. The thyroid hormone level including thyroid stimulating hormone, free triiodothyronine, free thyroxine was normal. Plasma adrenocorticotropic hormone and serum cortisol levels were normal. His gonadotropin levels were: basal luteinizing hormone, 0.3 mIU/mL; basal serum follicle-stimulating hormone, 0.5 mIU/mL; testosterone, <20 ng/mL; estradiol, <20 pg/mL; human chorionic gonadotropin, <0.1 mIU/mL; which were consistent with prepubertal status. Serum insulin-like growth factor (IGF)-1 and IGF binding protein-3 levels were 73.1 ng/mL (normal range: 74-388 ng/mL) and 2.69 µg/mL (normal range: 1.8-7.1 µg/mL),

respectively. The bone age was 9-10 years, consistent with his chronological age. Electrocardiography revealed sinus rhythm. The Chinese Wechsler Intelligence Scale for children indicated a verbal intelligence quotient score of 68 and a performance intelligence quotient score of 63. Abdominal ultrasonography showed normal liver, gall bladder, pancreas, spleen, and kidneys. Cranial magnetic resonance imaging (MRI) results indicated a small pituitary gland.

Genetic analysis: Trio (proband and both parents) whole-exome sequencing was performed because of the nonspecific dysmorphic features in the patient and a phenotype indistinguishable from many other inherited disorders with growth retardation. Genomic DNA samples were extracted from the peripheral blood of the patient and his parents and sent to an accredited domestic company for commercial sequencing (MyGenostics, Beijing, China). A *de novo* splicing variant, c.6833-2A > T, was identified in the *ZNF462* gene (NM_021224). The variant was identified in heterozygosis in the patient but was absent in his parents. According to the American College of Medical Genetics variant classification guidelines (11), the variant should be classified as "likely pathogenic". It is a splicing variant in a gene where loss of function is a known disease mechanism, and it removes a portion of the protein (< 10%), which has not been established as crucial to its function (PVS1_moderate). The variant was absent in the parents (*de novo* mutation), and there was no family history (PS2); moreover, the variant has not been reported in general population databases (ClinVar, ExAC, gnomAD, 1000 G) (PM2).

Treatment and follow-up: Recombinant human growth hormone (rhGH) therapy was started at a dose of 0.15 IU/kg/day and administered as daily subcutaneous injections. Unfortunately, the family were lost to follow-up because they moved away from Beijing; however, information obtained via telephone follow-up indicated that his GV was faster than before (5 cm/6 months). No adverse events, such as headaches, were reported.

Discussion

WSKA is a rare disorder caused by mutations in the *ZNF462* gene or deletion of the 9p31.2 chromosome region containing the *ZNF462* gene. The worldwide prevalence of WSKA is unknown, with only 30 affected individuals have been described currently (2,3,4,5,6,7,8,10) and there is only one reported case among the Chinese Han population (9). The number of patients with WSKA reported may be far lower than those harboring *ZNF462* gene variation, which may be due to limited awareness of the disease among healthcare providers, the variability in disease phenotypes, and the mild presentation in some patients.

This study described a patient with WSKA from Northern China, presenting with a novel *de novo* splicing variant in the *ZNF462* gene. This case adds to the limited number of reported cases of WSKA globally; previously reported cases were also reviewed and analyzed given the rarity of the diagnosis. All reviewed patients harbored *ZNF462* variants or deletion in the 9q31.2 chromosome region. The reported patients demonstrated an approximately 2:1 female to male incidence and exhibited a broad spectrum of phenotypes. The most prevalent reported characteristics included developmental delay and craniofacial abnormalities (Table 1). Other phenotypes included autism spectrum disorders, feeding issues, brain abnormalities, congenital heart defects, and limb anomalies (1,2,9). Clinical analyses of the individuals were heterogeneous, and not all individuals underwent comprehensive evaluation, such as brain and heart imaging. Thus, the phenotype frequencies shown in Table 1 may be underestimated. Given the prevalence of developmental delay, corpus callosum anomalies, congenital heart defects, and hearing loss, a comprehensive multidisciplinary evaluation is recommended for individuals with loss-of-function variants in the *ZNF462* gene. Such an assessment should include growth and developmental evaluation, physical examination to identify face shape and suture ridging, ophthalmological evaluation, neuropsychiatric evaluation, hearing evaluation, gastrointestinal/feeding evaluation, cardiac examination with echocardiography, brain imaging, and consultation with a clinical geneticist and genetic counselor. As more patients undergo thorough longitudinal studies, future recommendations for targeted management may emerge.

Table 1. Clinical features of patients with Weiss-Kruszka syndrome

Items	n (%)
Sex (F/M)	20/11
Developmental delay	24/31 (77.4)
Autism spectrum disorder	10/31 (32.2)
Craniofacial features	
Ptosis	27/31 (87.1)
Down slanted palpebral fissures	15/31 (48.4)
Cupid's bow	15/31 (48.4)
Arched eyebrows	15/31 (48.4)
Epicanthal folds	14/31 (45.1)
Short upturned nose	12/31 (38.7)
Ears/hearing	17/31 (54.8)
Feeding issues	14/31 (45.1)
Congenital heart disease	8/31 (25.8)
Limb anomalies	7/31 (22.5)
Craniosynostosis/metopic ridging	10/31 (32.2)
Brain abnormalities	9/31 (29.0)

M: male, F: female

Our patient presented with typical craniofacial features previously reported in individuals with WSKA, including heavily arched eyebrows, mild bilateral ptosis, inner epicanthal folds, low-set ears, together with a transverse right-sided palmar crease, developmental delay, and feeding difficulties. However, growth retardation was the chief complaint of this patient. Among the 19 reported cases with available height parameters, six cases (approximately 31.5%) had height/length below the third percentile for the same age and sex, and nine (approximately 47.3%) were below the tenth percentile. Growth retardation may become apparent with age. Of note, three of these 19 with height data were taller, 75th percentile or greater and one patient exceeded the 97th percentile (Supplementary Table 1). Presently, few reports describe adult patients with WSKA, leaving the long-term height prognosis unclear. One paper presented the case of a Korean boy with molecularly confirmed WSKA and primary empty sella syndrome associated with growth hormone deficiency (7). In the present case, the patient had a slightly lower IGF-1 level and smaller pituitary volume, which may be associated with hypothalamic-pituitary dysfunction. Further studies are required to identify the exact mechanisms of growth retardation, and should include GH assessment by stimulation test.

The formal diagnostic criteria for WKSA have not yet been established. WKSA should be suspected in individuals with suggestive clinical and brain MRI findings. Diagnosis is confirmed by identifying a heterozygous pathogenic variant in *ZNF462* or deletion of 9p31.2 including *ZNF462* or, rarely, chromosome rearrangements that disrupt *ZNF462* (1). *ZNF462* is a C2H2-type zinc finger transcription factor with 23 zinc finger domains, making DNA binding a likely function (12). *ZNF462* is essential for embryonic development in multiple species, is involved in chromatin remodeling, and binds *H3K9me3*, making it a chromatin reader involved in heterochromatin modifications (13). *ZNF262* is also necessary for cell division during the cleavage stage (14), helps maintain chromatin structure in pluripotent cells (15), and interacts with the heterochromatin protein 1α (HP1α) (13). As hallmarks of heterochromatin, HP1α and *H3K9me3* are key to gene silencing, repetitive DNA transcription, and genome integrity (16,17,18), further emphasizing the role of *ZNF462* in chromatin remodeling. WKSA occurs via a presumed loss-of-function mechanism, inherited in an autosomal dominant manner, with most pathogenic variants reported in exon 3. However, the molecular mechanism underlying this associated phenotype remains unknown. Most cases (95%) occur because of *de novo* mutations in *ZNF462,* and only 5% of individuals diagnosed with WKSA have an affected parent, with parental germline mosaicism reported in only one family (2). No genotype-phenotype correlations have been identified because familial cases show highly variable expressivity in the phenotypic manifestations, making genetic counseling important for understanding the disease etiology, recurrence risk, and family planning, including prenatal and preimplantation genetic testing. However, because of intrafamilial clinical variability, molecular genetic test results cannot accurately predict clinical findings.

The treatment of WKSA is primarily symptomatic and involves comprehensive clinical multidisciplinary therapy. Only one case report has discussed the effectiveness of growth hormone therapy for short stature (3). In this report, rhGH replacement was initiated at a dose of 0.23 mg/kg/week and was gradually increased to 0.3 mg/kg/week. After two years of treatment, an improvement in height velocity (8 cm/year) was observed, with the height SDS increasing from -3.49 SDS to -1.15 SDS. Our patient was also treated with rhGH but treatment effectiveness could not be determined owing to the short duration of the treatment. Further study of the molecular mechanisms involving *ZNF462* may open new avenues for targeted therapy.

Conclusion

In conclusion, this study describes a Chinese patient diagnosed with WKSA and the genotypic and phenotypic characteristics of all published cases of WKSA. The presented patient provides additional clinical and genetic evidence to support the mechanism of haploinsufficiency of the *ZNF462* gene, as proposed by earlier studies. The novel variant and phenotypes observed in our patient expands the spectrum of clinical features, genetic characteristics, diagnostic protocols, and genetic counseling for WSKA.

Ethics

Informed Consent: This study was approved by the Ethics Committee of Beijing Children's Hospital, Capital Medical University (2020-k-139). Written informed consent was obtained from the legal guardian of the participant. This study was conducted in accordance with the principles of the Declaration of Helsinki.

Acknowledgments

We would like to thank the patient, all his family, and the medical staff involved in this study. We would like to thank Editage (www.editage.cn) for English language editing.

Footnotes

Authorship Contributions

Concept: Chunxiu Gong, Design: Chunxiu Gong, Data Collection and Processing: Chunxiu Gong, Analysis or Interpretation: Lele Li, Literature Search: Lele Li, Writing: Lele Li.

Financial Disclosure: The study was supported by Beijing Hospitals Authority Youth Programme (grant number: QML20201205) and Jin Lei Pediatric Endocrinology Growth Research Fund for Young Physicians (grant number: PEGRF202011034).

Supplementary Table: https://d2v96fxpocvxx.cloudfront.net/cf9d60d6-523c-458a-a2e6-78728d3ffbb0/content-images/c28950ce-ed26-446f-b42f-0523dbd8b60d.pdf

References

1. Kruszka P. Weiss-Kruszka Syndrome. 2019 Oct 31. In: Adam MP, Bick S, Mirzaa GM, Pagon RA, Wallace SE, Amemiya A, editors. GeneReviews® [Internet]. Seattle (WA): University of Washington, Seattle; 1993-2026. https://www.ncbi.nlm.nih.gov/books/NBK549204/

2. Kruszka P, Hu T, Hong S, Signer R, Cogné B, Isidor B, Mazzola SE, Giltay JC, van Gassen KLI, England EM, Pais L, Ockeloen CW, Sanchez-Lara PA, Kinning E, Adams DJ, Treat K, Torres-Martinez W, Bedeschi MF, Iascone M, Blaney S, Bell O, Tan TY, Delrue MA, Jurgens J, Barry BJ, Engle EC, Savage SK, Fleischer N, Martinez-Agosto JA, Boycott K, Zackai EH, Muenke M. Phenotype delineation of ZNF462 related syndrome. Am J Med Genet A 2019;179:2075-2082.

3. Weiss K, Wigby K, Fannemel M, Henderson LB, Beck N, Ghali N, Study DDD, Anderlid BM, Lundin J, Hamosh A, Jones MC, Ghedia S, Muenke M, Kruszka P. Haploinsufficiency of ZNF462 is associated with craniofacial anomalies, corpus callosum dysgenesis, ptosis, and developmental delay. Eur J Hum Genet. 2017;25:946-951. Epub 2017 May 17

4. Talisetti A, Forrester SR, Gregory D, Johnson L, Schneider MC, Kimonis VE. Temtamy-like syndrome associated with translocation of 2p24 and 9q32. Clin Dysmorphol. 2003;12:175-177.

5. Cosemans N, Vandenhove L, Maljaars J, Van Esch H, Devriendt K, Baldwin A, Fryns JP, Noens I, Peeters H. ZNF462 and KLF12 are disrupted by a de novo translocation in a patient with syndromic intellectual disability and autism spectrum disorder. Eur J Med Genet. 2018;61:376-383. Epub 2018 Feb 7

6. González-Tarancón R, Salvador-Rupérez E, Miramar Gallart MD, Barroso E, Díez García-Prieto I, Pérez Delgado R, López Pisón J, García Jiménez MC. A novel mutation in the *ZNF462* gene c.3306dup; p.(Gln1103Thrfs*10) is associated to Weiss-Kruszka syndrome. A case report. Acta Clin Belg. 2022;77:118-121. Epub 2020 Jun 16

7. Park J, Ha DJ, Seo GH, Maeng S, Kang SM, Kim S, Lee JE. Empty Sella syndrome associated with growth hormone deficiency: the first case report of Weiss-Kruszka syndrome. J Korean Med Sci. 2021;36:e133.

8. Iivonen AP, Kärkinen J, Yellapragada V, Sidoroff V, Almusa H, Vaaralahti K, Raivio T. Kallmann syndrome in a patient with Weiss-Kruszka syndrome and a de novo deletion in 9q31.2. Eur J Endocrinol. 2021;185:57-66.

9. Zhao S, Miao C, Wang X, Lu Y, Liu H, Zhang X. A nonsense variant of *ZNF462* gene associated with Weiss-Kruszka syndrome-like manifestations: a case study and literature review. Front Genet. 2022;13:781832.

10. Pellino G, Chiasso L, Fiori G, Mazzone S, Zama D, Cordelli DM, Russo A. Acute lymphoblastic leukemia in a child with Weiss-Kruszka syndrome: casual or causal association? Eur J Med Genet. 2022;65:104457.

11. Richards S, Aziz N, Bale S, Bick D, Das S, Gastier-Foster J, Grody WW, Hegde M, Lyon E, Spector E, Voelkerding K, Rehm HL; ACMG Laboratory Quality Assurance Committee. Standards and guidelines for the interpretation of sequence variants: a joint consensus recommendation of the American College of Medical Genetics and Genomics and the Association for Molecular Pathology. Genet Med. 2015;17:405-424.

12. Chang YS, Stoykova A, Chowdhury K, Gruss P. Graded expression of *Zfp462* in the embryonic mouse cerebral cortex. Gene Expr Patterns. 2007;7:405-412.

13. Eberl HC, Spruijt CG, Kelstrup CD, Vermeulen M, Mann M. A map of general and specialized chromatin readers in mouse tissues generated by label-free interaction proteomics. Mol Cell. 2013;49:368-378. Epub 2012 Nov 29

14. Laurent A, Masse J, Omilli F, Deschamps S, Richard-Parpaillon L, Chartrain I, Pellerin I. ZFPIP/Zfp462 is maternally required for proper early Xenopus laevis development. Dev Biol. 2009;327:169-176. Epub 2008 Dec 16

15. Massé J, Laurent A, Nicol B, Guerrier D, Pellerin I, Deschamps S. Involvement of ZFPIP/Zfp462 in chromatin integrity and survival of P19 pluripotent cells. Exp Cell Res. 2010;316:1190-1201.

16. Almouzni G, Probst AV. Heterochromatin maintenance and establishment: lessons from the mouse pericentromere. Nucleus 2011;2:332-338.

17. Beisel C, Paro R. Silencing chromatin: comparing modes and mechanisms. Nat Rev Genet. 2011;12:123-135. Epub 2011 Jan 11

18. Ren J, Martienssen RA. Silent decision: HP1 protein escorts heterochromatic RNAs to their destiny. EMBO J. 2012;31:3237-3238. Epub 2012 Jun 15

CASE REPORT

JCRPE Journal of Clinical Research in Pediatric Endocrinology

DOI: 10.4274/jcrpe.galenos.2025.2024-10-11
J Clin Res Pediatr Endocrinol 2026;18(Suppl 1):64-69

Cabergoline Induced Pathological Gambling in an Adolescent with Prolactinoma

Ummahan Tercan[1], Ezgi Sarban[1], Melek Yıldız[1], Özlem Nida Erbaşı[2], Mine Özkan[3], Aslı Derya Kardelen[1], Şükran Poyrazoğlu[1], Firdevs Baş[1], Feyza Darendeliler[1]

[1]İstanbul University, İstanbul Faculty of Medicine, Department of Pediatric Endocrinology, İstanbul, Türkiye
[2]İstanbul University, İstanbul Faculty of Medicine, Department of Child and Adolescent Psychiatry, İstanbul, Türkiye
[3]İstanbul University, İstanbul Faculty of Medicine, Department of Psychiatry, İstanbul, Türkiye

Cite this article as: Tercan U, Sarban E, Yıldız M, Erbaşı ÖN, Özkan M, Kardelen AD, Poyrazoğlu Ş, Baş F, Darendeliler F. Cabergoline induced pathological gambling in an adolescent with prolactinoma. J Clin Res Pediatr Endocrinol. 2026;18(Suppl 1):64-69

What is already known on this topic?

Dopamine agonists are known to be associated with the development of impulse control disorders, such as pathological gambling in adult patients. Pathological gambling has been reported as a rare side effect of dopamine agonist in the adolescent age group.

What this study adds?

This is the first documented case of cabergoline-induced pathological gambling in an adolescent patient being treated for prolactinoma. This case highlights the need for careful psychiatric monitoring of patients, especially those undergoing treatment with dopamine agonists. Early identification and intervention may be important in preventing and managing such impulse control disorders.

ABSTRACT

Prolactinomas are the most common hormone-secreting pituitary adenomas in adolescents. Dopamine agonists (DA) are used as first-line medical treatment. DAs are associated with an array of physical side effects; however, impulse control disorders (ICDs), such as pathological gambling (PG), have also been reported in adults. A 15.7-year-old male with no psychiatric history was referred for headache and elevated prolactin (PRL) levels. He was diagnosed with PRL-secreting pituitary macroadenoma. After initiating DA therapy with cabergoline (CBG), normalization of PRL levels and a considerable decrease in tumor size were observed. Central hypothyroidism and adrenal insufficiency present at the time of diagnosis were resolved. CBG dose was adjusted according to the test results over time. However, after two and a half years of therapy (while using 1.5 mg CBG per week), the patient developed PG, incurring debts and affecting familial relationships. Upon reducing the

Corresponding Author: Ummahan Tercan, MD, İstanbul University, İstanbul Faculty of Medicine, Department of Pediatric Endocrinology, İstanbul, Türkiye
E-mail: ummahantercan@gmail.com **ORCID:** orcid.org/0000-0002-3240-3408
Received: 24.10.2024 **Accepted:** 02.01.2025 **Epub:** 24.01.2025 **Publication Date:** 02.06.2026

©Copyright 2026 by Turkish Society for Pediatric Endocrinology and Diabetes / The Journal of Clinical Research in Pediatric Endocrinology published by Galenos Publishing House.
Licensed under a Creative Commons Attribution-NonCommercial-NoDerivatives 4.0 (CC BY-NC-ND) International License.

CBG dosage, PG symptoms ceased. This is the first case report of an adolescent with a PRL-secreting macroadenoma who developed PG as a side effect of CBG treatment. This case highlights the need for careful monitoring of psychiatric symptoms in pediatric patients with prolactinoma on DAs.

Keywords: Adolescent, cabergoline, dopamine agonist, pathological gambling, prolactinoma

Introduction

Prolactinomas are the most prevalent hormone-secreting pituitary adenomas in adolescents (1,2). For prolactinomas, medical therapy, typically with dopamine agonists (DA), such as bromocriptine (BRC) or cabergoline (CBG), is the first-line treatment (2,3). DAs are generally well tolerated but can be associated with an array of side effects, which predominantly manifest during the initial phase of therapy. Gastrointestinal disturbances are the most frequent adverse events. Neurologically, patients might have headache, dizziness, dyskinesia, and confusion (4). The side effects of DAs may also include psychiatric complications such as depression, anxiety, insomnia, hallucinations, and mania. Although impulse control disorders (ICDs) have been associated with the treatment of Parkinson's disease (PD), they have also been described in pituitary adenoma patients treated with DAs (5). ICDs are psychiatric disorders characterized by difficulty in regulating emotions and behaviors, ranging from mild issues like punding to more serious conditions such as pathological gambling (PG) and hypersexuality, which can negatively impact personal and social well-being (6). ICDs, including PG, share a biological background with other addictive disorders. PG is considered a behavioral ICD, where the individual is unable to resist urges to gamble (7).

Here, we report the case of an adolescent boy with a macroadenoma secreting prolactin (PRL), who developed PG as a side effect of CBG treatment. To the best of our knowledge, this is the first documented CBG-induced gambling disorder among adolescents within the current literature. Moreover, this emphasizes the importance of careful monitoring and management of DA-induced side effects.

Case Report

A 15.7-year-old male presented with a complaint of headache and was referred to pediatric endocrinology due to a markedly elevated PRL level of 462 ng/mL (N=4.04-15.2). The patient was previously healthy and his medical history was unremarkable, with no psychiatric history. He was born at term, with a birth weight of 4380 g, from healthy parents with a non-consanguineous marriage. At presentation, his body weight was 88 kg [-0.81 standard deviation score (SDS)], height was 178 cm (1.88 SDS), and body mass index (BMI) was 27.9 kg/m^2 (1.62 SDS). His blood pressure was within the normal limits, and neither galactorrhea nor gynecomastia was present. Testicular volumes were 15 mL/15 mL and pubic hair was compatible with Tanner stage 5. His systemic physical examination results were otherwise normal.

Hormonal evaluation revealed a markedly elevated PRL level of 539.9 ng/mL (N=4.04-15.2). Growth hormone and gonadotropin levels were within normal limits. Free thyroxine (T4) level was below the lower limits and retest-confirmed central hypothyroidism. As the patient's baseline cortisol level was low, a low-dose (1 µg) adrenocorticotropin hormone stimulation test was performed, and peak cortisol was found to be inadequate at 10.9 µg/dL (N>18 µg/dL). The hormonal profiles of the patient at the time of diagnosis are shown in Table 1. Magnetic resonance imaging (MRI) revealed a pituitary adenoma, 19×14×13 mm

Table 1. Hormonal profile of the patient at the time of diagnosis

Test	Result	Normal range
Prolactin (ng/mL)	539.9	4.04-15.2
FSH (IU/L)	5.79	1.5-12.4
LH (IU/L)	5.4	1.7-8.6
Total testosterone (ng/mL)	3.05	2-6.2
TSH (µIU/mL)	2.04	0.53-3.59
Free T4 (pmol/L)	9.6	12-20.6
Free T3 (pmol/L)	6.88	3.5-7.7
IGF-1 (ng/mL)	365	211-512
IGFBP3 (µg/mL)	9.53	3.4-9.5
Growth hormone (ng/mL)	0.38	0.077-10.6
Cortisol (08:00 am) (ug/dL)	3.06	3-21
ACTH (pg/mL)	30	7.2-63.3

FSH: follicle stimulating hormone, LH: luteinizing hormone, TSH: thyroid stimulating hormone, free T4: free thyroxine, free T3: free triiodothyronine, IGF-1: insulin like growth factor-1, IGFBP3: insulin like growth factor binding protein 3, ACTH: adrenocorticotropic hormone

J Clin Res Pediatr Endocrinol
2026;18(Suppl 1):64-69

in diameter, extending into the suprasellar cistern with thin, peripheral, septal enhancements. This finding was consistent with a cystic degenerated adenoma with hemorrhagic leveling, and the optic chiasm was slightly elevated. The infundibular stalk was deviated to the left side, and a 14×10×10 mm cystic lesion was found in the pineal gland. Visual field examination at the time of diagnosis was normal. Thyroid hormone and hydrocortisone therapies were commenced for central hypothyroidism and central adrenal insufficiency. For hyperprolactinemia, CBG treatment at a dose of 0.5 mg three days/week was initiated. Echocardiography findings before CBG therapy were normal.

After three months, his headaches regressed. Serum PRL level was 1.93 ng/mL, which was below the normal range and follow-up MRI revealed a 40% reduction in the size of the macroadenoma. Subsequently, the CBG dose was gradually reduced to 0.75 mg per week, and the PRL level normalized to 5.92 ng/mL. The maintenance dose was adjusted according to the test results over the years. Ten months after the onset of hydrocortisone therapy, it was discontinued because of an adequate peak cortisol response in a low-dose adrenocorticotropic hormone test (off-therapy for 24 h). At this time, replacement levothyroxine therapy was also stopped. Subsequent medication-free evaluations showed that thyroid function test results were within normal limits.

Two and a half years after the initiation of treatment, at 18.2 years, the CBG dosage was 1.5 mg per week. According to his parents' statement, although he had no gambling history before, the patient's change in behavior was dramatic, having been gambling on the Internet for four months. He gambled on most days, lost 60,000 Turkish lira (3900 Euro), and incurred increased debts due to gambling. This behavior resulted in significant financial losses and deteriorated family relationships. There was no impulsive or affective behavior or other psychiatric diseases in his family history. On his laboratory evaluation, the PRL level was 14.9 ng/mL, baseline cortisol level was 12.4 µg/dL, insulin-like growth factor 1 was 262.3 ng/mL, luteinizing hormone level 4.87 IU/L, follicle stimulating hormone level was 6.38 IU/L, total testosterone was 3.5 ng/mL; all within the normal range. He was referred to a psychiatry clinic and diagnosed with PG secondary to CBG treatment. The diagnosis was based on Diagnostic and Statistical Manual of Mental Disorders, Fifth Edition (DSM-5) criteria for non-substance addictive disorders and supported by a clinical interview. Gambling behavior started after initiating CBG, persisted during treatment, and resolved after dose reduction, suggesting a direct link to the medication. Other ICDs, including hypersexuality, were investigated but not identified. The CBG dose was reduced to 0.5 mg per week because it was thought to be the triggering factor for his PG. Three months after dose reduction, the patient's gambling issues ceased. At the last visit, the patient had no complaints. His PRL level was 20 ng/mL. Serum PRL levels and CBG dosage over time is shown in Figure 1. The follow-up pituitary MRI showed regression in adenoma size compared with the previous MRI. The visual field examination and echocardiography results were normal. CBG was continued at a dose of 0.25 mg twice a week. The patient has now been transferred to adult care. He continues to take his medications and attended regular check-ups.

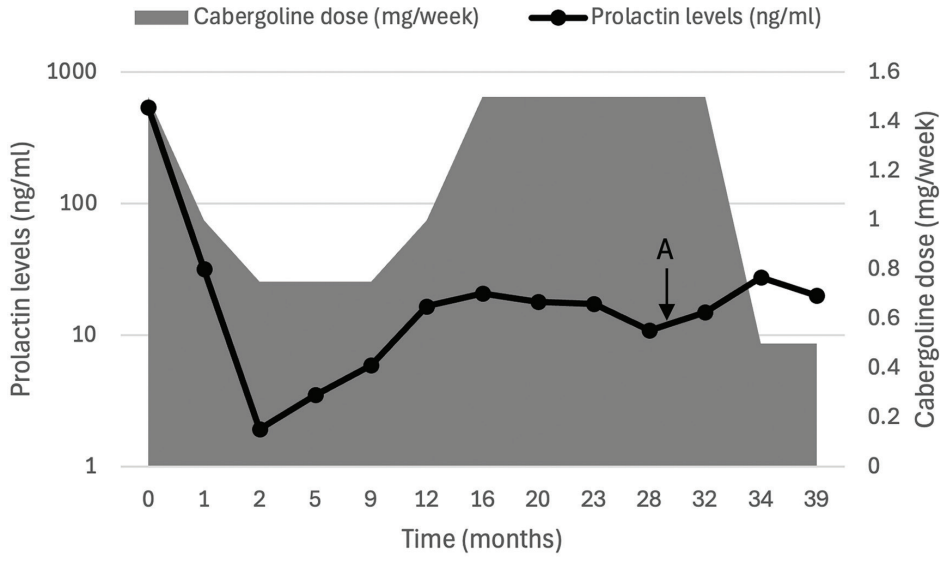

Figure 1. Serum prolactin levels and cabergoline dose over time. Arrow 'A': Onset of symptoms of pathological gambling disorder

Discussion

PG is a relatively rare side effect of DAs, which are the mainstay in the management of PRL-secreting pituitary adenomas. In this case report, we focused on a significant instance of gambling addiction linked to the use of CBG in managing prolactinomas that manifest during adolescence. While CBG and BRC remain the mainstay FDA approved therapies for hyperprolactinemia, alternatives such as pergolide and quinagolide, play minimal clinical roles. Pergolide was removed from the United States (US) market in 2007 following safety concerns regarding heart valve disease, and quinagolide is currently not available for use in the US (8). CBG is preferred in clinical practice for its efficacy at low weekly doses (0.25-0.5 mg), which is generally well-tolerated. The goal of DA therapy is to reduce PRL levels and shrink adenomas, with dosages adjusted according to the severity of the condition and patient's response to treatment. This involves tapering off or discontinuing DAs after normalization of serum PRL levels and adenoma resolution, typically after a minimum of two years of therapy (9).

ICDs are a group of psychiatric conditions defined in DSM-5, and are characterized by significant challenges in regulating emotions and behaviors (10). These disorders manifest as actions that may infringe upon the rights of others or bring individuals into serious conflict with societal norms and authority figures. The clinical presentation of ICDs is broad, from less severe forms such as punding to more hazardous behaviors, such as PG and hypersexuality, which can pose considerable risks to personal and social well-being (6). Reports have indicated high prevalence rates of ICD ranging from 6% to 24% in patients undergoing therapy for PD (11,12). Although effective in controlling PRL levels, there is an emerging concern regarding the onset of ICDs in patients undergoing DA therapy. Even if the doses of DAs used in these instances are considerably 5-10 times lower than those used to treat PD or restless leg syndrome, distinct dopaminergic personality patterns have been described (13,14,15,16).

In adults treated with DAs for prolactinoma, the prevalence of ICD ranges between 8% and 61% (17,18,19,20). Our patient was an adolescent boy who developed PG as a side effect of CBG treatment. Similar case reports have described male patients with prolactinoma who developed PG while receiving CBG treatment (13,14,15). Males seem to have an increased risk of developing pathological hypersexuality and gambling, whereas females are more likely to exhibit compulsive eating and shopping behaviors in the general population (21).

In most reported studies, neither the DA dose (17,18,19,20,22) nor duration of therapy (17,19,23) were found to be associated with the occurrence of ICDs. In prolactinomas, the correlation between DA dosage and the emergence of ICDs is unclear. While Bancos et al. (17) observed that DA dosage did not play a significant role in ICD development, Barake et al. (23) observed an association between higher doses of CBG and increased impulsivity. In another study, even though patients with ICDs were on higher maintenance doses of CBG, the difference was not statistically significant (18). Furthermore, several case reports in adult patients with prolactinomas have indicated that ICDs may emerge even with low dose DAs (13,14,24). Our patient exhibited signs of PG while using 1.5 mg of CBG per week, and this dose is not considered high.

Gambling disorder is an addiction in which individuals engage in problematic gambling. The DSM-5 outlines that those affected by PG are driven to bet increasingly larger amounts of money to achieve the desired excitement and have repeatedly failed to control their gambling (24). ICDs and addictive disorders share similar brain processes, which implies that they might benefit from comparable treatment strategies. PG is categorized as an addiction due to its compulsive aspects, reflecting a shift in the most recent editions of diagnostic manuals, such as DSM-5 and ICD-11, where PG is classified as an addictive disorder rather than an ICD (6,24). The tendency for gambling may increase with the use of dopamine-related drugs because of the potential overstimulation of dopamine-dependent reward and reinforcement circuits in the brain (25,26,27). The use of DAs in the treatment of hyperprolactinemia is based on their effects on dopamine receptor isoforms, specifically D2 and D3. D2 receptors are key to inhibiting PRL release from the pituitary gland. D3 is highly expressed within the limbic system, ventral striatum, frontal cortex and thalamus (8). The mesocorticolimbic pathway, which begins in the ventral tegmental area and connects the limbic system and the frontal cortex, is thought to be involved in the development of DA-induced ICDs (28). The induction of ICDs is believed to be due to the activation of D3 dopamine receptors in the mesocorticolimbic pathway (8).

Although a correlation has been observed between DA therapy and PG, the development of PG symptoms can occur at different stages of DA therapy. Notably, these patients had no prior psychiatric history, and the symptoms occurred independent of the type of medication administered; that is BRC and CBG (13,14,18,27). However, data on this side effect in childhood are limited. In a case report by Thondam et al. (27), a 14-year-old girl with prolactinoma commenced BRC therapy, and two years after the initiation of therapy, she developed symptoms of PG. In contrast, a 19-year-old young adult developed gambling behavior shortly after beginning BRC for a giant prolactinoma (16). Another report described a 19-year-old boy who presented with signs of increased sexual behavior concurrently with the initiation of treatment with 4 mg CBG per week (28). In our case report, the manifestation of PG occurred two and half years after the initiation of CBG therapy, when the patient was on a dose regimen of 1.5 mg per week. This observation is consistent with the existing literature and suggests that the onset of PG is not

influenced by the dosage or initial timing of the treatment. In addition, our case report appears to be the first documented instance of PG developing in an adolescent undergoing treatment with CBG for prolactinoma, thereby expanding the understanding of such occurrences in this age group with this specific DA.

Currently, there are no published guidelines for the management of ICDs in patients with hyperprolactinemia receiving DA therapy. Studies have indicated that reducing the dose or cessation of DA therapy might be beneficial for those who develop ICDs (13,14,18,27). Owing to the side effects of DA therapy, it may be necessary to reduce the dose or discontinue the therapy. Patients with hyperprolactinemia who develop ICDs should be withdrawn from DA therapy or, at least, undergo DA dose reduction, as well as being considered for psychiatric consultation and cognitive behavioral therapy. It is also important to evaluate preexisting psychiatric disorders before prescribing DAs and to carefully follow up patients who are prone to or have a history of psychiatric disorders (5,25). Before considering cessation, a reduction in DA dosage should be attempted, as it could improve symptoms in certain patients. Switching between different DAs is generally not recommended, as it could lead to different ICDs, exemplified by a patient who developed compulsive gambling and eating when switching from BRC to CBG (15). Considering the current literature, we adopted a dose reduction strategy for our patient, who exhibited PG as a side effect of CBG therapy. Three months after the reduction in medication dose, the symptoms disappeared.

Conclusion

To the best of our knowledge, this is the first case of PG reported in an adolescent patient with a PRL-secreting macroadenoma who was receiving CBG treatment. This example demonstrates that ICDs are an important complication of dopaminergic therapy in patients with prolactinomas. Here, we wanted to highlight the need for careful monitoring of psychiatric symptoms in patients treated with DAs for prolactinomas, especially in the pediatric and adolescent age groups. It has been suggested that every patient who is prescribed DA, along with their family, should be informed about the possible side effects. This was done to ensure early recognition and prevent the development of severe financial and social issues. The occurrence of PG in this patient, without a prior psychiatric history, emphasizes the potential for DA-induced PG, irrespective of the DA dosage and duration of treatment.

Ethics

Informed Consent: Informed consent for publication was obtained from the patient's parents.

Footnotes

Authorship Contributions

Medical Practices: Ummahan Tercan, Özlem Nida Erbaşı, Mine Özkan, Concept: Ummahan Tercan, Ezgi Sarban, Design: Ummahan Tercan, Aslı Derya Kardelen, Data Collection or Processing: Ummahan Tercan, Melek Yıldız, Analysis or Interpretation: Ummahan Tercan, Aslı Derya Kardelen, Literature Search: Ummahan Tercan, Ezgi Sarban, Melek Yıldız, Writing: Ummahan Tercan, Ezgi Sarban, Melek Yıldız, Aslı Derya Kardelen, Şükran Poyrazoğlu, Firdevs Baş, Feyza Darendeliler.

Conflict of Interest: One author of this article, Feyza Darendeliler, is a member of the Editorial Board of the Journal of Clinical Research in Pediatric Endocrinology. However, she did not involved in any stage of the editorial decision of the manuscript. The editors who evaluated this manuscript are from different institutions. The other authors declared no conflict of interest.

Financial Disclosure: The authors declared that this study received no financial support.

References

1. Eren E, Yapıcı Ş, Çakır ED, Ceylan LA, Sağlam H, Tarım Ö. Clinical course of hyperprolactinemia in children and adolescents: a review of 21 cases. J Clin Res Pediatr Endocrinol. 2011;3:65-69. Epub 2011 Jun 8
2. Hoffmann A, Adelmann S, Lohle K, Claviez A, Müller HL. Pediatric prolactinoma: initial presentation, treatment, and long-term prognosis. Eur J Pediatr. 2018;177:125-132. Epub 2017 Nov 22
3. Fernandez A, Karavitaki N, Wass JA. Prevalence of pituitary adenomas: a community-based, cross-sectional study in Banbury (Oxfordshire, UK). Clin Endocrinol (Oxf). 2010;72:377-382. Epub 2009 Jul 24
4. Stumpf MAM, Pinheiro FMM, Silva GO, Cescato VAS, Musolino NRC, Cunha-Neto MBC, Glezer A. How to manage intolerance to dopamine agonist in patients with prolactinoma. Pituitary. 2023;26:187-196. Epub 2023 Apr 7
5. Petersenn S, Fleseriu M, Casanueva FF, Giustina A, Biermasz N, Biller BMK, Bronstein M, Chanson P, Fukuoka H, Gadelha M, Greenman Y, Gurnell M, Ho KKY, Honegger J, Ioachimescu AG, Kaiser UB, Karavitaki N, Katznelson L, Lodish M, Maiter D, Marcus HJ, McCormack A, Molitch M, Muir CA, Neggers S, Pereira AM, Pivonello R, Post K, Raverot G, Salvatori R, Samson SL, Shimon I, Spencer-Segal J, Vila G, Wass J, Melmed S. Diagnosis and management of prolactin-secreting pituitary adenomas: a Pituitary Society international Consensus Statement. Nat Rev Endocrinol. 2023;19:722-740. Epub 2023 Sep 5
6. Ioachimescu AG, Fleseriu M, Hoffman AR, Vaughan Iii TB, Katznelson L. Psychological effects of dopamine agonist treatment in patients with hyperprolactinemia and prolactin-secreting adenomas. Eur J Endocrinol. 2019;180:31-40.
7. Goudriaan AE, Oosterlaan J, de Beurs E, Van den Brink W. Pathological gambling: a comprehensive review of biobehavioral findings. Neurosci Biobehav Rev. 2004;28:123-141.
8. Barake M, Klibanski A, Tritos NA. Management of endocrine disease: impulse control disorders in patients with hyperpolactinemia treated

with dopamine agonists: how much should we worry? Eur J Endocrinol. 2018;179:R287-R296.

9. Fukuhara N, Nishiyama M, Iwasaki Y. Update in pathogenesis, diagnosis, and therapy of prolactinoma. Cancers (Basel). 2022;14:3604.

10. American Psychiatric Association. Diagnostic and statistical manual of mental disorders (5th ed.). Arlington, VA: American Psychiatric Publishing; 2013. https://doi.org/10.1176/appi.books.9780890425596

11. Weintraub D, Koester J, Potenza MN, Siderowf AD, Stacy M, Voon V, Whetteckey J, Wunderlich GR, Lang AE. Impulse control disorders in Parkinson disease: a cross-sectional study of 3090 patients. Arch Neurol. 2010;67:589-595.

12. Weiss HD, Marsh L. Impulse control disorders and compulsive behaviors associated with dopaminergic therapies in Parkinson disease. Neurol Clin Pract. 2012;2:267-274.

13. Falhammar H, Yarker JY. Pathological gambling and hypersexuality in cabergoline-treated prolactinoma. Med J Aust. 2009;190:97.

14. Davie M. Pathological gambling associated with cabergoline therapy in a patient with a pituitary prolactinoma. J Neuropsychiatry Clin Neurosci. 2007;19:473-474.

15. Almanzar S, Zapata-Vega MI, Raya JA. Dopamine agonist-induced impulse control disorders in a patient with prolactinoma. Psychosomatics. 2013;54:387-391. Epub 2012 Dec 20

16. Athanasoulia-Kaspar AP, Popp KH, Stalla GK. Neuropsychiatric and metabolic aspects of dopaminergic therapy: perspectives from an endocrinologist and a psychiatrist. Endocr Connect. 2018;7:R88-R94. Epub 2018 Jan 29

17. Bancos I, Nannenga MR, Bostwick JM, Silber MH, Erickson D, Nippoldt TB. Impulse control disorders in patients with dopamine agonist-treated prolactinomas and nonfunctioning pituitary adenomas: a case-control study. Clin Endocrinol (Oxf). 2014;80:863-868. Epub 2013 Dec 16

18. Dogansen SC, Cikrikcili U, Oruk G, Kutbay NO, Tanrikulu S, Hekimsoy Z, Hadzalic A, Gorar S, Omma T, Mert M, Akbaba G, Yalin GY, Bayram F, Ozkan M, Yarman S. Dopamine agonist-induced impulse control disorders in patients with prolactinoma: a cross-sectional multicenter study. J Clin Endocrinol Metab. 2019;104:2527-2534.

19. De Sousa SMC, Baranoff J, Rushworth RL, Butler J, Sorbello J, Vorster J, Thompson T, McCormack AI, Inder WJ, Torpy DJ. Impulse control disorders in dopamine agonist-treated hyperprolactinemia: prevalence and risk factors. J Clin Endocrinol Metab. 2020;105:dgz076.

20. Celik E, Ozkaya HM, Poyraz BC, Saglam T, Kadioglu P. Impulse control disorders in patients with prolactinoma receiving dopamine agonist therapy: a prospective study with 1 year follow-up. Endocrine. 2018;62:692-700. Epub 2018 Sep 11

21. Fattore L, Melis M. Sex differences in impulsive and compulsive behaviors: a focus on drug addiction. Addict Biol. 2016;21:1043-1051. Epub 2016 Mar 3

22. Beccuti G, Guaraldi F, Natta G, Cambria V, Prencipe N, Cicolin A, Montanaro E, Lopiano L, Ghigo E, Zibetti M, Grottoli S. Increased prevalence of impulse control disorder symptoms in endocrine diseases treated with dopamine agonists: a cross-sectional study. J Endocrinol Invest. 2021;44:1699-1706. Epub 2020 Dec 12

23. Barake M, Evins AE, Stoeckel L, Pachas GN, Nachtigall LB, Miller KK, Biller BM, Tritos NA, Klibanski A. Investigation of impulsivity in patients on dopamine agonist therapy for hyperprolactinemia: a pilot study. Pituitary. 2014;17:150-156.

24. Grant JE, Chamberlain SR. Expanding the definition of addiction: DSM-5 vs. ICD-11. CNS Spectr. 2016;21:300-303. Epub 2016 May 6

25. Wolfschlag M, Håkansson A. Drug-induced gambling disorder: epidemiology, neurobiology, and management. Pharmaceut Med. 2023;37:37-52. Epub 2023 Jan 7

26. Balarajah S, Cavanna AE. The pathophysiology of impulse control disorders in Parkinson disease. Behav Neurol. 2013;26:237-244.

27. Thondam SK, Alusi S, O'Driscoll K, Gilkes CE, Cuthbertson DJ, Daousi C. Impulse control disorder in a patient on long-term treatment with bromocriptine for a macroprolactinoma. Clin Neuropharmacol. 2013;36:170-172.

28. Bulwer C, Conn R, Shankar A, Ferrau F, Kapur S, Ederies A, Korbonits M, Spoudeas HA. Cabergoline-related impulse control disorder in an adolescent with a giant prolactinoma. Clin Endocrinol (Oxf). 2017;86:862-864. Epub 2017 Apr 24

CASE REPORT

JCRPE Journal of Clinical Research in Pediatric Endocrinology

DOI: 10.4274/jcrpe.galenos.2025.2024-10-6
J Clin Res Pediatr Endocrinol 2026;18(Suppl 1):70-74

Atypical Presentation of New Onset Diabetes with Hyperglycemic Hyperosmolar State in Two Toddlers

Alina Haque[1], Esther E. Bell-Sambataro[2], Foram Patel[3], Leena Mamilly[4], Kathryn Obrynba[4], Jennifer M. Ladd[4]

[1]The Ohio State University Faculty of Medicine, Columbus, Ohio, United States
[2]Johns Hopkins All Children's Hospital, St. Petersburg, Florida, United States
[3]UT Southwestern Medical Center, Department of Pediatrics, Division of Pediatric Endocrinology, Dallas, Texas, United States
[4]Nationwide Children's Hospital, Department of Pediatrics, Division of Pediatric Endocrinology, Columbus, Ohio, United States

Cite this article as: Haque A, Bell-Sambataro EE, Patel F, Mamilly L, Obrynba K, Ladd JM. Atypical presentation of new onset diabetes with hyperglycemic hyperosmolar state in two toddlers. J Clin Res Pediatr Endocrinol. 2026;18(Suppl 1):70-74

What is already known on this topic?

Hyperglycemic hyperosmolar state (HHS), or mixed HHS with diabetic ketoacidosis (DKA), is a rare complication of diabetes in children. It is most often seen in older children and adolescents and is associated with significant morbidity and mortality.

What this study adds?

This manuscript highlights two of the youngest patients ever reported with HHS and mixed HHS-DKA at new onset of diabetes. Although rare in toddlers, HHS must be considered upon presentation with severe hyperglycemia. Developmental delay may further increase risk of hyperosmolality given the inability to adequately express thirst and access fluids at younger ages.

ABSTRACT

Hyperglycemic hyperosmolar state (HHS), or mixed HHS with diabetic ketoacidosis (DKA), is a rare complication of diabetes in children. Prompt recognition of hyperosmolality is necessary to prevent morbidity and mortality. We report two of the youngest cases with HHS, both presenting as new onset of type 1 diabetes. The first was a 3-year-4-month-old male with autism spectrum disorder who presented with glucose 76.0 mmol/L (1370 mg/dL), calculated serum osmolality 388 mOsm/kg, and trace urinary ketones, consistent with HHS and complicated by acute kidney injury. The second was a 4-year-7-month-old male with Trisomy 21 and autism spectrum disorder who presented with glucose 117.3 mmol/L (2114 mg/dL), calculated serum osmolality 401 mOsm/kg, and elevated serum β-hydroxybutyrate, consistent with mixed HHS-DKA and complicated by acute kidney injury and pancreatitis. Both received aggressive rehydration although hyperosmolality was initially overlooked,

Corresponding Author: Jennifer M. Ladd, MD, MSc, Nationwide Children's Hospital, Department of Pediatrics, Division of Pediatric Endocrinology, Columbus, Ohio, United States
E-mail: jennifer.ladd@nationwidechildrens.org **ORCID:** orcid.org/0009-0005-1949-4367
Conflict of interest: None declared
Received: 20.12.2024 **Accepted:** 12.02.2025 **Epub:** 08.05.2025 **Publication Date:** 02.06.2026

©Copyright 2026 by Turkish Society for Pediatric Endocrinology and Diabetes / The Journal of Clinical Research in Pediatric Endocrinology published by Galenos Publishing House.
Licensed under a Creative Commons Attribution-NonCommercial-NoDerivatives 4.0 (CC BY-NC-ND) International License.

resulting in earlier and higher insulin dosing more typical of DKA than HHS. Both recovered without sequelae. In each case, young age and developmental delay likely contributed to hyperosmolality, given the inability to communicate increased thirst and freely access water. A high index of suspicion for HHS is necessary as significant rehydration and delayed start of low dose insulin infusion are recommended to prevent complications.

Keywords: Developmental delay, hyperglycemic hyperosmolar state, pediatrics, type 1 diabetes

Introduction

New onset diabetes mellitus in young children can initially go unrecognized given the inability to verbalize symptoms such as thirst, lack of free access to fluids, and lack of toilet training, which can mask urinary frequency. As a result, young children have the highest prevalence of diabetic ketoacidosis (DKA) at presentation of new onset diabetes, with 46.7% of children aged 0-4 years presenting in DKA in the SEARCH for Diabetes in Youth Study including over 7,000 children in the United States (1,2). Hyperglycemic hyperosmolar state (HHS), another complication of diabetes with more severe hyperglycemia and dehydration, has less frequently been reported in children, with one single center study of 390 youth aged 0-21 years showing only 0.8% presenting in HHS and 13.8% presenting in mixed HHS-DKA (3).

Prompt distinction between HHS and DKA, and identification of mixed states, is critical given that different treatment considerations are applied for each entity and given the higher rates of morbidity and mortality in HHS or mixed HHS-DKA compared to DKA alone (4,5). Herein, we present two of the youngest reported cases of toddlers presenting with new onset diabetes with hyperosmolality. Understanding the distinctive features of these cases can facilitate earlier recognition of HHS and mixed HHS-DKA in very young children and thus guide earlier appropriate treatment to minimize complications.

Case Report

Case 1

A 3-year-4-month-old nonverbal male with autism spectrum disorder presented to an outside hospital emergency department with fatigue and decreased activity level. On the day of presentation, he had one episode of emesis as well as heavy breathing. He was not on daily medications. Initial vital signs were significant for tachycardia [140 beats per minute (bpm)] and hypoxia [oxygen saturation (SpO_2) as low as 78%] with respiratory rate of 20 breaths per minute. Physical examination revealed decreased responsiveness, sunken eyes, and dry oral mucosa, although lungs were clear to auscultation. Initial laboratory investigation showed severely elevated serum glucose of 76.0 mmol/L (1370 mg/dL) with measured hypernatremia of 149 mmol/L (corrected sodium 169 mmol/L) and calculated serum osmolality 388 mOsm/kg. Venous blood gas was without acidosis (pH 7.40, pCO_2 31 mmHg, and bicarbonate 19 mmol/L), and urinary ketones were trace. Hemoglobin A1c (HbA1c) was 72 mmol/mol (8.7%) (Table 1). Respiratory viral antigen testing was positive for parainfluenza. Upon further discussion, parents noted increased urine output and increased intake of PediaSure® and 2% milk over the preceding three days.

The patient was started on supplemental oxygen via nasal cannula. Initial resuscitation consisted of a 20 mL/kg normal saline bolus given over one hour and followed by a second 20 mL/kg normal saline bolus one hour after initial bolus. This was followed by isotonic intravenous (IV) fluids at 1.5 times maintenance rate. Additional results were consistent with acute kidney injury [initial creatinine 61.9 mmol/L (0.7 mg/dL)]. IV insulin infusion was started at 0.1 units/kg/hr, and the patient was transferred to our emergency department.

On arrival at our hospital, point-of-care blood glucose was 15.2 mmol/L (273 mg/dL). Given this rapid decline in blood glucose level, and given that it was then recognized that the initial presentation was consistent with HHS rather than DKA, the insulin drip was temporarily paused while IV rehydration with isotonic fluids was increased to twice maintenance rate. Upon stabilization of serum glucose, the IV insulin drip was resumed at 0.025 units/kg/hr and continued until transition to subcutaneous insulin 12 hours after presentation (Figure 1). Serum creatinine normalized with rehydration. He was monitored for development of rhabdomyolysis and pancreatitis; serum creatinine kinase and lipase remained normal throughout the hospitalization. He did not have any clinical evidence of cerebral edema or venous thrombosis.

At the time of discharge, he required a total daily dose of 0.4 units/kg/day of basal-bolus subcutaneous insulin. Islet antigen 2 antibody and anti-insulin antibodies were positive, consistent with a diagnosis of type 1 diabetes.

Case 2

A 4-year-7-month-old nonverbal male with Trisomy 21, autism spectrum disorder, duodenal atresia status post repair, cholestasis, and bilateral cystic kidney disease presented to our emergency department with lethargy and respiratory distress. Daily medications included prophylactic sulfamethoxazole-trimethoprim, ursodiol, and polyethylene glycol. Initial vital signs were notable for tachycardia (heart rate 144 bpm), but no tachypnea (respiratory rate 18 breaths per minute) or hypoxia

J Clin Res Pediatr Endocrinol
2026;18(Suppl 1):70-74

Table 1. Initial laboratory values at presentation

	Case 1	Case 2	Reference range
Serum glucose	76.0 (1370)	117.3 (2114)	3.3-6.4 mmol/L (60-115 mg/dL)
Venous pH	7.40	7.15	7.32-7.42
pCO_2	31	50	33-46 mmHg
Bicarbonate	19	19	21-30 mmol/L
Measured sodium	149	134	135-145 mmol/L
Corrected sodium[a]	169	166	135-145 mmol/L
Calculated serum osmolality[b]	388	401	271-296 mOsm/kg
Serum βhydroxybutyrate[c]	--	4.4	<0.3 mmol/L
Hemoglobin A1c	72 (8.7)	89 (10.3)	20-38 mmol/mol (4.0-5.6%)
Creatinine	61.9 (0.7)	123.8 (1.4)	17.7-35.4 mmol/L (0.2-0.4 mg/dL)
Lipase	4	7740	<202 U/L

[a]Corrected sodium calculated as 1.6*(serum glucose in mg/dL-100)/100+measured sodium,
[b]Calculated serum osmolality as 2*measured sodium+serum glucose in mg/dL/18+BUN/2.8,
[c]Serum βhydroxybutyrate not measured at presentation in Case 1; urinary ketones were trace at presentation in Case 1.
BUN: blood urea nitrogen

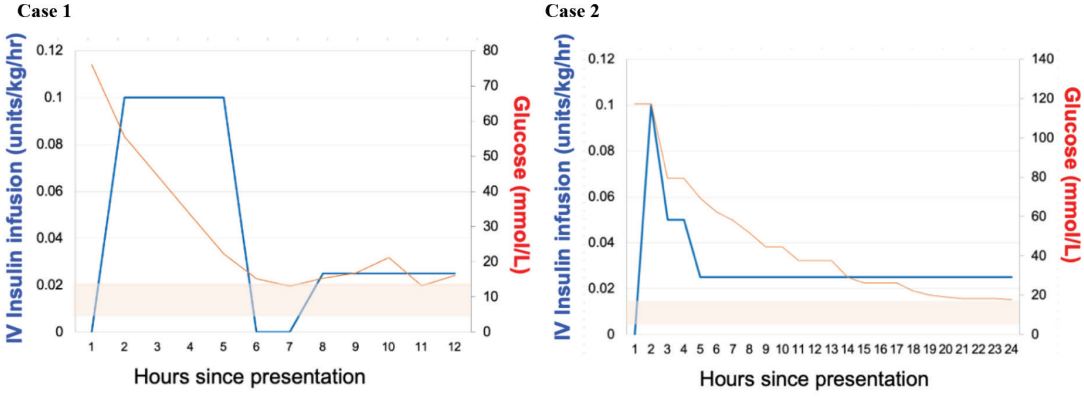

Figure 1. Trends of blood glucose decline and IV insulin dosing
Note: Blue lines show IV insulin infusion rates. Red lines show blood glucose levels, with shaded red area representing target blood glucose range [5.6-11.1 mmol/L (100-200 mg/dL)] while on insulin infusion
IV: intravenous

(SpO_2 97%). Physical examination revealed somnolence, dry oral mucosa, clear lungs, and a diffusely tender abdomen. Initial laboratory testing revealed markedly elevated serum glucose of 117.3 mmol/L (2114 mg/dL) with hypernatremia (measured sodium 134 mmol/L with corrected sodium 166 mmol/L). Venous blood gas was consistent with a predominant respiratory acidosis (pH 7.15, pCO_2 50 mmHg, and bicarbonate 19 mmol/L), and serum β-hydroxybutyrate was elevated at 4.4 mmol/L. Calculated serum osmolality at presentation was 401 mOsm/kg. HbA1c was 89 mmol/mol (10.3%) (Table 1). Chest X-ray was unremarkable, and all infectious testing was negative. Upon more detailed history, parents noted polyuria over the prior week and had offered water and diluted juice.

The patient was started on bilevel positive airway pressure due to initial hypercapnia and respiratory distress. Initial resuscitation consisted of a total of two 20 mL/kg normal saline boluses, each given over one hour sequentially, followed by isotonic IV fluids at twice maintenance rate. IV insulin infusion was initially started at 0.1 units/kg/hr, but was soon thereafter decreased to 0.025 units/kg/hr given later recognition that initial evaluation was consistent with mixed HHS-DKA, as well as a component of respiratory acidosis (Figure 1). Additional results were consistent with pancreatitis (initial serum lipase 7740 U/L in the context of diffuse abdominal pain), which may have contributed to the respiratory acidosis on presentation. Laboratory testing also showed acute kidney injury [initial creatinine 123.8 mmol/L (1.4 mg/dL)]. IV insulin infusion was

continued at 0.025 units/kg/hr for 36 hours until resolution of pancreatitis, normalization of sodium, and clinical improvement occurred. Serum creatinine normalized with rehydration, and serial creatine kinase levels remained normal without evidence of rhabdomyolysis. He did not have signs of cerebral edema clinically or on cranial computed tomography. No physical signs of venous thrombosis were present. After transition from IV insulin to subcutaneous insulin, he was noted to have marked insulin resistance, requiring a total daily dose of 1.7 units/kg/day of basal-bolus subcutaneous insulin on discharge from the hospital.

Further work-up revealed negative pancreatic autoantibodies including glutamic acid decarboxylase-65, islet antigen 2, anti-insulin, and zinc transporter 8. A monogenetic diabetes panel of 18 genes including *HNF1β* was obtained due to negative autoantibodies and history of renal cysts; the panel was negative for any mutations. He is therefore currently managed as having antibody negative type 1 diabetes in the setting of Trisomy 21. Now 1.5 years after diagnosis, he is requiring a more typical 0.7 units/kg/day of insulin through an automated insulin delivery system, with his most recent HbA1c of 52 mmol/mol (6.9%).

Discussion

The two cases described herein represent two of the youngest reported patients with HHS in the literature (6,7,8,9,10). The first case had a more classical presentation of HHS with minimal ketosis and without acidosis, whereas the second case had mixed features of both HHS and DKA. Both patients received significant fluid resuscitation on arrival given clinical evidence of dehydration, but the features of hyperosmolality and HHS were not immediately recognized in such young and developmentally delayed patients. Given positive autoantibodies in the first patient and negative genetic testing in the second patient, both toddlers were presumed to have new onset type 1 diabetes.

Although DKA has often been thought to be associated with type 1 diabetes and HHS with type 2 diabetes, either form of diabetes can present with DKA, HHS, or a mixed picture. The diagnosis of HHS, or mixed HHS-DKA, in a young child therefore requires a high index of suspicion and is of critical importance due to its implications for prognosis, management, and complications (11,12). Both HHS and DKA present with hyperglycemia, but differ in pathophysiology and risk of complications, leading to differences in initial management. In DKA, there is an absolute paucity of insulin production, resulting in hyperglycemia and ketone production through lipolysis. The diagnostic criteria for DKA include a serum glucose concentration greater than 11.1 mmol/L (200 mg/dL), metabolic acidosis with a venous pH less than 7.3 or serum bicarbonate less than 18 mmol/L, and ketonemia (serum β-hydroxybutyrate greater than 3 mmol/L or moderate-to-large urine ketones) (11). Conversely, in HHS, increased gluconeogenesis and glycogenolysis occur, resulting in very high serum glucose levels, but the body maintains enough circulating insulin to prevent ketone formation (5). The diagnostic criteria of HHS include a serum glucose concentration greater than 33.3 mmol/L (600 mg/dL), serum osmolality greater than 320 mOsm/kg, and absence of significant ketosis and acidosis (11). Presentation can also be mixed, meeting criteria for both HHS and DKA. HHS is most often described in older children and adolescents and is exceedingly rare in younger children, with an incidence rate of 3.2 per 1,000,000 children in 2009 in a large hospital discharge database in the United States (13).

The distinction between HHS and DKA, and the prompt recognition of the presence of each, is crucial for appropriate treatment. The total body fluid deficit in HHS is more severe than in DKA, but this may not always be clinically appreciated as hypertonicity relatively preserves intravascular volume (14). Therefore, more aggressive fluid resuscitation is required in HHS than in DKA to prevent circulatory collapse and maintain intravascular volume as hypertonicity declines, thereby allowing fluids to move to the extravascular space (14). For this reason, unlike in DKA, insulin infusion in HHS should be delayed until adequate initial volume resuscitation has been achieved and serum glucose is no longer declining with hydration alone, although earlier insulin administration can be considered in mixed HHS-DKA (11,14). Lower rates of insulin infusion may also be needed to prevent a rapid decline in blood glucose levels which may contribute to large fluid shifts (14). In both cases presented here, IV insulin infusions were initially started at rates more typical for DKA after primary resuscitation. In the first case, the insulin infusion was halted upon recognition of significant hyperosmolality with minimal ketosis and then restarted at a much lower dose to prevent continued rapid decline in blood glucose. In the second case of mixed HHS-DKA, earlier insulin administration was likely appropriate given ketosis, although the rate was decreased to again preserve a slower decline in blood glucose.

In addition to more pronounced electrolyte imbalances, other complications are more likely to be present in HHS than in DKA including rhabdomyolysis, pancreatitis, venous thrombosis, acute kidney injury, and malignant hyperthermia, all of which can contribute to morbidity and likely account for the 10-fold higher mortality in HHS or mixed HHS-DKA than in DKA alone (4,5,12,14). Although both cases here had acute kidney injury at presentation and the second case also had evidence of pancreatitis, neither patient developed rhabdomyolysis, venous thrombosis, cerebral edema, or circulatory collapse.

J Clin Res Pediatr Endocrinol
2026;18(Suppl 1):70-74

In both cases, young age and developmental delay likely contributed to marked hyperglycemia and hyperosmolality, as well as overt dehydration, at presentation. Both patients were non-verbal, leading to the inability to clearly communicate increased thirst, and given their young ages, neither were able to freely access water. Both toddlers were also inadvertently provided high carbohydrate-containing liquids (including diluted juice and PediaSure®), which likely exacerbated the severe underlying hyperglycemia. Developmental delay has been reported to be a contributor to presentation of HHS in published case reports, although these children were all older (7,10). In a single center study of 390 youth presenting with diabetes, those with intellectual disability, including developmental delay, were also found to have 3.4 higher odds of hyperosmolality compared to those without this disability (3). Thus, increased awareness of the potential for HHS, or mixed HHS-DKA, upon presentation with new onset diabetes in those with developmental delay, including at very young ages, is necessary to reduce the likelihood of delayed treatment and complications.

Conclusion

We have highlighted two cases, one of HHS and one of mixed HHS-DKA in toddlers, an age group in which hyperosmolality is rare. Providers should have a high index of suspicion for HHS and mixed HHS-DKA in young patients who present with a glucose greater than 33.3 mmol/L (600 mg/dL), given the differing management considerations and complications in HHS as compared to DKA alone. This suspicion should be heightened in those with developmental delay, given the increased risk of hyperosmolality and delayed recognition of symptoms. Prompt management of HHS with aggressive fluid resuscitation and delayed start of low dose insulin infusion is recommended.

Ethics

Informed Consent: Consent was obtained from the patient's parents.

Footnotes

Prior Presentations: The second case was presented as a peer-reviewed abstract at the Canadian Pediatric Endocrine Group 2023 annual meeting and the Pediatric Endocrine Society 2023 annual meeting.

Authorship Contributions

Concept: Esther E. Bell-Sambataro, Foram Patel, Leena Mamilly, Kathryn Obrynba, Jennifer M. Ladd, Design: Esther E. Bell-Sambataro, Foram Patel, Leena Mamilly, Kathryn Obrynba, Jennifer M. Ladd, Data Collection or Processing: Esther E. Bell-Sambataro, Foram Patel, Leena Mamilly, Kathryn Obrynba, Jennifer M. Ladd, Literature Search: Alina Haque, Esther E. Bell-Sambataro, Foram Patel, Leena Mamilly, Jennifer M. Ladd, Writing: Alina Haque, Esther E. Bell-Sambataro, Foram Patel, Leena Mamilly, Kathryn Obrynba, Jennifer M. Ladd.

Financial Disclosure: The authors declared that this study received no financial support.

References

1. Jensen ET, Stafford JM, Saydah S, D'Agostino RB, Dolan LM, Lawrence JM, Marcovina S, Mayer-Davis EJ, Pihoker C, Rewers A, Dabelea D. Increase in prevalence of diabetic ketoacidosis at diagnosis among youth with type 1 diabetes: The SEARCH for diabetes in youth study. Diabetes Care. 2021;44:1573-1578. Epub 2021 Jun 7
2. Alonso GT, Coakley A, Pyle L, Manseau K, Thomas S, Rewers A. Diabetic ketoacidosis at diagnosis of type 1 diabetes in Colorado children, 2010-2017. Diabetes Care. 2020;43:117-121. Epub 2019 Oct 10
3. Agrawal S, Baird GL, Quintos JB, Reinert SE, Gopalakrishnan G, Boney CM, Topor LS. Pediatric diabetic ketoacidosis with hyperosmolarity: clinical characteristics and outcomes. Endocr Pract. 2018;24:726-732. Epub 2018 Aug 7
4. Simon R, Shah A, Shah B. Hyperosmolar nonketotic hyperglycemia. Pediatr Rev. 2024;45:169-171.
5. Pasquel FJ, Umpierrez GE. Hyperosmolar hyperglycemic state: a historic review of the clinical presentation, diagnosis, and treatment. Diabetes Care. 2014;37:3124-3131.
6. Cho YM, Park BS, Kang MJ. A case report of hyperosmolar hyperglycemic state in a 7-year-old child: an unusual presentation of first appearance of type 1 diabetes mellitus. Medicine (Baltimore). 2017;96:e7369.
7. Butorac Ahel I, Severinski S, Lah Tomulic K, Milardovic A, Baraba Dekanic K, Palcevski D. An extremely high blood glucose level in a child with hyperglycemic hyperosmolar state and type 1 diabetes. J Pediatr Endocrinol Metab. 2021;34:1045-1048.
8. Alharfi IM, Singh R, Clarson C, Foster JR. Hyperosmolar hyperglycemic state without ketosis in a toddler with type 1 diabetes. Pediatr Emerg Care. 2014;30:485-487.
9. Goldman SL. Hyperglycemic hyperosmolar coma in a 9-month-old child. Am J Dis Child. 1979;133:181-183.
10. Parra Villasmil MG, Patel S, Tansey M, Badheka A, Chegondi M. A Rare presentation of new-onset type 1 diabetes mellitus in a developmentally delayed child with an overlap of diabetic ketoacidosis and hyperglycemic hyperosmolar state. Cureus. 2022;14:e28983.
11. Glaser N, Fritsch M, Priyambada L, Rewers A, Cherubini V, Estrada S, Wolfsdorf JI, Codner E. ISPAD clinical practice consensus guidelines 2022: Diabetic ketoacidosis and hyperglycemic hyperosmolar state. Pediatr Diabetes. 2022;23:835-856.
12. Zarse E, Knoll MM, Halpin K, Thompson M, Williams DD, Tallon EM, Kallanagowdar G, Tsai S. Recognizing complications in youth with diabetes admitted with diabetic ketoacidosis versus hyperglycemic hyperosmolar state. J Pediatr Health Care. 2024;38:761-768. Epub 2024 Jun 18
13. Bagdure D, Rewers A, Campagna E, Sills MR. Epidemiology of hyperglycemic hyperosmolar syndrome in children hospitalized in USA. Pediatr Diabetes. 2013;14:18-24. Epub 2012 Aug 28
14. Zeitler P, Haqq A, Rosenbloom A, Glaser N; Drugs and Therapeutics Committee of the Lawson Wilkins Pediatric Endocrine Society. Hyperglycemic hyperosmolar syndrome in children: pathophysiological considerations and suggested guidelines for treatment. J Pediatr. 2011;158:9-14, 14.e1-e2. Epub 2010 Oct 30

CASE REPORT

JCRPE Journal of Clinical Research in Pediatric Endocrinology

DOI: 10.4274/jcrpe.galenos.2025.2024-10-12
J Clin Res Pediatr Endocrinol 2026;18(Suppl 1):75-82

Thauvin-Robinet-Faivre Syndrome: A *FIBP* Variant in an Adolescent with Segmental Overgrowth and Thyroid Carcinoma

Ülkü Gül Şiraz[1], Deniz Koçak Göl[2], Meino Rohlfs[3], Christoph Klein[3], Ekrem Ünal[4], Nihal Hatipoğlu[1]

[1]Erciyes University Faculty of Medicine, Department of Pediatric Endocrinology, Kayseri, Türkiye
[2]Erciyes University Faculty of Medicine, Department of Pediatric Hematology-Oncology, Kayseri, Türkiye
[3]Ludwig-Maximilians-University, Genetic Dr. Von Hauner Children's Hospital, Department of Pediatrics, Lindwurmstr, Munich, Germany
[4]Hasan Kalyoncu University Faculty of Health Sciences; Medical Point Hospital, Department of Pediatric Hematology Oncology and Bone Marrow Transplantation Unit, Gaziantep, Türkiye

Cite this article as: Şiraz ÜG, Koçak Göl D, Rohlfs M, Klein C, Ünal E, Hatipoğlu N. Thauvin-Robinet-Faivre syndrome: a *FIBP* variant in an adolescent with segmental overgrowth and thyroid carcinoma. J Clin Res Pediatr Endocrinol. 2026;18(Suppl 1):75-82

What is already known on this topic?

Overgrowth syndromes are rare diseases seen in pediatric endocrinology clinics. Those affecting growth factor pathways may present with body parts or limb hypertrophy and a predisposition to malignancy, including endocrine organs. *Fibroblast growth factor 1 intracellular binding protein* gene variants cause Thauvin-Robinet-Faivre syndrome (TROFAS), a new disease defined in this pathway.

What this study adds?

The present case represents the ninth instance of TROFAS reported worldwide and the fifth from Türkiye, contributing to the literature in terms of clinical findings and clinical presentations in cases with suspected tumor predisposition.

ABSTRACT

Overgrowth syndromes are rare genetic disorders arising from alterations in the growth factors pathway. These syndromes can present as generalized overgrowth, characterized by macrosomia and excessive height compared to peers, or partial overgrowth syndromes, where specific body regions exhibit disproportionate growth often accompanied by vascular anomalies. Both forms are associated with an increased risk of tumor development. The *fibroblast growth factor 1 (FGF-1) intracellular binding protein (FIBP)* gene plays a critical role in cell proliferation and differentiation by interacting with growth factors. In this article, we present a case of Thauvin-Robinet-Faivre syndrome (TROFAS) in a 16-year-old girl, diagnosed with homozygous NM_004214.5 c.412-3_415dup (p. Asp139AIafsTer3) variant in the *FIBP* gene. This case exhibits

Corresponding Author: Prof. Nihal Hatipoglu, Erciyes University Faculty of Medicine, Department of Pediatric Endocrinology, Kayseri, Türkiye
E-mail: nihalhatipoglu@yahoo.com **ORCID:** orcid.org/0000-0002-0991-6539
Conflict of interest: None declared
Received: 23.10.2024 **Accepted:** 13.03.2025 **Epub:** 18.03.2025 **Publication Date:** 02.06.2026

©Copyright 2026 by Turkish Society for Pediatric Endocrinology and Diabetes / The Journal of Clinical Research in Pediatric Endocrinology published by Galenos Publishing House.
Licensed under a Creative Commons Attribution-NonCommercial-NoDerivatives 4.0 (CC BY-NC-ND) International License.

phenotypic features and tumor development, including thyroid follicular carcinoma and parotid mucoepidermoid carcinoma, that have not been previously reported in association with this syndrome. Recent studies have implicated *FIBP* gene defects in overgrowth syndromes, with only a limited number of cases described globally. This case expands the known clinical and tumor spectrum associated with TROFAS, providing new insights into the pathophysiology of this rare disorder.

Keywords: Overgrowth syndromes, *FGF-1 intracellular binding protein (FIBP)* gene, cancer

Introduction

Overgrowth syndromes comprise a diverse group of disorders characterized by prenatal overgrowth, persistent postnatal overgrowth in both weight and height, segmental overgrowth, congenital malformations, intellectual disability, and in some cases, an increased risk of neoplasia. Segmental overgrowth refers to excessive growth localized to specific body regions, such as a single digit, an extremity, one side of the face, or the head (macrocephaly). It often presents as asymmetrical overgrowth of musculoskeletal, adipose or brain tissue, vascular malformations and/or overlying skin lesions. This phenotype is frequently associated with mosaic variants in the phosphoinositide-3-kinase-protein kinase B (PI3K/AKT)/mammalian target of rapamycin (mTOR) pathway, a key signaling cascade activated by growth factors such as insulin-like growth factor-1 (IGF-1), vascular endothelial growth factor (VEGF), and epidermal growth factor (EGF) (1,2,3).

The *fibroblast growth factor 1* (*FGF-1*) *intracellular binding protein* (*FIBP*) gene, located on chromosome 11q13.1, is expressed in the membranes of microsomes and mitochondria within the cytoplasm and nucleus (4). The interaction between FGFs and their receptors (FGFRs) plays a crucial role in multiple biological processes, including embryogenesis, neuronal development, and the formation of bone, cartilage, and vascular structures (4,5).

Thauvin-Robinet-Faivre Syndrome (TROFAS) is a rare autosomal recessive disorder caused by biallelic pathogenic variants in the *FIBP* gene. TROFAS (OMIM: 617107) is characterized by a broad spectrum of phenotypic features, including mild to severe learning difficulties, distinctive facial dysmorphisms, enlarged hands and feet, generalized overgrowth, and a predisposition to various congenital anomalies affecting the heart, eyes, kidneys, and skeleton. Only eight cases of TROFAS have been reported worldwide, making it a largely under-recognized condition with limited available literature (6,7,8,9).

Here, we present the case of a 16-year-old female patient diagnosed with a homozygous likely pathogenic variant in the *FIBP* gene, born to consanguineous parents. This case is particularly notable due to the malignancies and distinct clinical features not previously described in other reported TROFAS cases.

Case Report

A 16-year-old female presented with a six-month history of swelling on the right side of her neck and chin. She had previously undergone surgery at another hospital, where a right hemithyroidectomy and excision of a right parotid mass were performed. Histopathological examination revealed thyroid follicular carcinoma and a low-grade mucoepidermoid carcinoma of the parotid gland.

The patient was born at full term to consanguineous parents, with a birth weight of 2800 g. Her neuromotor developmental history was notable for significant delays; she began walking at the age of 3 years and started speaking between 6 and 7 years of age. The family history included two healthy siblings, one sister with congenital heart disease, and two siblings who died in the neonatal period for unknown reasons.

On physical examination, her weight was 59.6 kg (66th percentile), height was 159.3 cm (29th percentile), and body mass index was 23.5 kg/m^2 (79th percentile). Her head circumference measured 56.8 cm (77th percentile). Sitting height was 85 cm, with a sitting height-to-height ratio of 0.53 (within the normal range). Her arm span was 163 cm, with an arm span-height difference of 4 cm [+1 standard deviation (SD) to +2 SD]. Pubertal assessment was consistent with Tanner stage 5; she had menarche at 12.5 years, and her menstrual cycles were regular.

Notable facial features included a flat midface, mild right ptosis, low palpebral fissures, deep-set eyes, thick lips, thick and broad eyebrows with mild synophrys, a pointed chin, a prominent nasal bridge, a narrow forehead, a high palate, posteriorly rotated ears, and raised earlobes. Skeletal examination revealed mild pectus excavatum and pes planus. In addition, she had enlarged hands and feet, broad port-wine stains on her arms and legs, and varicose veins in both legs. Syndactyly was present between the second and third toes on the left foot, and a flexion contracture was noted between the first and second phalanges of the third finger on the right hand, which developed following hemangioma surgery (Figure 1 and 2). Numerous nevi were also observed on her face and trunk. The patient had an intellectual disability.

Parental heights were 155 cm (-3.4 SD) for the father and 157 cm (-1.04 SD) for the mother. Her 25-year-old brother's height was 169 cm (-1.17 SD), and her 20-year-old sister's height was

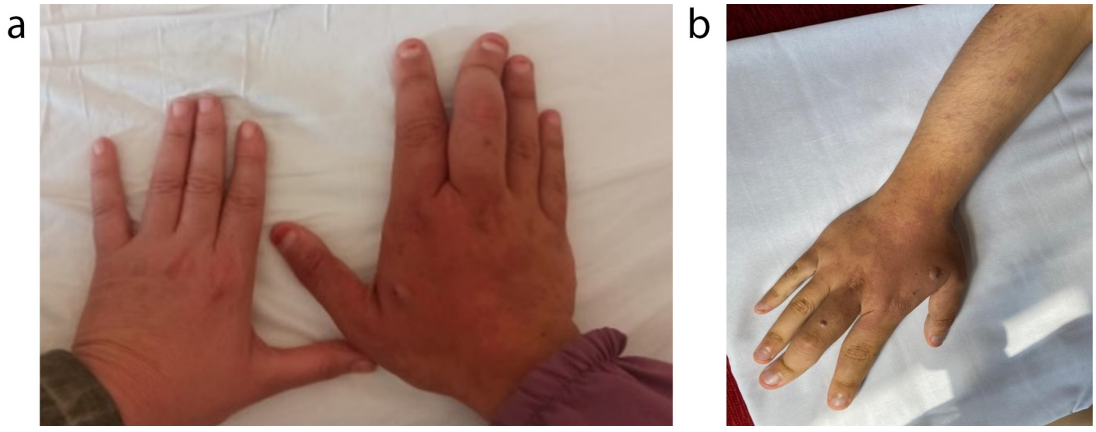

Figure 1. a) The patient's hand is noticeably larger than a normal hand. **b)** Capillary malformation (Port--wine Stain) on the hand extending to the arm and contracture of the fingers due to vascular anomaly

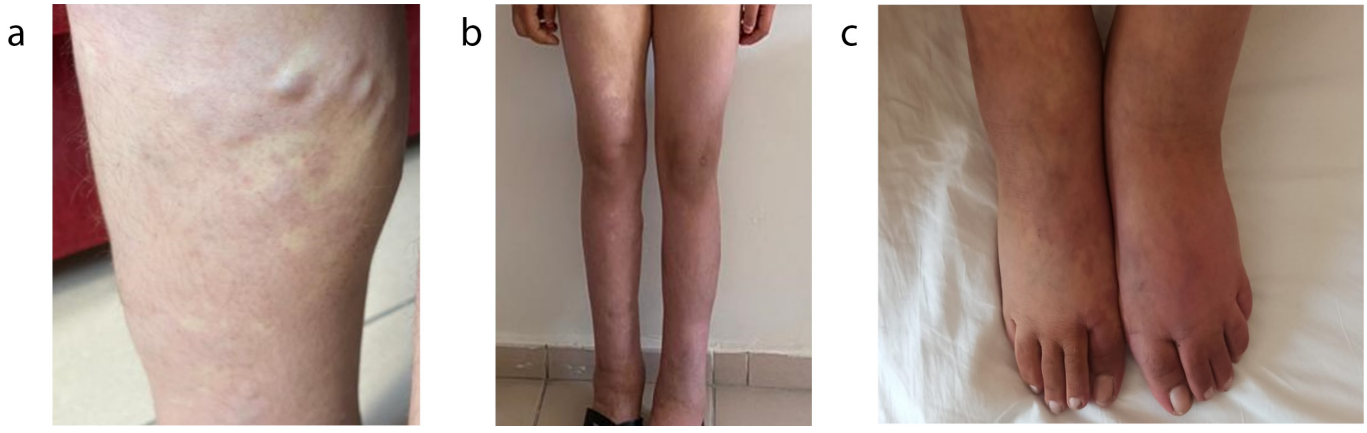

Figure 2. a) Varicose veins. **b)** Port-wine-Stain on legs and feet, wide ankles, and feet. **c)** Syndactyly between the second and third toes of the left foot

158 cm (-0.87 SD). It was reported that her 14-year-old sister has a normal height but is being followed at another center for a cardiac condition.

Laboratory tests, including a complete blood count and biochemistry, were unremarkable. Eye and hearing examinations were normal; her IQ score was 65. Radiographic imaging showed mild thoracic scoliosis and closed epiphyses. Abdominal and renal ultrasonography did not detect any anomaly. Anatomical variation was noted, with the hepatic artery originating directly from the abdominal aorta, while the splenic and left gastric arteries arose from a single branch. Venous Doppler imaging revealed multiple enlarged perforating veins with reflux, connected to the great saphenous vein, with numerous varicose veins in both legs. An echocardiogram detected mild mitral valve prolapse, trace mitral regurgitation, and a small atrial septal defect.

Surgery and pathology reports indicated that the 3x2.5 cm diameter nodule removed from the right lobe hemithyroidectomy material was non-invasive follicular carcinoma, and the 3.5x3 cm mass removed from the right parotid was low-grade mucoepidermoid carcinoma. No metastatic or residual mass was detected in further scans.

Methods and Results

We performed whole exome sequencing (WES) for the patient and her healthy father using the Illumina DNA Prep & TWIST Bioscience Exome 2.0 Plus Comprehensive Exome library preparation and the Illumina NovaSeq 6000 sequencing platform. The bioinformatics analysis pipeline included the Burrows-Wheeler Aligner (BWA 0.7.15) for read alignment, the Genome Analysis Toolkit (GATK 3.6) for variant calling, and the Variant Effect Predictor (VEP 89) for annotation. Variants were

J Clin Res Pediatr Endocrinol
2026;18(Suppl 1):75-82

filtered based on their frequency using public and in-house databases (e.g., gnomAD) (10,11,12,13).

Variant pathogenicity was assessed according to the 2015 American College of Medical Genetics and Genomics (ACMG) guidelines (14) Variants in the *FIBP* gene that met the analysis criteria, correlated with the clinical phenotype, and had variant allele frequency values consistent with the expected inheritance pattern were reported. WES revealed a homozygous c.412-3_415dup p.Asp139AlafsTer3 frameshift variant which was assessed to be likely pathogenic in the *FIBP* gene (NM_004214.5), classified according to ACMG criteria as PVS1-PM2. Family segregation analysis confirmed that the father was a heterozygous carrier of this variant, but maternal carrier status could not be verified due to the lack of available DNA samples. The *FIBP* gene is known to follow a loss-of-function disease mechanism, and the identified variant was absent in population databases, including gnomAD, ExAC, and the Turkish Variome.

Discussion

The protein product of *F1BP* binds acidic FGF intracellularly, leading to morphological changes, differentiation, and stimulation of mitogenic activity in various cell types (4). The FGF receptor (FGFR) family, similar to IGF receptors, functions through tyrosine kinase signaling pathways. Activation of FGFRs initiates downstream signaling cascades, including the MAPK and PI3K/AKT pathways, which play central roles in cellular differentiation, proliferation, survival, and migration. These pathways are also involved in angiogenesis, vascular repair, and wound healing. Aberrations in FGFR genes such as translocations, amplifications or activating variants have been implicated in various malignancies, including gastric, lung, breast, and ovarian cancers (15).

Thauvin-Robinet et al. (16) first described TROFAS in 2016 in a 23-year-old male of North African descent, born to consanguineous parents. The patient exhibited overgrowth, macrocephaly, intellectual disability, facial dysmorphism, bilateral retinal coloboma, ventricular septal defect, mitral valve prolapse, bifid ureter, renal malrotation, transient neutropenia, and varicose venous anomalies. The biallelic variant identified in the *FIBP* gene suggested that loss of function in the intracellular domain of FGFRs may be associated with overgrowth syndromes. Further analysis of the patient's fibroblasts demonstrated significantly reduced *FIBP* cDNA expression but an increased proliferation rate compared to controls, indicating a potential link between *FIBP* dysfunction and overgrowth through the FGFR3 pathway (16,17).

In 2016, a homozygous indel variant (NM_198897.1 c.175_176insTAA, p.His59delinsLeuAsn) was identified in three siblings from an Arab family, each presenting with an overgrowth syndrome accompanied by congenital abnormalities. Functional studies using *in vitro* and *in vivo* models demonstrated that patient-derived fibroblasts exhibited markedly increased proliferation rates, reinforcing the association of *FIBP* loss-of-function variants with overgrowth syndromes (18).

A recent case from Türkiye described a 9-year-old boy with distinct dysmorphic features, including macrosomia at birth, neuromotor delay, and intellectual disability. His facial features included a triangular face, midface retrusion, pointed chin, deep-set eyes, hypertelorism, long and wavy palpebral fissures, a prominent nasal bridge, thick and broad eyebrows with mild synophrys, a short philtrum, a high palate, and posteriorly rotated ears with upturned earlobes. Additional findings included chest narrowing, mild pectus excavatum, hyperextensible elbow joints, pes planus, telangiectasias, hypoplastic nipples, and unilateral cryptorchidism. Genetic analysis via exome sequencing identified a homozygous frameshift variant (NM_004214.5 c.412-3_415dup, p.Asp139AlafsTer3) in the *FIBP* gene, which was classified as likely pathogenic (6). Subsequently, three additional cases with a similar phenotype carrying the same homozygous NM_004214.5 c.412-3_415dup, p Asp139AlafsTer3 variant were reported from Türkiye. All reported cases' clinical and genetic characteristics are summarized in Table 1 (6,7,8,9).

The same frameshift variant was also detected in our patient, introducing a premature stop codon in exon 4 of 10, leading to a truncated or non-functional *FIBP* protein compatible with TROFAS. The loss of *FIBP* function impairs its interaction with growth factors, contributing to dysregulated growth and tumorigenesis, fitting with the observed overgrowth and tumor predisposition in TROFAS. Unlike previously reported cases, our patient did not present with macrosomia, tall stature, macrocephaly, or renal anomalies. However, she shared several overlapping features, including facial dysmorphism, intellectual disability, skeletal abnormalities, and cardiac defects. Moreover, varicose venous enlargement, previously reported in the 23-year-old male described by Thauvin-Robinet et al. (16), was also present in our younger patient, although this feature has not been consistently observed in other cases. Further imaging revealed that our patient also had multiple hemangiomas scattered throughout the body.

Segmental overgrowth syndromes are associated with segmental mosaicism, where a postzygotic variant arising during embryogenesis disrupts tissue growth regulation. Overgrowth can result from either increased cell size (hypertrophy) or increased cell proliferation (hyperplasia), with the severity of symptoms depending on the affected gene and its role in cellular growth and survival (19).

Syndromes associated with somatic *PIK3CA* variants are classified under the PIK3CA-related overgrowth spectrum

Table 1. Cliniacal and genetic characteristics of the nine reported cases of Thauvin-Robinet-Faivre Syndrome (TROFAS)

	Case 1	Case 2	Case 3	Case 4	Case 5
Age	**17 years, male**	**14 years, famale**	**10 years, male**	**3 years, famale**	**4 years, male**
Macrosomia	+	+	+	-	+
Tall stature	+	+	+	+	+
Intellectual Disability/ developmental delay	+	+	+	+	+
Macrocephaly	+	-	-	-	+
Cardiovascular anomalies	VSD MVP Varicose veins	VSD Double chamber right ventricle	-	-	Small PDA Multilple telangiectasias
Genitourinary anomalies	Renal malrotation Left bifid ureter	-	-	Cystic dysplastic kidneys	Mild right renal pelvis dilatation Unilateral cryptorchidism
Hearing loss	-	+	-	-	-
Dysmorphic features	Occipital prominent aspect Long and down-slanting palpebral fissures Large and prominent ears Thick lips Mild macroglossia	Round face Widely spaced eyes Epicanthic folds Depressed nasal bridge Short, small nose Flat mid-face and full lips	Round face Widely spaced eyes Epicanthic folds Depressed nasal bridge Short, small nose Flat mid-face and full lips Strabismus	Round face Widely spaced eyes Epicanthic folds Depressed nasal bridge Short, small nose Flat mid-face and full lips	Triangular face Midface retrusion Pointed chin Deeply set eyes Hypertelorism Long and wave-shaped palpebral fissures Prominent nasal bridge Short philtrum High palate, Posteriorly rotated ears and uplifted earlobes Thick and broad eyebrows with mild synophrys Hypoplastic nipples
Skeletal abnormalities	Hands and feet were large with large thumbs and hallux Bilateral asymmetric limitation of thumb extension Spatulate digits Camptodactyly		Bilateral talipes equino varus, Rotation of both femurs and tibias Spina bifida occulta		Narrow chest Mild pectus excavatum, Hyperextensible elbow joints Pes planus
Other	Bilateral retinal coloboma Transient neutropenia İnguinal hernia Psychosis	Chronic benign neutropenia	Chronic benign neutropenia	Polyhydramnios	Multiple nevus Fibrotic changes in bilateral basal lung segments consistent with chronic pulmonary disease
Tumor/cancer predisposition	-	Wilms tumor	-	-	-
FIBP gene variant	Homozygous NM_004214.5 c.652C>T	Homozygous NM_198897.1 c.175_176insTAA	Homozygous NM_198897.1 c.175_176insTAA	Homozygous NM_198897.1 c.175_176insTAA	Homozygous NM_004214.5 c.415_416insCAGTTTG
Author	Thauvin-Robinet et al. (17) 2016	Akawi et al. (18) 2016	Akawi et al. (18) 2016	Akawi et al. (18) 2016	Duzenli et al. (6) 2023

Table 1. Continued

Case 6	Case 7	Case 8	Present case
16 years, male	**5 years, famale**		**16 years, female**
-	-	+	-
+	+		-
+	+	+	+
+	+		-
Minimal pericardial effusion	–	-	Varicose veins Hemangiomas Hepatic artery originating from the abdominal aorta Mild MVP Small ASD
Right renal atrophy	–	-	-
-	-	-	-
Macrocephaly Round face Widely-spaced deep-set eyes Prominent supraorbital ridges Thick eyebrows Down-slanting palpebral fissures Marked philtrum	Round face Flat midface Widely-spaced eyes Thick eyebrows Marked philtrum.	Hypertelorism Thick and arched eyebrows Pointed chain Down-slanting palpebral fissures Epicanthic folds Broad nasal bridge Small nose High palate	Flat midface Mild right ptosis Low palpebral fissures Deep-set eyes Thick lips Thick and broad eyebrows Mild synophrys Pointed chin Prominent nasal bridge Narrow forehead High palate Posteriorly rotated ears and raised earlobes
Scholiosis Pectus deformity Thoracic asymmetry Large hand Large feet Talipes varus	–	Coxa valga	Mild pectus excavatum and pes planus Enlarged hands and feet
Parieto-occipital perivascular cystic gliotic changes Slightly decreased muscle strength in the lower extremities	Cerebral periventricular patchy hyperintense lesions	-	Port-wine stains on the arms and legs Widespread nevi on face and trunk
-	-	-	Parotis low-grade mucoepidermoid carcinoma Thyroid follicular carcinoma
Homozygous NM_004214.5 c.412-3_415dupCAGTTTG	Homozygous NM_004214.5 c.412-3_415dupCAGTTTG	Homozygous NM_004214 c.412-3_415dupCAGTTTG	Homozygous NM_004214.5 c.412-3_415dup
Kılıç and Koşukcu (7) 2023	Kılıç and Koşukcu (7) 2023	Yüksel Ülker et al. (8) 2024	

ASD: atrial septal defect, VSD: ventricular septal defect, MVP: mitral valve prolapse, PDA: patent ductus arteriosus

(PROS), which encompasses conditions such as fibro adipose overgrowth, hemihyperplasia-multiple lipomatosis, dysplastic megalencephaly, congenital lipomatous overgrowth, vascular malformations, epidermal nevi, skeletal anomalies (CLOVES syndrome), Klippel-Trenaunay syndrome, macrodactyly, and others. These disorders share a common genetic origin but present a broad range of phenotypic expressions, from isolated macrodactyly to more complex cases. The variability in symptom severity is influenced by the timing and cellular context of the variant during development (20,21).

Other genes in the PI3K signaling pathway, including *PTEN* (a negative regulator), are also implicated in segmental overgrowth syndromes. Loss-of-function variants in *PTEN* increase PIP3 levels, activate the AKT/mTOR pathway, and lead to conditions such as germline and mosaic forms of *PTEN* hamartoma tumor syndrome (PHTS). For instance, SOLAMEN syndrome results from a mosaic loss of *PTEN* function and is characterized by localized hypertrophy, vascular malformations, macrodactyly, and an increased cancer risk. Furthermore, activating variants in genes, including *PIK3R2, AKT1, AKT2, AKT3,* and *CCND2* have been identified. Somatic activation of *AKT1* is associated with Proteus syndrome, which is marked by asymmetrical lesions, lipomatous tumors, lymphovascular malformations, and overgrowth of bones and connective tissues, also with a higher cancer risk (22,23).

The presence of a prominent hemangiomatous lesion, along with intellectual disability, excessive soft tissue and bone overgrowth, skeletal abnormalities, and an increased risk of tumors, led us to evaluate the possibility of segmental overgrowth syndromes. TROFAS affects similar genetic pathways and presents with comparable clinical features, and may be included within the *PIK3CA*-PROS. Our patient was thoroughly evaluated for other overgrowth syndromes (21,24). Since *PIK3CA* mosaicism may be present in the affected tissues, it was impossible to completely rule out other diseases in this group for our patient.

Recent research suggests that *FIBP* regulates the expression of the mTOR/STAT3 pathway, a signaling molecule implicated in carcinogenesis, which provides a potential mechanism for the increased cancer risk observed in overgrowth syndromes (25). *FIBP* overexpression has been reported in tumors, such as colon carcinoma and head and neck cancers. Given that FGF1 is linked to several cancers, it is hypothesized that the interaction between *FIBP* and FGF1 plays a role in tumorigenesis (5,26,27,28).

The case described above is particularly notable due to the early onset of multiple malignancies. By the age of 16 years, the patient had developed two distinct cancers: thyroid follicular carcinoma and mucoepidermoid carcinoma of the parotid gland. Among the eight reported cases of TROFAS in the literature, only a single instance of Wilms' tumor has been documented (18). This case suggests a broader diversity of malignancies in TROFAS and an increased spectrum of cancer predisposition associated with *FIBP* gene variants.

Conclusion

The presented case is significant for its distinct phenotypic features and the early development of malignancies, highlighting the role of *FIBP* variants in overgrowth syndrome and cancer predisposition. It should also be remembered that individuals with segmental overgrowth are not always macrosomic at birth, and their height and weight during childhood may remain within normal ranges.

Ethics

Informed Consent: Consent was obtained from the patient and her parents for the scientific use of genetic testing and photographs.

Footnotes

Authorship Contributions: Surgical and Medical Practices: Ülkü Gül Şiraz, Deniz Koçak Göl, Concept: Ülkü Gül Şiraz, Nihal Hatipoğlu, Design: Ülkü Gül Şiraz, Data Collection or Processing: Ülkü Gül Şiraz, Ekrem Ünal, Analysis or Interpretation: Meino Rohlfs, Christoph Klein, Literature Search: Ülkü Gül Şiraz, Ekrem Ünal, Writing: Ülkü Gül Şiraz.

Financial Disclosure: The authors declared that this study received no financial support.

References

1. Neylon OM, Werther GA, Sabin MA. Overgrowth syndromes. Curr Opin Pediatr. 2012;24:505-511.
2. Bertino F, Braithwaite KA, Hawkins CM, Gill AE, Briones MA, Swerdlin R, Milla SS. Congenital limb overgrowth syndromes associated with vascular anomalies. Radiographics. 2019;39:491-515.
3. Manor J, Lalani SR. Overgrowth syndromes-evaluation, diagnosis, and management. Front Pediatr. 2020;8:574857.
4. Kolpakova E, Frengen E, Stokke T, Olsnes S. Organization, chromosomal localization and promoter analysis of the gene encoding human acidic fibroblast growth factor intracellular binding protein. Biochem J. 2000;352 Pt 3:629-635.
5. Xie Y, Su N, Yang J, Tan Q, Huang S, Jin M, Ni Z, Zhang B, Zhang D, Luo F, Chen H, Sun X, Feng JQ, Qi H, Chen L. FGF/FGFR signaling in health and disease. Signal Transduct Target Ther. 2020;5:181.
6. Duzenli T, Sezer A, Kayhan G, Arslan AT, Percin FE. Expanding the phenotype and genotype in Thauvin-Robinet-Faivre syndrome: a new patient with a novel variant and additional clinical findings. Am J Med Genet A. 2023;191:2232-2239. Epub 2023 May 23
7. Kılıç E, Koşukcu C. New cases of recently described Thauvin-Robinet-Faivre syndrome with a novel homozygous FIBP gene variant. Am J Med Genet A. 2024;194:e63449. Epub 2023 Oct 24
8. Yüksel Ülker A, Uludağ Alkaya D, Çağlayan AO, Usluer E, Aykut A, Aslanger A, Vural M, Tüysüz B. An investigation of the etiology and follow-up findings in 35 children with overgrowth syndromes, including biallelic SUZ12 variant. Am J Med Genet A. 2023;191:1530-1545. Epub 2023 Mar 15

9. Duzenli T, Sezer A, Percin FE. Letter to the Editor regarding "New cases of recently described Thauvin-Robinet-Faivre syndrome with a novel homozygous FIBP gene variant" by Kılıç and Koşukçu, "An investigation of the etiology and follow-up findings in 35 children with overgrowth syndromes, including biallelic SUZ12 variant" by Yüksel Ülker et al. and "Expanding the phenotype and genotype in Thauvin-Robinet-Faivre syndrome: A new patient with a novel variant and additional clinical findings" by Duzenli et al. Am J Med Genet A. 2024;194:e63507. Epub 2023 Dec 15

10. Li H, Durbin R. Fast and accurate short read alignment with Burrows-Wheeler transform. Bioinformatics. 2009;25:1754-1760.

11. McKenna A, Hanna M, Banks E, Sivachenko A, Cibulskis K, Kernytsky A, Garimella K, Altshuler D, Gabriel S, Daly M, DePristo MA. The Genome Analysis Toolkit: a MapReduce framework for analyzing next-generation DNA sequencing data. Genome Res. 2010;20:1297-1303. Epub 2010 Jul 19

12. McLaren W, Gil L, Hunt SE, Riat HS, Ritchie GR, Thormann A, Flicek P, Cunningham F. The ensembl variant effect predictor. Genome Biol. 2016;17:122.

13. Karczewski KJ, Francioli LC, Tiao G, Cummings BB, Alföldi J, Wang Q, Collins RL, Laricchia KM, Ganna A, Birnbaum DP, Gauthier LD, Brand H, Solomonson M, Watts NA, Rhodes D, Singer-Berk M, England EM, Seaby EG, Kosmicki JA, Walters RK, Tashman K, Farjoun Y, Banks E, Poterba T, Wang A, Seed C, Whiffin N, Chong JX, Samocha KE, Pierce-Hoffman E, Zappala Z, O'Donnell-Luria AH, Minikel EV, Weisburd B, Lek M, Ware JS, Vittal C, Armean IM, Bergelson L, Cibulskis K, Connolly KM, Covarrubias M, Donnelly S, Ferriera S, Gabriel S, Gentry J, Gupta N, Jeandet T, Kaplan D, Llanwarne C, Munshi R, Novod S, Petrillo N, Roazen D, Ruano-Rubio V, Saltzman A, Schleicher M, Soto J, Tibbetts K, Tolonen C, Wade G, Talkowski ME; Genome Aggregation Database Consortium; Neale BM, Daly MJ, MacArthur DG. The mutational constraint spectrum quantified from variation in 141,456 humans. Nature. 2020;581:434-443. Epub 2020 May 27. Erratum in: Nature. 2021;590:E53. Erratum in: Nature. 2021;597:E3-E4.

14. Richards S, Aziz N, Bale S, Bick D, Das S, Gastier-Foster J, Grody WW, Hegde M, Lyon E, Spector E, Voelkerding K, Rehm HL; ACMG Laboratory Quality Assurance Committee. Standards and guidelines for the interpretation of sequence variants: a joint consensus recommendation of the American College of Medical Genetics and Genomics and the Association for Molecular Pathology. Genet Med. 2015;17:405-424.

15. Touat M, Ileana E, Postel-Vinay S, André F, Soria JC. Targeting FGFR signaling in cancer. Clin Cancer Res. 2015;21:2684-2694.

16. Chen F, Hristova K. The physical basis of FGFR3 response to fgf1 and fgf2. Biochemistry. 2011;50:8576-8582. Epub 2011 Sep 16.

17. Thauvin-Robinet C, Duplomb-Jego L, Limoge F, Picot D, Masurel A, Terriat B, Champilou C, Minot D, St-Onge J, Kuentz P, Duffourd Y, Thevenon J, Rivière JB, Faivre L. Homozygous *FIBP* nonsense variant responsible of syndromic overgrowth, with overgrowth, macrocephaly, retinal coloboma and learning disabilities. Clin Genet. 2016;89:e1-e4. Epub 2016 Jan 20

18. Akawi N, Ben-Salem S, Lahti L, Partanen J, Ali BR, Al-Gazali L. A recessive syndrome of intellectual disability, moderate overgrowth, and renal dysplasia predisposing to Wilms tumor is caused by a mutation in *FIBP* gene. Am J Med Genet A. 2016;170:2111-2118. Epub 2016 May 17

19. Keppler-Noreuil KM, Sapp JC, Lindhurst MJ, Parker VE, Blumhorst C, Darling T, Tosi LL, Huson SM, Whitehouse RW, Jakkula E, Grant I, Balasubramanian M, Chandler KE, Fraser JL, Gucev Z, Crow YJ, Brennan LM, Clark R, Sellars EA, Pena LD, Krishnamurty V, Shuen A, Braverman N, Cunningham ML, Sutton VR, Tasic V, Graham JM Jr, Geer J Jr, Henderson A, Semple RK, Biesecker LG. Clinical delineation and natural history of the PIK3CA-related overgrowth spectrum. Am J Med Genet A. 2014;164A:1713-1733. Epub 2014 Apr 29

20. Venot Q, Canaud G. Les syndromes de surcroissance segmentaire et les stratégies thérapeutiques [Segmental overgrowth syndromes and therapeutic strategies]. Med Sci (Paris). 2020;36:235-242. Epub 2020 Mar 31

21. Mirzaa G, Graham JM Jr, Keppler-Noreuil K. PIK3CARelated Overgrowth Spectrum. In: Adam MP, Mirzaa GM, Pagon RA, Everman DB, et al., editors. GeneReviews® [Internet]. Seattle (WA): University of Washington, Seattle; 1993-2023. [Accessed on: August 25th, 2022]. https://www.ncbi.nlm.nih.gov/books/

22. Yehia L, Keel E, Eng C. The clinical spectrum of *PTEN* mutations. Annu Rev Med. 2020;71:103-116. Epub 2019 Aug 21

23. Kinross KM, Montgomery KG, Mangiafico SP, Hare LM, Kleinschmidt M, Bywater MJ, Poulton IJ, Vrahnas C, Henneicke H, Malaterre J, Waring PM, Cullinane C, Sims NA, McArthur GA, Andrikopoulos S, Phillips WA. Ubiquitous expression of the Pik3caH1047R mutation promotes hypoglycemia, hypoinsulinemia, and organomegaly. FASEB J. 2015;29:1426-1434.

24. Hughes M, Hao M, Luu M. PIK3CA vascular overgrowth syndromes: an update. Curr Opin Pediatr. 2020;32:539-546.

25. Xu Y, Li J, Zhu K, Zeng Y, Chen J, Dong X, Zhang S, Xu S, Wu G. FIBP interacts with transcription factor STAT3 to induce EME1 expression and drive radioresistance in lung adenocarcinoma. Int J Biol Sci. 2023;19:3816-3829.

26. Tassi E, Henke RT, Bowden ET, Swift MR, Kodack DP, Kuo AH, Maitra A, Wellstein A. Expression of a fibroblast growth factor-binding protein during the development of adenocarcinoma of the pancreas and colon. Cancer Res. 2006;66:1191-1198.

27. Li W, Wang C, Juhn SK, Ondrey FG, Lin J. Expression of fibroblast growth factor binding protein in head and neck cancer. Arch Otolaryngol Head Neck Surg. 2009;135:896-901.

28. Colvin JS, Bohne BA, Harding GW, McEwen DG, Ornitz DM. Skeletal overgrowth and deafness in mice lacking fibroblast growth factor receptor 3. Nat Genet. 1996;12:390-397.

CASE REPORT

JCRPE Journal of Clinical Research in Pediatric Endocrinology

DOI: 10.4274/jcrpe.galenos.2025.2024-12-4
J Clin Res Pediatr Endocrinol 2026;18(Suppl 1):83-91

Xp21 Contiguous Gene Deletion Syndrome: Diagnosis, Treatment, and a Review of the Literature on a Rare Genetic Disorder

Berna Singin[1], Zeynep Donbaloğlu[1], Ebru Barsal Çetiner[1], Aynur Bedel[1], Kürşat Çetin[1], Belgin Akcan Paksoy[2], Tarkan Kalkan[3], Halide Akbaş[4], Hale Ünver Tuhan[1], Mesut Parlak[1]

[1]Akdeniz University Faculty of Medicine, Department of Pediatric Endocrinology, Antalya, Türkiye
[2]Akdeniz University Faculty of Medicine, Department of Pediatric Metabolic Diseases, Antalya, Türkiye
[3]University of Health Sciences Türkiye, Antalya Training and Research Hospital, Clinic of Molecular Genetics, Antalya, Türkiye
[4]Akdeniz University Faculty of Medicine, Department of Medical Biochemistry, Antalya, Türkiye

Cite this article as: Singin B, Donbaloğlu Z, Barsal Çetiner E, Bedel E, Çetin K, Akcan Paksoy B, Kalkan T, Akbaş H, Ünver Tuhan H, Parlak M. Xp21 contiguous gene deletion syndrome: diagnosis, treatment, and a review of the literature on a rare genetic disorder. J Clin Res Pediatr Endocrinol. 2026;18(Suppl 1):83-91

What is already known on this topic?

Complex glycerol kinase deficiency (CGKD) usually arises from a partial deletion of the Xp21 chromosomal region, affecting genes associated with GKD, adrenal hypoplasia, Duchenne muscular dystrophy, and other conditions that lead to various developmental abnormalities. Symptoms are related to the size of the deletion and may manifest in early life.

What this study adds?

CGKD is an uncommon condition and this report describes our experiences with a patient diagnosed with CGKD. This case highlights the rare yet significant clinical and genetic diversity linked to Xp21 contiguous gene deletion syndrome and it is hoped that this case report will enhance the recognition and clinical management of these patients.

ABSTRACT

Xp21 contiguous gene deletion syndrome is an uncommon genetic condition associated with complex glycerol kinase deficiency (*GK*), congenital adrenal hypoplasia (*NR0B1*), Duchenne muscular dystrophy (*DMD*), and, in some cases, intellectual disability. Clinical findings vary based on the

Corresponding Author: Prof. Mesut Parlak, Akdeniz University Faculty of Medicine, Department of Pediatric Endocrinology, Antalya, Türkiye
E-mail: mesutparlak@akdeniz.edu.tr **ORCID:** orcid.org/0000-0002-3550-1425
Conflict of interest: None declared
Received: 20.12.2024 **Accepted:** 17.03.2025 **Epub:** 19.03.2025 **Publication Date:** 02.06.2026

©Copyright 2026 by Turkish Society for Pediatric Endocrinology and Diabetes / The Journal of Clinical Research in Pediatric Endocrinology published by Galenos Publishing House.
Licensed under a Creative Commons Attribution-NonCommercial-NoDerivatives 4.0 (CC BY-NC-ND) International License.

J Clin Res Pediatr Endocrinol
2026;18(Suppl 1):83-91

size of the deletion and the number of affected genes. To date, over 100 male patients with this syndrome have been reported, while the number of symptomatic female carriers is quite limited. In this article, we present the diagnosis and treatment process of a case exhibiting dysmorphic facial features, signs of adrenal insufficiency, pseudo-hypertriglyceridemia, and elevated creatine phosphokinase levels. The patient's serum 17-hydroxyprogesterone levels were normal, and the adrenal glands were not observable via magnetic resonance imaging. An Xp21.2 deletion (*DMD, NR0B1, GK, IL1RAPL1*) was identified in the case. Treatment with hydrocortisone, fludrocortisone, and oral salt was arranged. This case highlights the rare yet significant clinical and genetic diversity of Xp21 contiguous gene deletion syndrome.

Keywords: Complex glycerol kinase deficiency, congenital adrenal hypoplasia, Duchenne muscular dystrophy, glycerol kinase deficiency, pseudo-hypertriglyceridemia

Introduction

Xp21 contiguous gene deletion syndrome is a rare genetic metabolic disorder that arises from the deletion of a chromosomal segment encompassing the glycerol kinase (GK) locus in the Xp21 region (1). The genetic loci for adrenal hypoplasia (AHC), Duchenne muscular dystrophy (DMD), chronic granulomatous disease (CGD), ornithine transcarbamylase (OTC) deficiency, and retinitis pigmentosa (RP) are frequently involved. The loci for AHC and DMD are located near the glycerol kinase deficiency (GKD) locus, which makes the combination of AHC, GKD, and DMD the most common genotype in this condition, referred to as complex glycerol kinase deficiency (CGKD) (2).

The symptoms depend on the extent of the deletion and may appear early in life. Diagnosis relies on clinical observations and laboratory results. Genetic testing can confirm the diagnosis by detecting a deletion at the Xp21 locus, and carrier status can be identified in female relatives (1,3).

This article presents a male infant with a complex phenotype of Xp21 contiguous gene deletion syndrome, featuring pseudo-hypertriglyceridemia, adrenal insufficiency (hyponatremia, hyperkalemia, dehydration), and increased creatine phosphokinase (CPK) levels, suggestive of DMD. Biochemical, cytogenetic, and molecular tests were performed to identify and assess the extent of the genomic deletion. Early diagnosis of CGKD gives the patient the possibility of optimal multi-profile medical care, which has a positive effect on the optimal individual development and the quality of life. This article highlights the diversity of the clinical course of the disease. We hope it will prove to be of help to other endocrinologists, to the benefit of our patients.

Case Report

An 8-month-and-13-day-old male was referred to our hospital due to respiratory distress, dehydration, and hypoglycemia. The patient had been diagnosed with adrenal insufficiency during the neonatal period and had been started on hydrocortisone, fludrocortisone, oral salt, and anti-potassium treatments. The patient had been receiving hydrocortisone treatment at approximately 8 mg/m²/day after the neonatal period, but the dose of hydrocortisone was likely not increased after an infection. Due to his poor general condition, he was admitted to the pediatric intensive care unit for monitoring.

The patient was born at 39 weeks, weighing 2900 grams and measuring 48 cm, via NSD from a 22-year-old mother. There was a first-degree consanguinity (sibling) between the parents, and the mother had a history of mental retardation. On physical examination, the patient's weight was 5 kg (<3rd percentile), height was 64 cm (<3rd percentile), and head circumference was 39 cm (<3rd percentile). He appeared in poor general condition, hypotonic, microcephalic, and dehydrated, with dysmorphic facial features including upward-deviated eyes and low-set ears. The skin showed hyperpigmentation, particularly evident in the scrotum. On examination of the genitourinary system, the stretched penis measured 4 cm, and the testicles were not palpable bilaterally. Other system examinations were normal.

On routine laboratory tests, the following results were obtained: glucose: 191 mg/dL (74-106) (prior to dextrose treatment at an external center, it was 39 mg/dL), sodium: 129.1 mEq/L (136-145), potassium: 6.4 mEq/L (3.5-5.1), aspartate aminotransferase: 1081 U/L (0-34), alanine aminotransferase: 293 U/L (10-49). Additional testing showed blood urea nitrogen: 31 mg/dL (9-23), creatinine: 0.43 mg/dL (0.7-1.3), uric acid: 6.9 mg/dL (3.7-9.2), hemoglobin: 11.7 g/dL, leukocytes: 14.7 10^3/mm³, platelets: 131 10^3/mm³, C-reactive protein: 61.3 mg/L (0-5), lactate dehydrogenase: 2736 U/L (120-246), and myoglobin: 2416 (0-110) ng/mL. Based on these findings, adrenal cortical insufficiency was suspected. The treatment doses were adjusted with fluid and electrolyte therapy in appropriate doses, with hydrocortisone at 30 mg/m²/day and fludrocortisone at 0.1 mg/day. The adrenocorticotropic hormone (ACTH) level was 9.07 pg/mL (0-46), serum cortisol was 40.2 µg/dL (4.3-22.4), 17-hydroxyprogesterone (17-OHP) was 0.35 ng/mL (0.59-3.44), renin was <0.14 ng/mL/hour (0.06-4.69), and aldosterone was >20 ng/dL (0-19.9) (Table 1). However, these tests were performed after the patient started hydrocortisone and fludrocortisone treatments. During the diagnosis in the neonatal period, ACTH was found to be 612 pg/mL (0-46) and cortisol 0.8 µg/dL (4.3-22.4). Also during this period, renin was >500 pg/mL (2.13-58.78) and aldosterone was 32.08 ng/L (25-315). It was considered that the low renin value in the patient's

Table 1. Patient's laboratory results

Hormone	Result	Normal range
Serum cortisol (µg/dL)	40.2	4.3-22.4
ACTH (pg/mL)	9.07	0-46
17-OHP (ng/mL)	0.35	0.59-3.44
DHEAS (ug/dL)	<15	80-560
AS (ng/mL)	0.21	0.03-0.15
11-Deoxycortisol (ng/mL)	3.56	0.43-7.56
Aldosterone (ng/dL)	>20	0-19.9
Renin (ng/mL/hour)	<0.14	0.06-4.69

ACTH: adrenocorticotropic hormone, 17-OHP: 17-hydroxyprogesterone, DHEAS: dehydroepiandrosterone sulfate, AS: androstenedione

tests taken in the pediatric intensive care unit was due to the fludrocortisone treatment, and the high aldosterone value was thought to be due to analytical interference caused by the medication.

In the metabolic tests of the patient, serum CPK was found to be 40,800 U/L (normal range: 46-171), and the lipid panel showed elevated triglycerides at 637 mg/dL (normal range: 0-150). Urinary organic acid analysis using gas chromatography-mass spectrometry (GC-MS) revealed a high urinary glycerol excretion of 1465.14 mmol/mmol creatinine (normal range: 0.01-0.1) (Figure 1 and 2). The positive urinary glycerol level and triglyceridemia suggested GKD.

Abdominal ultrasound failed to visualize the adrenal glands. Scrotal ultrasound showed the right testis in the proximal inguinal canal (undescended testis) measuring 16x8x6 mm (0.4 mL), while the left testis was not visualized. Bilateral adrenal glands could not be seen on upper abdominal magnetic resonance imaging (MRI). The clinical and laboratory observations were obtained following an AHC diagnosis. The brain MRI showed widespread diffusion restrictions in both cerebral and cerebellar hemispheres, as well as in the basal ganglia.

Peripheral blood chromosome analysis reported a karyotype of 46,XY. An array CGH test was performed to investigate submicroscopic deletions. The microarray analysis result was arr[GRCh37] Xp21.3p21.1(28514128_37189187)x0. A hemizygous deletion of approximately 8.6 Mb was detected in the patient (Figure 3). The deletion encompassed the *IL1RAPL1*, *NR0B1* (*DAX1*), *GK*, and also the *DMD* genes. Thus he was diagnosed with Xp21 contiguous gene deletion syndrome, characterized by GKD, AHC, and possible DMD.

During the follow-up, the patient did not experience any vomiting, could tolerate feeding, and gained weight. Laboratory tests indicated that electrolyte values remained within normal ranges. On the 32nd day of hospitalization, he was discharged on oral hydrocortisone and fludrocortisone treatments. He was placed under multidisciplinary follow-up involving the relevant specialties.

Discussion

In this article, we present our experience in the diagnosis and treatment of a patient who was referred at 8 months and 13 days of age with complaints of respiratory distress, dehydration, and hypoglycemia. Cytogenetic and molecular studies confirmed a deletion involving the *GK*, *NR0B1*, and *DMD* genes. The patient is currently under multidisciplinary follow-up, and appropriate care is provided in a supervised institutional setting with regular medical oversight.

CGKD is an X-linked inherited contiguous gene deletion syndrome. It usually results from a partial deletion at the Xp21 chromosomal locus, encompassing genes linked to GKD, AHC, DMD, and several developmental disorders. The symptoms are

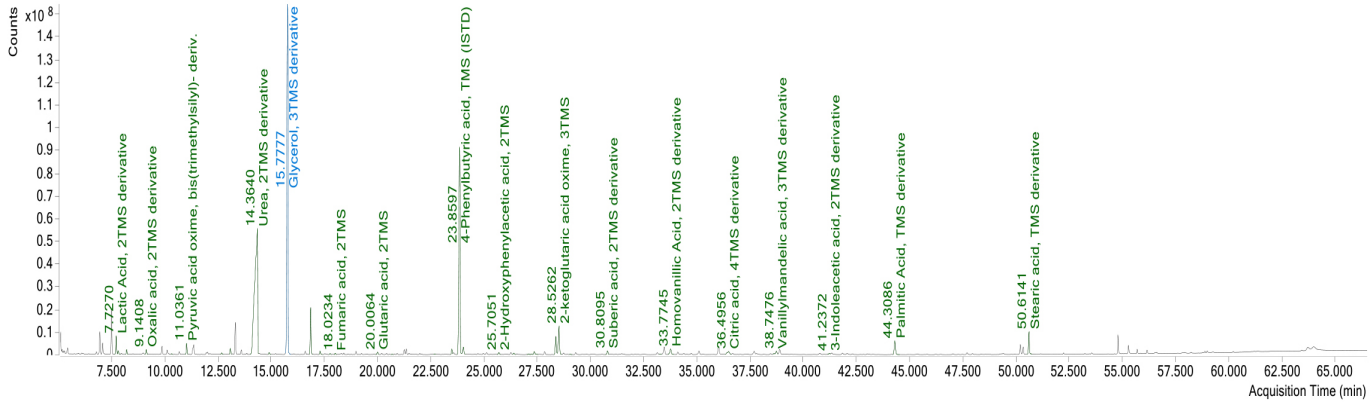

Figure 1. Urinary organic acid analysis results

associated with the extent of the deletion and can manifest in early life, as in the presented case (4). Due to its rarity and limited recognition among healthcare providers, CGKD is frequently challenging to diagnose in its early stages. Most affected individuals are male, and to date, there have been fewer than ten reported cases of female patients (5,6).

In the presented case, adrenal insufficiency was considered due to salt loss during the neonatal period, and treatment with hydrocortisone, fludrocortisone, oral salt, and anti-potassium medications was initiated. The clinical and laboratory findings of dehydration, hyponatremia, hyperkalemia, and hyperpigmentation were consistent with the diagnosis of adrenal insufficiency. It was suggested that the normal serum ACTH level might be due to early steroid replacement therapy. Congenital adrenal hyperplasia (CAH) is the most common cause of primary adrenal insufficiency; however, a 17-OHP level below 10 ng/mL during the neonatal period effectively excludes this diagnosis (7). In addition, CAH is typically associated with enlarged adrenal glands on imaging (8). In the presented case, the adrenal glands were not visualized even on MRI, supporting the diagnosis of AHC. The findings in our patient are consistent with AHC, which may be linked to mutations or deletions in the *DAX-1* (*NR0B1*) gene on the X chromosome (9,10), abnormalities in the steroidogenic factor 1 gene on chromosome 9q33 (11), and disorders like IMAGe syndrome (12). In X-linked AHC, deletions of the *DAX-1* gene can occur along with deletions of adjacent genes in the Xp21 locus.

In our case, the lipid metabolism findings prompted us to consider CGKD. The deletion of the GK locus causes GKD, which is linked to hypertriglyceridemia. Elevated triglyceride levels in lipid metabolism tests should raise concern for CGKD in an infant with growth delay. A fast and straightforward method for diagnosing CGKD is by measuring urinary glycerol levels using GC-MS analysis (13). Following this, genetic screening can verify the deletion of the CGKD loci.

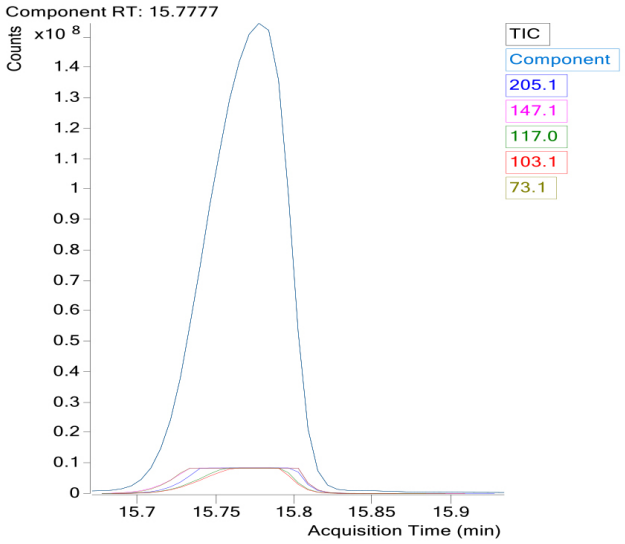

Figure 2. Glycerol peak in urinary organic acid analysis

Figure 3. 656K Microarray Analysis DECIPHER image of the region between p21.3 and p21.1 on the Grch37 X Chromosome (28514128-37189187). The layout of morbid genes *IL1RAPL1*, DMD, GK, *NR0B1, CFAP47* in the deleted area and the locations of all other genes in this region are shown

Glycerol kinase (IUB: 2.7.1.30) is the enzyme responsible for phosphorylation of glycerol from triglyceride breakdown for further metabolism. The absence of this enzyme activity leads to the accumulation of glycerol in circulation, causing glycerolaemia and glyceroluria (14,15). The glycerolaemia is usually detected as pseudo-hypertriglyceridemia due to overestimation of serum triglyceride levels as a result of analytical interference by free glycerol on the assay method (16).

Hypoglycemia is a feature in both congenital adrenal hypoplasia and GKD. In congenital adrenal hypoplasia, hypoglycemia is due to the deficiency of the counterregulatory hormone cortisol. In GKD, the conversion of glycerol to glycerol-3-phosphate is impaired, limiting substrate for gluconeogenesis. Thus, in Xp21 contiguous gene deletion, hypoglycemia results from a combination of congenital adrenal hypoplasia and GKD.

DMD symptoms in infants are frequently challenging to identify; nevertheless, caregivers should consult a doctor if their child cannot sit up by six months or older. In the presented case, psychometric analysis revealed that the patient was behind peers at all developmental stages. In clinical practice, the possibility of DMD can be considered based on laboratory results. Serum CPK levels are typically significantly elevated, usually 10 to 20 times higher than the normal reference range (17). In the presented case, the serum CPK concentration was noted to be significantly elevated. In addition, mental retardation may accompany DMD in male patients (18).

Table 2 lists 21 cases diagnosed with Contiguous Gene Deletion Syndrome and published since the 2000s. Genetic diagnosis was available for all cases except one (20). In two cases, other than *DMD*, the other genes were not investigated (3). Adrenal insufficiency was present in 14 cases (2,3,4,19,20,24,26,28,29,30). In 12 of these cases, a deletion in the *NR0B1* gene was present, while in the other two cases, the *NR0B1* gene was not investigated (3,23). Dysmorphic features have been inconsistently reported in the literature, and most reports do not describe these features in detail, making it difficult to define a consistent phenotypic pattern.

Table 2. Clinical and laboratory features of reported cases with contiguous gene deletion syndrome involving *DMD, GK, NR0B1*, and *IL1RAPL1* genes

Reference	Gender	Age of diagnosis	Genetic variants	Symptoms	Na meq/L	K meq/L	Serum cortisol	ACTH	CPK U/L	Urinary glycerol excretion
Our case	M	8 months	*DMD, NR0B1, GK, IL1RAPL1*	Respiratory distress, dehydration, hypoglycemia, dark skin	129	6.4	40.2 µg/dL (4.3-22.4) (At)	9.07 pg/mL (0-46) (At)	40.800	1465.14 mmol/mmol creatinine
Islas Abdenur (20) 2024	M	14 days	Not investigated	Dehydration, hyponatremia, hyperkalemia	126	5.9	5.9 ug/dL	480 pg/mL	6.530	Massive glyceroluria (Value not specified)
Pizza et al. (21) 2023	M	7 months	*DMD, GK*	Development delay, hypotonia, unable to walk, to go upstairs, to sit, intellectual disability	-	-	-	-	14.576	1082 mM/Mcreat
Bi et al. (22) 2023	M	19 days	*DMD, GK, CFAP47, CYBB, XK, RPGR*	Macrosomia, neonatal sepsis, liver and lung abscesses	-	-	-	-	1.115	-
Tao (19) et al. 2022	M	48 days	*DMD, GK, NR0B1*	Growth retardation, vomiting, dark skin, failure to thrive	132	5.9	647.9 nmol/L (66-630)	15.04 pg/mL (7.2-63.6)	1.586	3129.2 umol/mmol
Rathnasiri et al. (23) 2021	M	36 months	*DMD* (exons 45-79), *GK*	Failure to thrive, difficulty in feeding, developmental delay, difficulty in walking and getting up from the seated position, Gower's sign, calf hypertrophy	120	7.1	4 nmol/L (120-626)	343 pg/mL (7-41)	12.395	Massive glyceroluria (Value not specified)

Table 2. Clinical and laboratory features of reported cases with contiguous gene deletion syndrome involving *DMD, GK, NR0B1*, and *IL1RAPL1* genes

Reference	Gender	Age of diagnosis	Genetic variants	Symptoms	Na meq/L	K meq/L	Serum cortisol	ACTH	CPK U/L	Urinary glycerol excretion
Wikiera et al. (24) 2021 *Patient 1*	M	5 weeks	*NR0B1, GK, DMD*	Failure to thrive, loss of body weight, athrepsia, dehydration, weak muscle tone, psychomotor development delay	116.6	6.1	46.92 nmol/l	162 ng/L (<45)	13.126	Massive glyceroluria (Value not specified)
Wikiera et al. (24) 2021 *Patient 2*	M	5 weeks	*NR0B1, GK, IL1RAPL1, DMD* (*C*-terminal region)	Dehydration, adynamia, failure to thrive, psychomotor development delay	123	6.1	-	-	4.236	-
Liu et al. (25) 2021	M	Data not available	*IL1RAPL1, MAGEB1-4, ROB, CXorf2, M, AP3K71P, FTHL1, DMD, FAM47A, TMEM47, FAM47B*	Data not available						
Korkut et al. (4) 2016 *Patient 1*	M	36 days	*DMD* (part), *GK, NR0B1, IL1RAPL1* (part)	Difficulty to feed, vomiting, weight loss, dark skin, hypotonia, dehydration, dysmorphic facial features	128	8.6	12.6 µg/dL	>2000 pg/mL	5.758	4847.6 mmol/mmol creatine
Korkut et al. (4) 2016 *Patient 2*	M	18 days	DMD, GK, NR0B1	Reduced breastfeeding, vomiting, weight loss, dehydration, dysmorphic facial features	124	7.4	20.6 µg/dL	628 pg/mL	28.134	-
Heide et al. (5) 2015 *Patient 1*	F	-	*IL1RAPL1, NR0B1, GK, DMD* (last 37 exons)	Delayed expressive language, hyperopia, multiple serous otitis, intellectual disability	-	-	-	-	Normal (Value not specified)	-
Heide et al. (5) 2015 *Patient 2*	F	-	*IL1RAPL1, NR0B1, GK, DMD* (last 22 exons)	Delayed expressive language, muscular pains, muscular fatigue, global muscular hypertrophy, epilepsy	-	-	-	-	579	-
Sevim et al. (26) 2011	M	1 month	*DMD* (exons 62-79), *GK, NR0B1, IL1RAPL1*	Hypotonia, inadequate breastfeeding, failure to thrive, decreased skin turgor, scrotal hyperpigmentation	124	6.9	184.9 nmol/L (185-624)	4.58 pmol/L (0-50)	7.019	Massive glyceroluria (Value not specified)

Table 2. Clinical and laboratory features of reported cases with contiguous gene deletion syndrome involving *DMD, GK, NR0B1*, and *IL1RAPL1* genes

Reference	Gender	Age of diagnosis	Genetic variants	Symptoms	Na meq/L	K meq/L	Serum cortisol	ACTH	CPK U/L	Urinary glycerol excretion
Ramanjam et al. (3) 2010 *Patient 1*	M	19 days	*DMD*; other genes were not investigated	Dehydration, poor feeding, vomiting, developmental delay, hypotonia global weakness, calf hypertrophy; reflexes absent, intellectual disability	117	8.5	478 nmol/L (28-662)	-	2.507	590 mmol/L
Ramanjam et al. (3) 2010 *Patient 2*	M	Prenatal	*DMD*; other genes were not investigated	Hypotonia, waddling gait, difficulty in climbing stairs, intellectual disability	-	-	-	-	5.307	220 mmol/L
Jamroz et al. (27) 2010	M	4 months	*DMD, GK*	Failure to thrive, dehydration global developmental delay, axial hypotonia, distal hypertonia, intellectual disability	-	-	-	-	10.818	Massive glyceroluria (Value not specified)
Sanz-Ruiz et al. (28) 2009	M	7 months	*DMD, GK, NR0B1, IL1RAPL1*	Global developmental delay, pronounced axial hypotonia, intellectual disability	-	-	9.8 µg/dL (4-19.4)	>1.250 pg/mL (0-46)	12.829	12.332 µM/mol creatinin
Pantoja-Martínez et al. (29) 2007	M	8 days	*DMD, GK, NR0B1*	Salt loss with lethargy, vomiting, hypoglycemia, metabolic acidosis, progressive muscle weakness, intellectual disability	121	7.5	1 µg/dL (12-960)	807 pg/mL (16-106)	9.700	6.173 µmol/mol creatinin
Sehgal and Stack (2) 2005	M	Newborn	*GK, NR0B1*	Hypoglycemia, salt loss	126	5.9	69 mmol/L (85-440)	32 pmol/L (<10)	Normal (Value not specified)	Massive glyceroluria (Value not specified)
Ma et al. (30) 2004	M	42 months	*DMD* (exons 62-66), *GK, NR0B1*	Nausea, vomiting, global development delay, unable to walk, go upstairs, run fast, Gower's Sign, calf hypertrophy, intellectual disability	126	6.6.	3.5 ng/dL (5-25)	-	5.798	-

DMD: Duchenne muscular dystrophy, *GK*: glycerol kinase, *NR0B1*: nuclear receptor superfamily 0, group B, member 1, *IL1RAPL1*: interleukin 1 receptor accessory protein-like 1, M: male, F: female, At: after treatment

More than 100 male patients have been reported so far, while only a few cases of symptomatic female carriers have been described. In two of the reported cases, detailed clinical features and X chromosome inactivation analysis are presented in two unrelated female patients with overlapping Xp21 deletions, who presented with intellectual disability and episodic muscular symptoms (5).

As in our case, elevated CPK levels were detected in cases with *DMD* gene deletions. Only in one of the two female cases, CPK levels were found to be normal (5).

In 11 of the 17 cases with a deletion in the *GK* gene, glyceroluria was reported, as in our case (2,16,19,21,23,24,26,27,28,29). In six cases, no results were provided. In one case, despite massive glyceroluria, genetic testing was not performed (20).

Generally, corticosteroid therapy and salt intake are accepted treatments for CGKD (2,4). Diagnosing CGKD can be difficult, but a detailed standard assessment can help identify pseudo-hypertriglyceridemia and elevated CPK levels, which can then lead to additional genetic testing. The dosage of corticosteroid substitution treatment should be dynamically adjusted to avoid negatively impacting the hypothalamic-pituitary-adrenal axis and to minimize unwanted effects on the child's immune system (19). Furthermore, this treatment should be carefully managed and dynamically adjusted to minimize the risk of adrenal crisis.

Conclusion

This case presentation highlights the medical and genetic diversity of the very rare Xp21 contiguous gene deletion syndrome. The dysmorphic features described in our patient, including upward-deviated eyes and low-set ears, in combination with adrenal insufficiency and features of GKD, supported the diagnosis and emphasized the importance of a multidisciplinary approach. The response to treatment was positive, leading to stabilization. This case highlights the importance of clinical practice in diagnosing and managing rare genetic syndromes. AHC and CGKD should be included in the differential diagnosis of male newborns exhibiting similar clinical symptoms and adrenal imaging may provide key diagnostic data. Performing genetic analyses aids in confirming the diagnosis by pinpointing the position and size of deletions, predicting prognosis, and identifying female carriers.

Ethics

Informed Consent: Written informed consent of the parents was obtained for this case report.

Footnotes

Authorship Contributions

Surgical and Medical Practices: Berna Singin, Zeynep Donbaloğlu, Ebru Barsal Çetiner, Aynur Bedel, Kürşat Çetin, Belgin Akcan Paksoy, Hale Ünver Tuhan, Mesut Parlak, Concept: Berna Singin, Hale Ünver Tuhan, Mesut Parlak, Design: Berna Singin, Zeynep Donbaloğlu, Mesut Parlak, Data Collection or Processing: Berna Singin, Zeynep Donbaloğlu, Ebru Barsal Çetiner, Aynur Bedel, Kürşat Çetin, Mesut Parlak, Analysis or Interpretation: Berna Singin, Tarkan Kalkan, Halide Akbaş, Mesut Parlak, Literature Search: Berna Singin, Hale Ünver Tuhan, Mesut Parlak, Writing: Berna Singin, Mesut Parlak.

Financial Disclosure: The authors declared that this study received no financial support.

References

1. Dipple KM, Zhang YH, Huang BL, McCabe LL, Dallongeville J, Inokuchi T, Kimura M, Marx HJ, Roederer GO, Shih V, Yamaguchi S, Yoshida I, McCabe ER. Glycerol kinase deficiency: evidence for complexity in a single gene disorder. Hum Genet. 2001;109:55-62.
2. Sehgal A, Stack J. Complex glycerol kinase deficiency: an X-linked disorder associated with adrenal hypoplasia congenita. Indian J Pediatr. 2005;72:67-69.
3. Ramanjam V, Delport S, Wilmshurst JM. The diagnostic difficulties of complex glycerol kinase deficiency. J Child Neurol. 2010;25:1269-1271. Epub 2010 Jan 28
4. Korkut S, Baştuğ O, Raygada M, Hatipoğlu N, Kurtoğlu S, Kendirci M, Lyssikatos C, Stratakis CA. Complex glycerol kinase deficiency and adrenocortical insufficiency in two neonates. J Clin Res Pediatr Endocrinol. 2016;8:468-471. Epub 2016 Apr 18
5. Heide S, Afenjar A, Edery P, Sanlaville D, Keren B, Rouen A, Lavillaureix A, Hyon C, Doummar D, Siffroi JP, Chantot-Bastaraud S. Xp21 deletion in female patients with intellectual disability: two new cases and a review of the literature. Eur J Med Genet. 2015;58:341-345. Epub 2015 Apr 23
6. Shaikh MG, Boyes L, Kingston H, Collins R, Besley GT, Padmakumar B, Ismayl O, Hughes I, Hall CM, Hellerud C, Achermann JC, Clayton PE. Skewed X inactivation is associated with phenotype in a female with adrenal hypoplasia congenita. J Med Genet. 2008;45:e1.
7. Working Group on Neonatal Screening of the European Society for Paediatric Endocrinology. Procedure for neonatal screening for congenital adrenal hyperplasia due to 21-hydroxylase deficiency. Horm Res. 2001;55:201-205.
8. Al-Alwan I, Navarro O, Daneman D, Daneman A. Clinical utility of adrenal ultrasonography in the diagnosis of congenital adrenal hyperplasia. J Pediatr. 1999;135:71-75.
9. Habiby RL, Boepple P, Nachtigall L, Sluss PM, Crowley WF Jr, Jameson JL. Adrenal hypoplasia congenita with hypogonadotropic hypogonadism: evidence that DAX-1 mutations lead to combined hypothalmic and pituitary defects in gonadotropin production. J Clin Invest. 1996;98:1055-1062.
10. McCabe ER. DAX1: Increasing complexity in the roles of this novel nuclear receptor. Mol Cell Endocrinol. 2007;265-266:179-182. Epub 2007 Jan 8
11. Achermann JC, Ito M, Ito M, Hindmarsh PC, Jameson JL. A mutation in the gene encoding steroidogenic factor-1 causes XY sex reversal and adrenal failure in humans. Nat Genet. 1999;22:125-126.
12. Bergadá I, Del Rey G, Lapunzina P, Bergadá C, Fellous M, Copelli S. Familial occurrence of the IMAGe association: additional clinical variants and a proposed mode of inheritance. J Clin Endocrinol Metab. 2005;90:3186-3190. Epub 2005 Mar 15
13. Hellerud C, Wramner N, Erikson A, Johansson A, Samuelson G, Lindstedt S. Glycerol kinase deficiency: follow-up during 20 years, genetics, biochemistry and prognosis. Acta Paediatr. 2004;93:911-921.
14. Francke U, Harper JF, Darras BT, Cowan JM, McCabe ER, Kohlschütter A, Seltzer WK, Saito F, Goto J, Harpey JP, et al. Congenital adrenal hypoplasia, myopathy, and glycerol kinase deficiency: molecular genetic evidence for deletions. Am J Hum Genet. 1987;40:212-227.
15. Sjarif DR, Hellerud C, van Amstel JK, Kleijer WJ, Sperl W, Lacombe D, Sass JO, Beemer FA, Duran M, Poll-The BT. Glycerol kinase deficiency: residual activity explained by reduced transcription and enzyme conformation. Eur J Hum Genet. 2004;12:424-432.
16. Rughani A, Blick K, Pang H, Marin M, Meyer J, Tryggestad JB. Pseudohypertriglyceridemia: a novel case with ımportant clinical ımplications. Case Rep Pediatr. 2020;2020:4609317.
17. Yiu EM, Kornberg AJ. Duchenne muscular dystrophy. J Paediatr Child Health. 2015;51:759-764. Epub 2015 Mar 9
18. Nardes F, Araújo AP, Ribeiro MG. Mental retardation in Duchenne muscular dystrophy. J Pediatr (Rio J). 2012;88:6-16.

19. Tao N, Liu X, Chen Y, Sun M, Xu F, Su Y. Delayed diagnosis of complex glycerol kinase deficiency in a Chinese male infant: a case report. BMC Pediatr. 2022;22:517.

20. Islas Abdenur M. Complex glycerol kinase deficiency: a case report. Arch Argent Pediatr. 2025;123:e202410354. Epub 2024 Nov 7

21. Pizza A, Picillo E, Onore ME, Scutifero M, Passamano L, Nigro V, Politano L. Xp21 contiguous gene deletion syndrome presenting as Duchenne muscular dystrophy and glycerol kinase deficiency associated with intellectual disability: case report and review literature. Acta Myol. 2023;42:24-30.

22. Bi S, Dai L, Jiang L, Wang L, Teng M, Liu G, Teng RJ. Chronic granulomatous disease associated with Duchenne muscular dystrophy caused by Xp21.1 contiguous gene deletion syndrome: case report and literature review. Front Genet. 2023;13:970204.

23. Rathnasiri A, Senarathne U, Arunath V, Hoole T, Kumarasiri I, Muthukumarana O, Jasinge E, Mettananda S. A rare co-occurrence of duchenne muscular dystrophy, congenital adrenal hypoplasia and glycerol kinase deficiency due to Xp21 contiguous gene deletion syndrome: case report. BMC Endocr Disord. 2021;21:214.

24. Wikiera B, Jakubiak A, Łaczmanska I, Noczyńska A, Śmigiel R. Complex glycerol kinase deficiency - long-term follow-up of two patients. Pediatr Endocrinol Diabetes Metab. 2021;27:227-231.

25. Liu L, Wang L, Jiao Z, Kong X. [Diagnosis of a patient with adjacent gene deletion syndrome with DMD complete deletion type of Duchenne muscular dystrophy]. Zhonghua Yi Xue Yi Chuan Xue Za Zhi. 2021;38:869-872.

26. Sevim U, Fatma D, Ihsan E, Gulay C, Nevin B. A neonate with contiguous deletion syndrome in XP21. J Pediatr Endocrinol Metab. 2011;24:1095-1098.

27. Jamroz E, Paprocka J, Popowska E, Pytel J, Ciara E, Adamowicz M. Xp21.2 contiguous gene syndrome due to deletion involving glycerol kinase and Duchenne muscular dystrophy loci. Neurol India. 2010;58:670-671.

28. Sanz-Ruiz I, Bretón-Martínez JR, Del Castillo-Villaescusa C, Cásanovas-Martínez A, Martínez-Castellano F, Millán-Salvador JM, Hernández-Marco R, Codoñer-Franch P. Síndrome de deleción de genes contiguos en Xp21: una forma inusual de presentación [Contiguous gene deletion syndrome in Xp21: an unusual form of presentation]. Rev Neurol. 2009;49:472-474.

29. Pantoja-Martínez J, Martínez-Castellano F, Tarazona-Casany I, Buesa-Ibáñez E, Ardid-Encinar M, Esparza-Sánchez MA, Bonet-Arzo J. Sindrome de deleción de genes contiguos en Xp21: asociación de deficiencia de glicerolcinasa, hipoplasia suprarrenal congénita y distrofia muscular de Duchenne [Contiguous gene deletion syndrome in Xp21: the association between glycerol kinase deficiency, congenital suprarenal hypoplasia and Duchenne's muscular dystrophy]. Rev Neurol. 2007;44:606-609.

30. Ma HW, Jiang J, Wang YP, Wang ZC, Chen LY, Masafumi M. Gene deletion analysis of a Chinese boy with Xp21 contiguous gene deletion syndrome. Chinese Medical Journal, 2004;117;789-791.

CASE REPORT

JCRPE Journal of Clinical Research in Pediatric Endocrinology

DOI: 10.4274/jcrpe.galenos.2025.2024-10-16
J Clin Res Pediatr Endocrinol 2026;18(Suppl 1):92-96

Four Consecutive False Negative Newborn Screens in a Patient with Classical Congenital Adrenal Hyperplasia: A Case Report

Patrick Rizzuto, Mariam Gangat, Ahmed Khattab, Ian Marshall

Rutgers Robert Wood Johnson Medical School, Department of Pediatric Endocrinology, New Jersey, United States

Cite this article as: Rizzuto P, Gangat M, Khattab A, Marshall I. Four consecutive false negative newborn screens in a patient with classical congenital adrenal hyperplasia: a case report. J Clin Res Pediatr Endocrinol. 2026;18(Suppl 1):92-96

What is already known on this topic?

Classical congenital adrenal hyperplasia (CAH) presents early in life and requires lifelong treatment. It is marked by life-threatening "adrenal crises" due to critical steroid hormone deficiency. Newborn screening (NBS) offers protection against such crises by prompting diagnosis and treatment of CAH soon after birth, when patients are still generally asymptomatic. It is imperative that NBS has high sensitivity to minimize false negatives.

What this study adds?

NBS for CAH, including classical CAH, is subject to false negative results, even using high-sensitivity assays. Possible sources of false negative results on NBS for CAH include antenatal steroids, decreased 11HSD2 activity in pregnancies with intrauterine growth restriction, and sodium supplementation prior to sample collection. Persistent hyponatremia without an alternate explanation may indicate classical CAH in spite of normal NBS results. It should be remembered that NBS is screening and not diagnostic; appropriate diagnostic tests should be performed if clinical suspicion remains despite unremarkable NBS results.

ABSTRACT

21-hydroxylase deficiency is the most common cause of congenital adrenal hyperplasia (CAH). Salt-wasting CAH can present with life-threatening salt-wasting crises, underscoring the importance of universal newborn screening. We present a patient diagnosed with classical CAH despite four negative newborn screening (NBS). A male infant was born at 35 weeks gestation with birthweight 1470 grams following signs of placental insufficiency. While hospitalized in the neonatal intensive care unit (NICU), four NBS samples from days of life 2 to 38 were all within normal range, including on repeat analysis using fully integrated fluoroimmunoassay. After initially normal biochemical testing, hyponatremia and hyperkalemia developed by day of life (DOL) 26, responsive to sodium chloride supplementation. Following recurrent hyponatremia after a trial off supplementation after DOL 50, 17-hydroxyprogesterone measured by liquid chromatography-tandem mass spectrometry were reported by

Corresponding Author: Ian Marshall, MD, Rutgers Robert Wood Johnson Medical School, Department of Pediatric Endocrinology, New Jersey, United States
E-mail: marshaia@rwjms.rutgers.edu **ORCID:** orcid.org/0000-0001-7778-4331
Conflict of interest: None declared
Received: 23.10.2024 **Accepted:** 03.04.2025 **Epub:** 09.03.2026 **Publication Date:** 02.06.2026

©Copyright 2026 by Turkish Society for Pediatric Endocrinology and Diabetes / The Journal of Clinical Research in Pediatric Endocrinology published by Galenos Publishing House.
Licensed under a Creative Commons Attribution-NonCommercial-NoDerivatives 4.0 (CC BY-NC-ND) International License.

two different labs as 10,900 ng/dL and 11,200 ng/dL (normal range at DOL 50<2 ng/dL). Subsequent testing identified deletion of one *CYP21A2* allele and a mutation, *I172N*, in the second. This report illustrates the importance of maintaining a high index of suspicion for classical forms of CAH in infants with persistent electrolyte disturbances despite negative NBS results.

Keywords: Congenital adrenal hyperplasia, newborn screening, hyponatremia, 17-hydroxyprogesterone

Introduction

Steroid 21-hydroxylase deficiency (21-OHD) is the most common cause of congenital adrenal hyperplasia (CAH), resulting from deficiency of the 21-hydroxylase enzyme encoded by *CYP21A2* that plays an essential role in cortisol and aldosterone synthesis in the adrenal cortex. The most common classical forms consist of simple virilizing (SV) type which accounts for 25% of classical 21-OHD; and the salt-wasting type (SW), which accounts for more than 75% of affected individuals (1).

In all 50 of the United States, including New Jersey, newborn screening obtained in the neonatal period includes 17-hydroxyprogesterone (17-OHP) to identify and begin treatment of CAH before the life-threatening salt-wasting crises that occur in SW CAH without hormone replacement are likely to develop. In New Jersey, state law requires this newborn screen to be obtained in all babies 24 to 48 hours after birth. 17-OHP is measured using the Revvity DELFIA assay. The thresholds for elevated values vary depending on birthweight, increasing with lower weight. These cutoffs are included in Table 1.

Given the high sensitivity of newborn screening, providers may conclude in error there is no possibility of CAH in babies with a negative screening result. However, false negative newborn screens for CAH have been reported. One identified risk factor for a false negative CAH screen is antenatal steroid administration, such as to induce fetal lung maturity. Even in the absence of antenatal exogenous steroids, the possibility remains of a false negative CAH screen. Given the life-threatening nature of a salt-wasting crisis, failure to investigate the possibility of CAH and to institute appropriate treatment carries high morbidity and mortality.

In this case report, we present a patient diagnosed with the classical form of 21-OHD CAH despite four negative newborn screening (NBS) results. We identify pertinent features of his presentation that may have led to the false negative screens, as well as aspects that ultimately assisted in making the diagnosis. The parents of the patient consented to the publication of this case report.

Case Report

A Caucasian male was born at an outside institution at 35 weeks gestation by Cesarean section for non-reassuring fetal heart tracing and intrauterine growth restriction (IUGR) to a 35-year-old mother. At 30 weeks, the mother was hospitalized due to absent end diastolic flow on umbilical Doppler, consistent with placental insufficiency. To promote fetal lung maturity, standard doses of glucocorticoids (2 doses of betamethasone at 12 mg/dose 24 hours apart) were administered at 30 and at 33 weeks gestation.

Both birth weight (BW) of 1470 g and length of 40.5 cm were consistent with small for gestational age (SGA). The baby was not in distress at birth. Examination revealed bilaterally descended testes palpable in a normally developed scrotum, and a normal sized phallus. He was admitted to the neonatal intensive care unit (NICU) for monitoring due to prematurity and to gradually introduce enteral feeds.

Initial routine biochemical testing showed normal sodium and potassium levels for postnatal age. After day of life (DOL) 26, hyponatremia and hyperkalemia developed with sodium of 127 mEq/L (various reference ranges have been proposed) (2) and potassium of 6.2 mEq/L (Harriet Lane newborn range: 3.7-5.9 mEq/L). Hyponatremia persisted with a nadir of 124 mEq/L; peak potassium was 8.0 mEq/L. These lab values are displayed in Table 2. Additional testing did not reveal hypoglycemia or metabolic acidosis. There was no hypotension, tachycardia, or other clinical evidence of dehydration.

Table 1. 17-hydroxyprogesterone (17-OHP) thresholds used for newborn screening in the state of New Jersey, USA. As birthweight decreases, the thresholds for elevated values increase. That table was provided by the Newborn Screening Laboratory of the New Jersey Department of Health

Birth weight (grams)	Within acceptable limits (ng/mL)	Borderline range (ng/mL)	Presumptive/critical range (ng/mL)
<1500	<100	100-<145	≥145
1500-<2500	<60	60-<80	≥80
2500-<300	<40	40-<48	≥48
≥3000	<35	35-<55	≥55

The NICU team attributed both electrolyte disturbances to prematurity and started sodium chloride supplementation at 4 mEq/kg/day on DOL 30. The hyponatremia resolved, leading to discontinuation of sodium supplementation. After the supplement was stopped, hyponatremia then recurred within one day, and again resolved with reintroduction of sodium supplementation. Due to incomplete records, it is unclear if additional specific treatment was provided for the hyperkalemia, which normalized during the first course of sodium supplementation and did not recur at any point. On DOL 39, with appropriate sodium and potassium levels for postnatal age and on full enteral feeds, he was discharged home on sodium supplementation of 3 mEq/kg/day. While in the NICU, neither Pediatric Endocrinology nor Nephrology were consulted.

Eleven days after discharge, he was admitted to our institution on DOL 50 for additional evaluation due to the pediatrician's concern about the prior electrolyte abnormalities. His examination was unchanged. His weight of 2.78 kg represented an average daily weight gain since birth of approximately 30 g.

During admission, at our request, all four NBS samples for CAH drawn on DOL 2, 6, 13 and 38 were re-analyzed in duplicate by the New Jersey Department of Health using fully integrated fluoroimmunoassay (3) and again were within the normal range.

During this second admission, electrolytes were normal on sodium supplementation. Hyponatremia again developed within one day after supplementation was discontinued; hyperkalemia did not develop. Additional diagnostic testing off sodium at that time included plasma renin activity (PRA) of 120 ng/mL/hr (normal range for 0-2 yrs: 1.4-7.8 ng/mL/hr; Mayo Medical Laboratories, Rochester, MN, USA), and an aldosterone level of 24 ng/dL (normal for 31 days-11 months of age: 6.5-86 ng/dL; Mayo Medical Laboratories). Sodium supplementation was restarted followed by normalization of sodium within one day.

Table 2. Laboratory values obtained during first hospitalization, with respective normal ranges for given age

Analytes	Day of life (DOL) 26	Between DOL 26 and DOL 30 (prior to sodium supplementation)
Sodium (mEq/L)	127 (various)	124 (various)
Potassium (mEq/L)	6.2 (3.7-5.9)	8.0 (3.7-5.9)

Table 3. Laboratory values obtained during second hospitalization, with respective normal range for given age

Analytes	Day of life (DOL) 51	DOL 56 (after beginning hydrocortisone)
Plasma renin activity (ng/mL/hr)	120 (1.4-7.8)	
Aldosterone (ng/dL)	24 (6.5-86)	
Mayo medical laboratories 17-hydroxyprogesterone (ng/dL)	10,900 (<2)	2,850 (<2)
Esoterix laboratory services 17-hydroxyprogesterone (ng/dL)	11,200 (<2)	2,250 (<2)

21-OHD CAH was considered despite the negative screening. Serum 17-OHP measurements on DOL 51 off sodium supplementation for one day performed at both Mayo Medical Laboratories (Rochester, MN) and Esoterix Laboratory Services (Calabasas Hills, CA, USA) by liquid chromatography-tandem mass spectrometry were reported at 10,900 ng/dL and 11,200 ng/dL (normal range<2 ng/dL at 50 DOL), respectively. Repeat levels five days after sodium supplementation was restarted had decreased to 2,850 and 2,250 ng/dL, respectively. The above lab values from the second hospitalization are displayed in Table 3.

A diagnosis of SW CAH was then made based on the history of hyponatremia and 17-OHP levels>10,000 ng/dL on two assays. Hydrocortisone (15 mg/m^2/day) and fludrocortisone (0.1 mg/day) were then started with sodium supplementation at 3 mEq/kg/day. Subsequent genetic testing for 21-OHD CAH at Mayo Medical Laboratories (Rochester, MN) with full Sanger gene sequencing and multiple ligation-dependent probe amplification identified deletion of one *CYP21A2* allele and the *I172N* mutation in the second allele.

Discussion

NBS for CAH using 17-OHP measurements was first introduced to the USA in the late 1970's, and since then has been adopted by all 50 states, as well as 52 other countries. In healthy, unaffected newborns, physiological 17-OHP levels are elevated at birth and then decline over the next 2-3 weeks (4). In contrast, levels in classical CAH typically increase postnatally (5). The main purpose of screening is to identify newborns with classical CAH, particularly the salt wasting form in males, to avoid potential life-threatening salt wasting crises. It is also utilized to prevent incorrect sex assignment in virilized females with classical CAH.

Certain studies have shown that the sensitivity of the NBS for CAH is lower than expected. Sarafoglou et al. (6) reviewed 838,241 NBS results in Minnesota reported over a 12-year period, and reported that of 67 patients with classical CAH, 15 were missed on initial NBS (ten with SV CAH and five with SW CAH; six males, nine females). This was a false negative rate (FNR) of 22%. The diagnosis in five of the female patients was based on presentation of atypical genitalia at birth. Although three others also presented with atypical genitalia at birth, their diagnoses were delayed until as early as three months and up to six years of age. The remaining female patient had vaginoplasty six years prior to diagnosis. Despite these numbers, the authors suggested that the FNR was likely even higher due to the likelihood of undiagnosed patients with CAH, patients

moving out of state, and/or infants that may have died with unidentified CAH (6).

A review by Varness et al. (7) of all NBS results in Wisconsin over a 12-year period identified eight patients diagnosed with classical CAH whose NBS results were negative. Overall sensitivity was 86%; although constrained by small numbers, sensitivity was further determined by sex to be 67% in females and 97% in males. The higher FNR for females could be partly explained by significantly lower 17-OHP levels reported in females on NBS (7). However, as most female patients with classical CAH are expected to be virilized, detection prior to reporting of the NBS result is expected to occur, making the reduced sensitivity less problematic for female patients. However, even significantly virilized females have unfortunately been missed as atypical genitalia may not be noted on physical examination (6).

Schreiner et al. (8) reported that in a questionnaire-based study sent to 24 medical center members of the German Working Group of Pediatric Endocrinology, five out of 214 children with classical CAH were not detected by NBS, including two with the salt-wasting form.

Based on the reported FNR using single screen protocols and the rise in 17-OHP after birth in classical CAH, 13 states have instituted a two-screen protocol to improve sensitivity (3). Chan et al. (9) reported that 11 out of 39 (28%) cases of classical CAH in Colorado were detected by the second NBS test at age 8-14 days of life. A five-year retrospective study by Held et al. (4) demonstrated that 6.5% of all SW CAH cases missed on the first screen were identified by the second screen. Similarly in Texas, 14% of classical CAH cases were detected on a second screen (10).

This patient's genotype is typically associated with SV CAH (1) although, as in the presented case, may also result in the SW phenotype (11). Certain studies (6,10) have found that the majority of CAH cases missed by NBS are SV CAH, due to less dramatic elevations in 17-OHP. This is an important distinction, as the motivation for NBS hinges on rapid detection prior to life-threatening crises developing, which are unlikely in the milder defects associated with SV CAH. It is notable, however, that this patient had significant enough disease to develop hyponatremia and hyperkalemia, and may have been spared clinical dehydration primarily due to being in a NICU for other reasons. Furthermore, the final 17-OHP levels that were obtained prior to diagnosis were robustly elevated, and well into the range associated with classical CAH. Therefore, while the FNR is likely lower in the population of patients with SW CAH whose identification is the primary goal of newborn screening, our case does demonstrate a possibility of false negative screening in patients who may potentially suffer clinical complications as a consequence.

A possible explanation for this patient's initial two negative NBS results could be antenatal administration of glucocorticoids to promote lung maturity. Gatelais et al. (12) demonstrated that multiple courses of antenatal glucocorticoids lowered 17-OHP levels in the newborns by about 30% compared to controls. The reason is transplacental transfer of glucocorticoids with suppression of fetal adrenal steroidogenesis. Inhaled and intranasal corticosteroids have also been reported to produce the same effect (13). However, this postnatal suppression is believed to last only about one week (14), so would not likely explain the negative third and fourth NBS results. Even though in this case repeat NBSs did not detect CAH after the suppression is expected to have faded, repeating the NBS for infants born following antenatal glucocorticoid exposure, or alternatively checking a serum 17-OHP level, 1-2 weeks after delivery will lead to detection of some cases missed on the first screen.

Sodium supplementation may explain the 4th negative NBS result, and the decrease in 17-OHP during the patient's readmission. As 21-hydroxylase enzyme plays a role in the production of both cortisol and aldosterone in the adrenal cortex, mutations in the *CYP21A2* gene in the SV type are expected to also affect aldosterone synthesis. In SV CAH, this can lead to a relative state of hypovolemia, which in turn stimulates production of renin, angiotensin II, and possibly vasopressin (15). Angiotensin II can directly stimulate adrenal steroidogenesis independently of adrenocorticotropic hormone (ACTH), while vasopressin can increase pituitary ACTH secretion. As sodium supplementation corrects hypovolemia, angiotensin II and vasopressin production decreases, in turn reducing adrenal steroidogenesis and lowering 17-OHP levels. Therefore, if repeating the NBS or measuring 17-OHP directly, it is important to do so prior to sodium supplementation in babies with hyponatremia, or if supplements have already been started to discontinue them prior to further evaluation, as in this case.

An additional factor could be decreased activity of placental 11-hydroxysteroid dehydrogenase type 2 (11HSD2) reported in pregnancies complicated by IUGR (16). 11HSD2 inactivates cortisol by conversion to cortisone (16), thus protecting the fetus from potentially harmful effects of endogenous maternal glucocorticoids. We hypothesize that decreased 11HSD2 activity increases maternal cortisol levels that cross the placenta and induce suppression of fetal adrenal steroidogenesis, including 17-OHP production. It is possible this contributed to the false negative in our particular case in a manner similar to the antenatal glucocorticoids.

A significant limitation to this case report is the lack of complete records. Since hyperkalemia was noted with the initial hyponatremia, but not subsequent episodes of it, additional information regarding any treatment for the hyperkalemia itself

would have been valuable. Once a diagnosis of CAH has been established, the standard of care is to provide mineralocorticoid replacement with fludrocortisone in addition to hydrocortisone and sodium supplementation (15), as our patient ultimately received after diagnosis. It is also unclear if there were any investigations, such as renin and aldosterone measurements, during the first admission exploring an adrenal pathology for the electrolyte abnormalities. Additional insights into the treating team's evaluation of the electrolyte disturbances, and why they were ultimately attributed to prematurity, would have allowed a more comprehensive analysis of this case.

Conclusion

Despite efforts to improve the sensitivity of NBS for CAH, challenges persist, with potentially devastating consequences. This report emphasizes the importance of maintaining a high index of suspicion for classical forms of CAH in all newborns presenting with similar electrolyte disturbances despite negative NBS results.

Ethics

Informed Consent: The parents of the patient consented to the publication of this case report.

Footnotes

Authorship Contributions

Concept: Patrick Rizzuto, Mariam Gangat, Ahmed Khattab, Ian Marshall, Design: Patrick Rizzuto, Mariam Gangat, Ahmed Khattab, Ian Marshall, Analysis or Interpretation: Patrick Rizzuto, Mariam Gangat, Ahmed Khattab, Ian Marshall, Literature Search: Patrick Rizzuto, Mariam Gangat, Ahmed Khattab, Ian Marshall, Writing: Patrick Rizzuto, Mariam Gangat, Ahmed Khattab, Ian Marshall.

Financial Disclosure: The authors declared that this study received no financial support.

References

1. Nimkarn S, Lin-Su K, New MI. Steroid 21 hydroxylase deficiency congenital adrenal hyperplasia. Endocrinol Metab Clin North Am. 2009;38:699-718.
2. Bischoff AR, Tomlinson C, Belik J. Sodium intake requirements for preterm neonates: review and recommendations. J Pediatr Gastroenterol Nutr. 2016;63:e123-e129.
3. Edelman S, Desai H, Pigg T, Yusuf C, Ojodu J. Landscape of congenital adrenal hyperplasia newborn screening in the United States. Int J Neonatal Screen. 2020;6:64.
4. Held PK, Shapira SK, Hinton CF, Jones E, Hannon WH, Ojodu J. Congenital adrenal hyperplasia cases identified by newborn screening in one- and two-screen states. Mol Genet Metab. 2015;116:133-138. Epub 2015 Aug 12
5. White PC. Optimizing newborn screening for congenital adrenal hyperplasia. J Pediatr. 2013;163:10-12. Epub 2013 Mar 20
6. Sarafoglou K, Banks K, Kyllo J, Pittock S, Thomas W. Cases of congenital adrenal hyperplasia missed by newborn screening in Minnesota. JAMA. 2012;307:2371-2374.
7. Varness TS, Allen DB, Hoffman GL. Newborn screening for congenital adrenal hyperplasia has reduced sensitivity in girls. J Pediatr. 2005;147:493-498.
8. Schreiner F, Brack C, Salzgeber K, Vorhoff W, Woelfle J, Gohlke B. False negative 17-hydroxyprogesterone screening in children with classical congenital adrenal hyperplasia. Eur J Pediatr. 2008;167:479-481. Epub 2007 May 22
9. Chan CL, McFann K, Taylor L, Wright D, Zeitler PS, Barker JM. Congenital adrenal hyperplasia and the second newborn screen. J Pediatr. 2013;163:109-113.e1. Epub 2013 Feb 12
10. Therrell BL Jr, Berenbaum SA, Manter-Kapanke V, Simmank J, Korman K, Prentice L, Gonzalez J, Gunn S. Results of screening 1.9 million Texas newborns for 21-hydroxylase-deficient congenital adrenal hyperplasia. Pediatrics. 1998;101:583-590.
11. New MI, Abraham M, Gonzalez B, Dumic M, Razzaghy-Azar M, Chitayat D, Sun L, Zaidi M, Wilson RC, Yuen T. Genotype-phenotype correlation in 1,507 families with congenital adrenal hyperplasia owing to 21-hydroxylase deficiency. Proc Natl Acad Sci U S A. 2013;110:2611-2616. Epub 2013 Jan 28
12. Gatelais F, Berthelot J, Beringue F, Descamps P, Bonneau D, Limal JM, Coutant R. Effect of single and multiple courses of prenatal corticosteroids on 17-hydroxyprogesterone levels: implication for neonatal screening of congenital adrenal hyperplasia. Pediatr Res. 2004;56:701-705. Epub 2004 Sep 15
13. Houang M, Nguyen-Khoa T, Eguether T, Ribault B, Brabant S, Polak M, Netchine I, Lamazière A. Analysis of a pitfall in congenital adrenal hyperplasia newborn screening: evidence of maternal use of corticoids detected on dried blood spot. Endocr Connect. 2022;11:e220101.
14. Ballard PL, Gluckman PD, Liggins GC, Kaplan SL, Grumbach MM. Steroid and growth hormone levels in premature infants after prenatal betamethasone therapy to prevent respiratory distress syndrome. Pediatr Res. 1980;14:122-127.
15. White PC, Speiser PW. Congenital adrenal hyperplasia due to 21-hydroxylase deficiency. Endocr Rev. 2000;21:245-291. Erratum in: Endocr Rev 2000;21:550.
16. Kajantie E, Dunkel L, Turpeinen U, Stenman UH, Wood PJ, Nuutila M, Andersson S. Placental 11 beta-hydroxysteroid dehydrogenase-2 and fetal cortisol/cortisone shuttle in small preterm infants. J Clin Endocrinol Metab. 2003;88:493-500.